QRS complex

Dr Siow Yoon Kee

MD, MRCP (UK)

Consultant Cardiologist & Electrohpysiologist

Hospital Sultan Idris Shah, Serdang



Outlines:

1. Vector
2. QRS & ventricular depolarization
3. BBB & Abberancy
4. ECG in echocardiography
5. PVC
6. QRS in patient with syncope



Vector

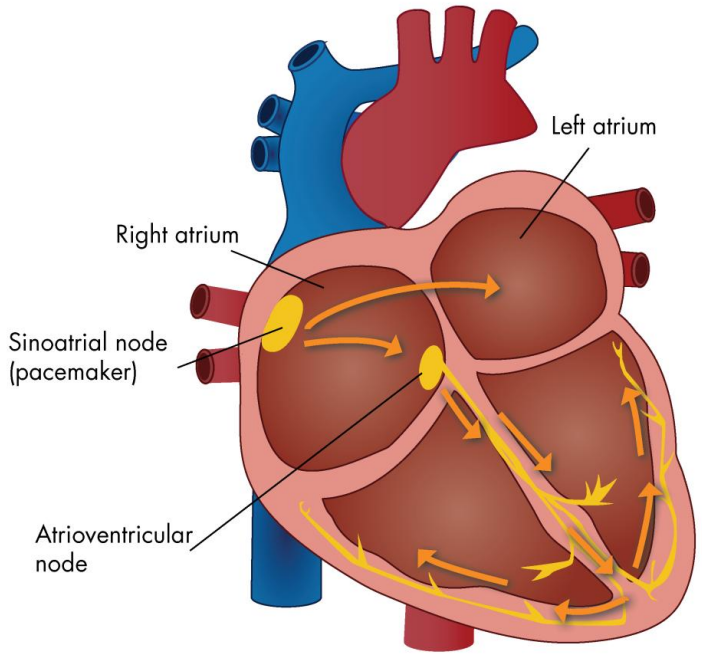

avR

avL

V1

V2

V3

V4

V5

V6

I

II

III

avF

cablesandsensors.com

Towards Positive

Away Negative



+





−





Positive deflection

Isoline

Negative deflection

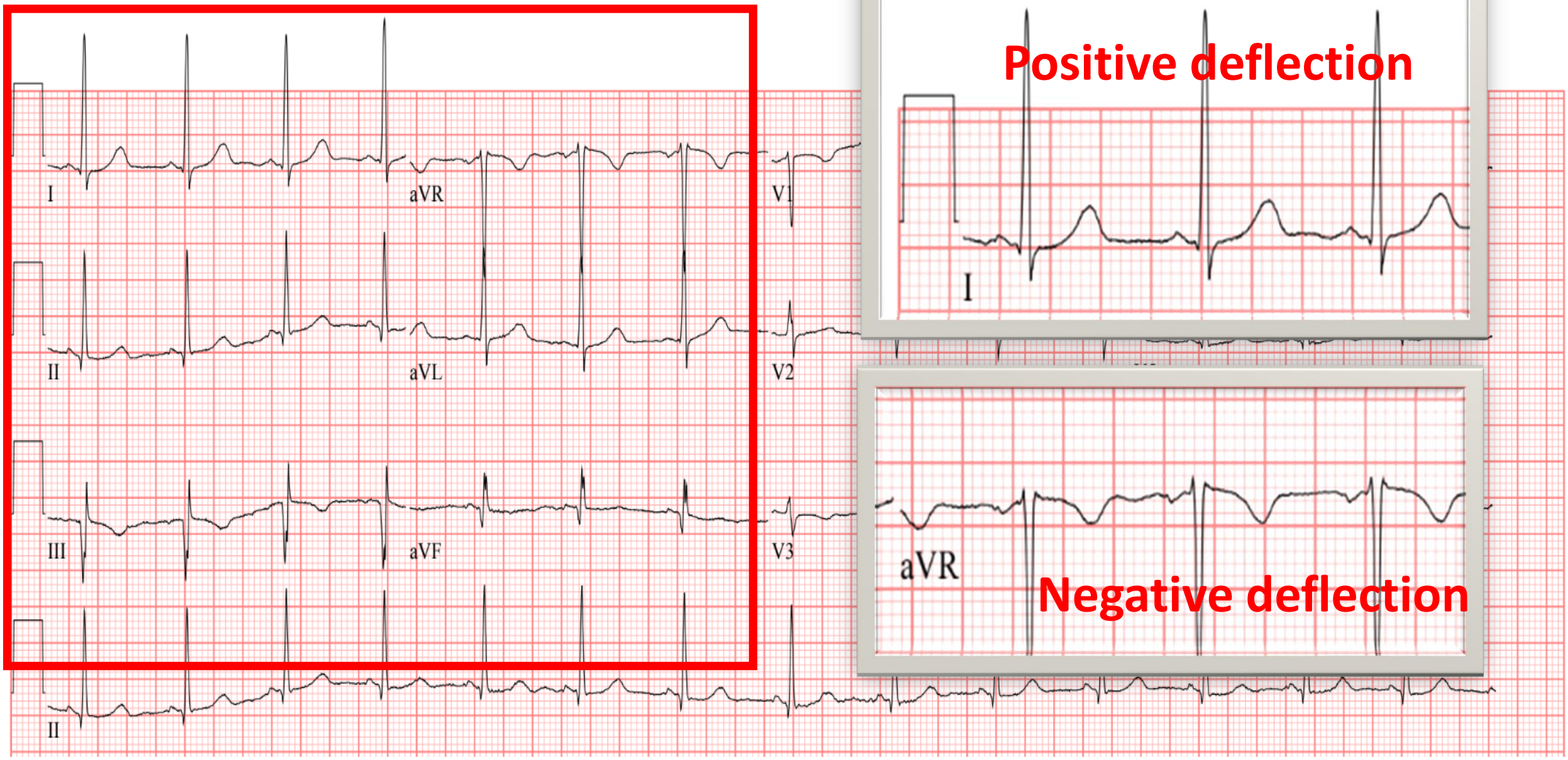
I
aVR
V1
II
aVL
V2
III
aVF
V3
II
Positive deflection
I
aVR
Negative deflection

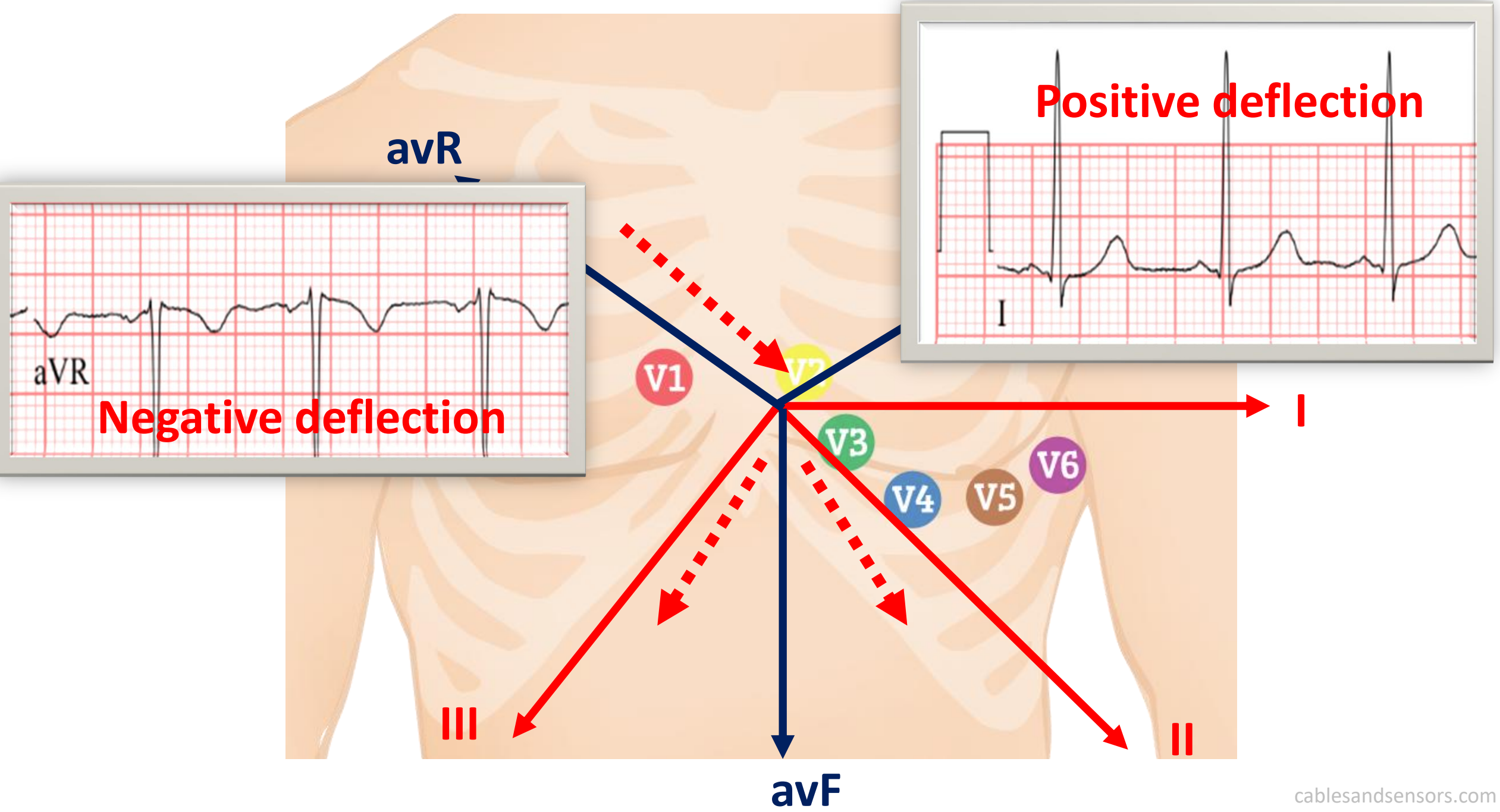

cablesandsensors.com

WRONG LEADS



https://doi.org/10.1016/j.afjem.2014.05.006

VENTRICULAR TACHYCARDIA

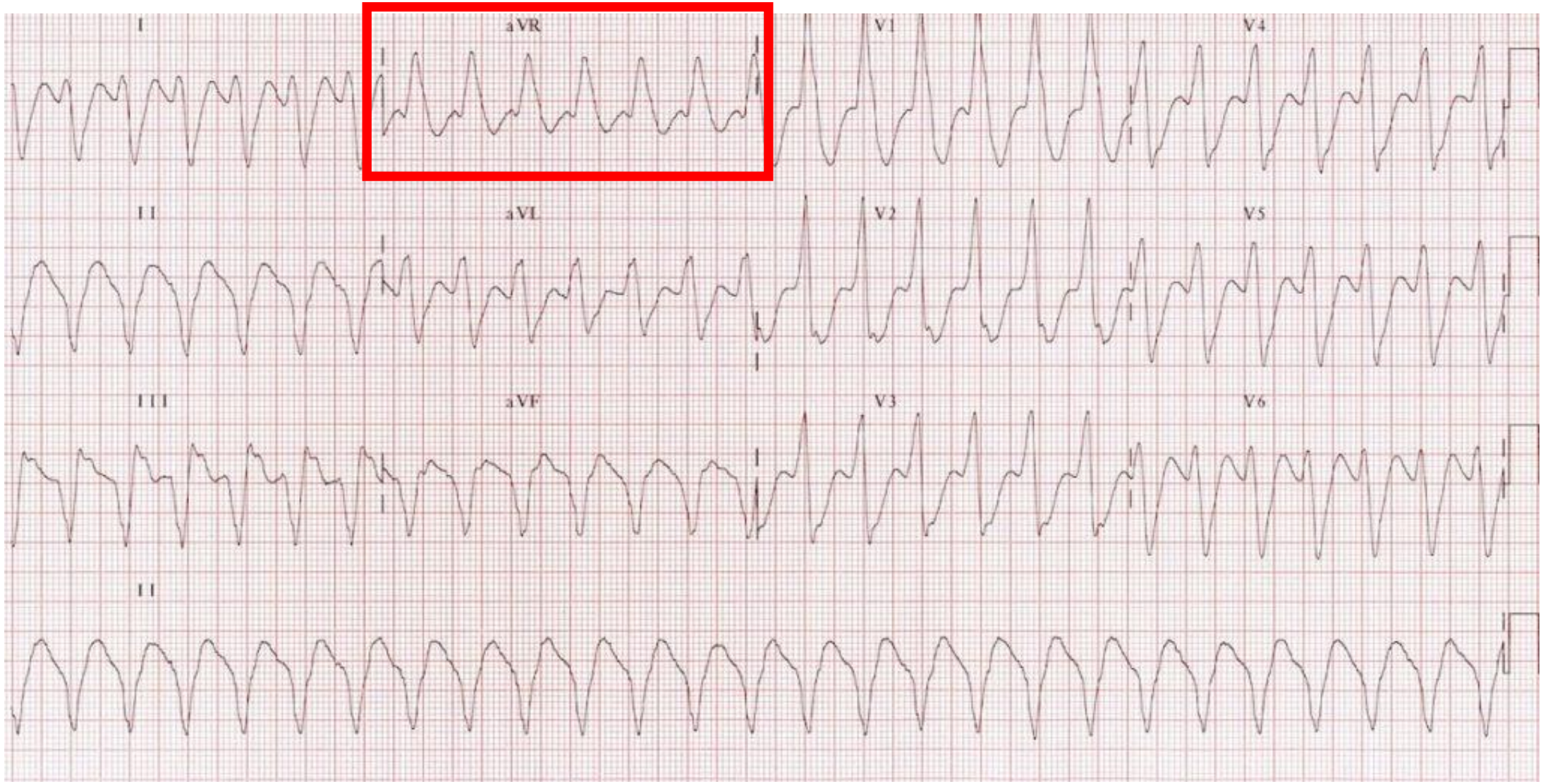

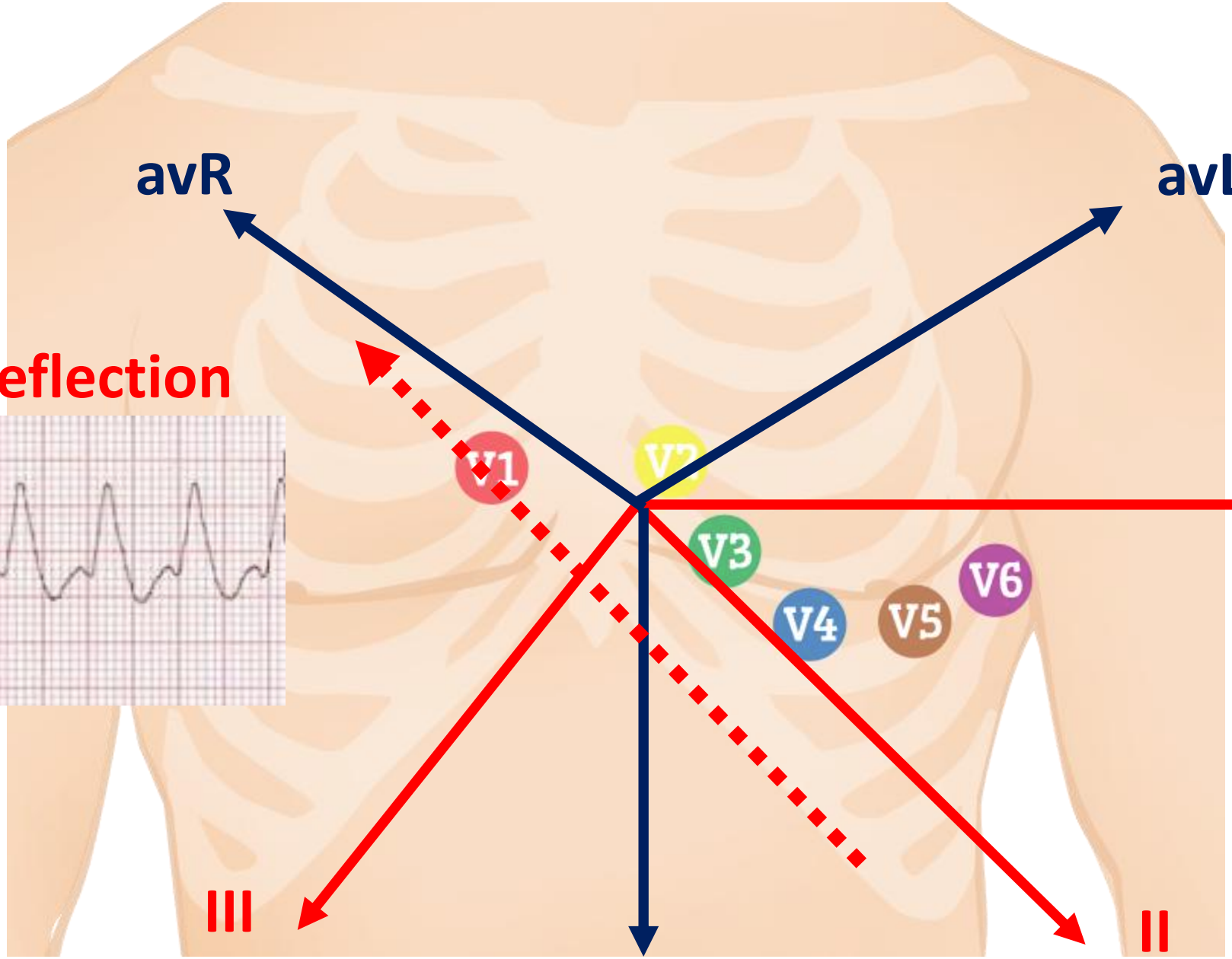

Positive deflection

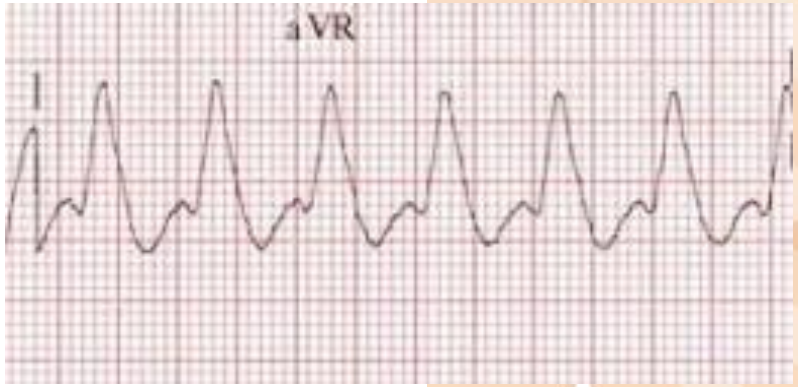

cablesandsensors.com



QRS =
Ventricular Depolarization

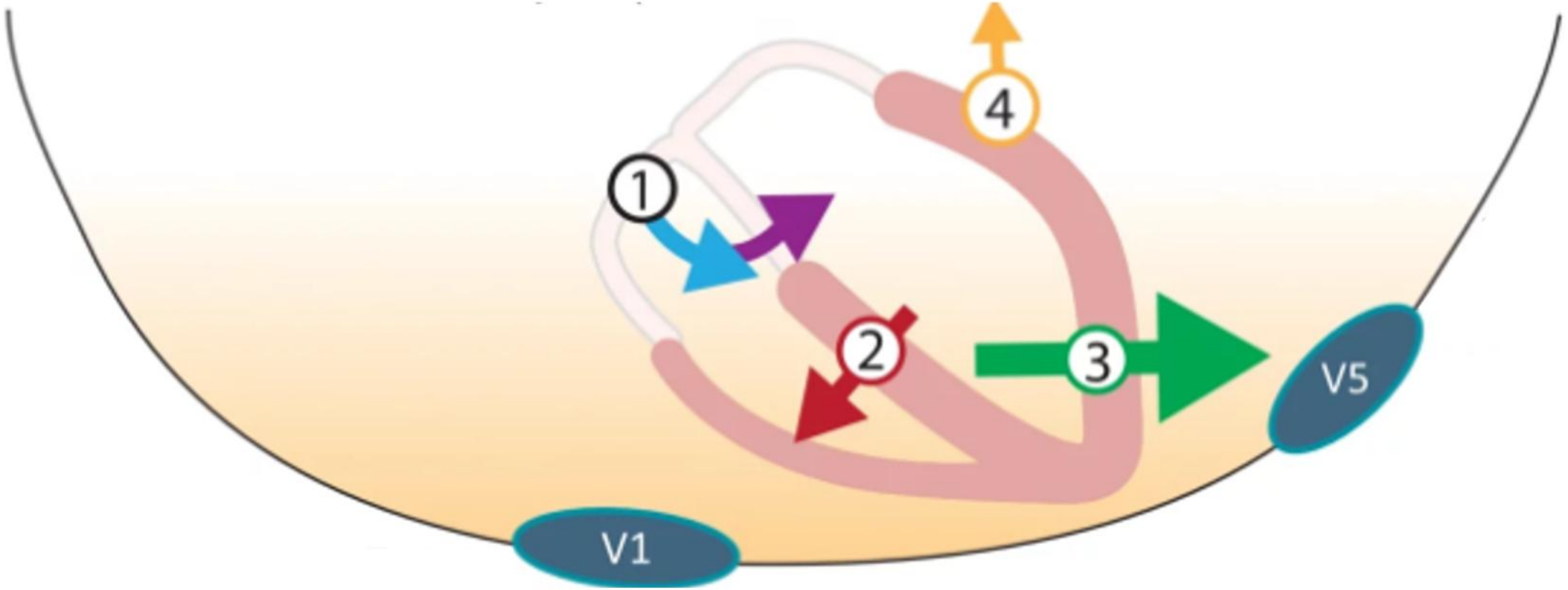
4
1
2
3
V5
V1

QRS complex

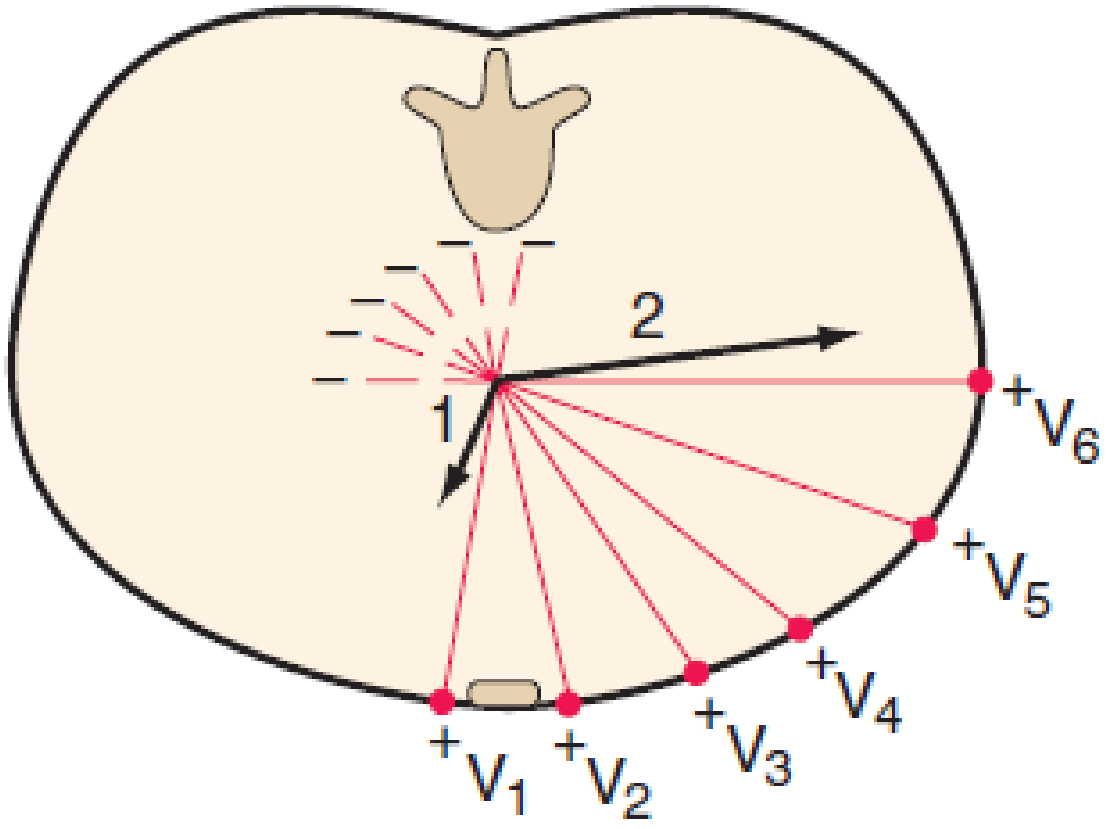

Harrison’s Internal Medicine 2022,21th Edition

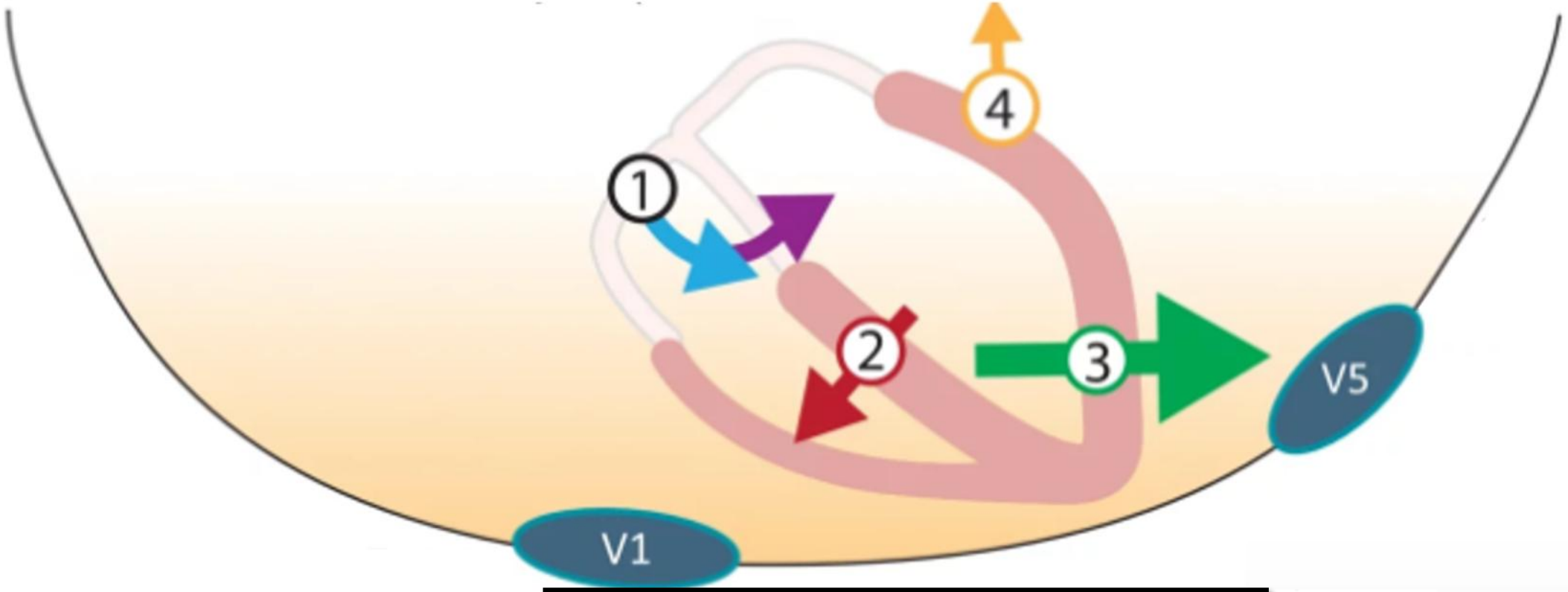

V1





Note the gradual transition from the QRS pattern in V1 to V6.

V5



POOR R WAVE PROGRESSION

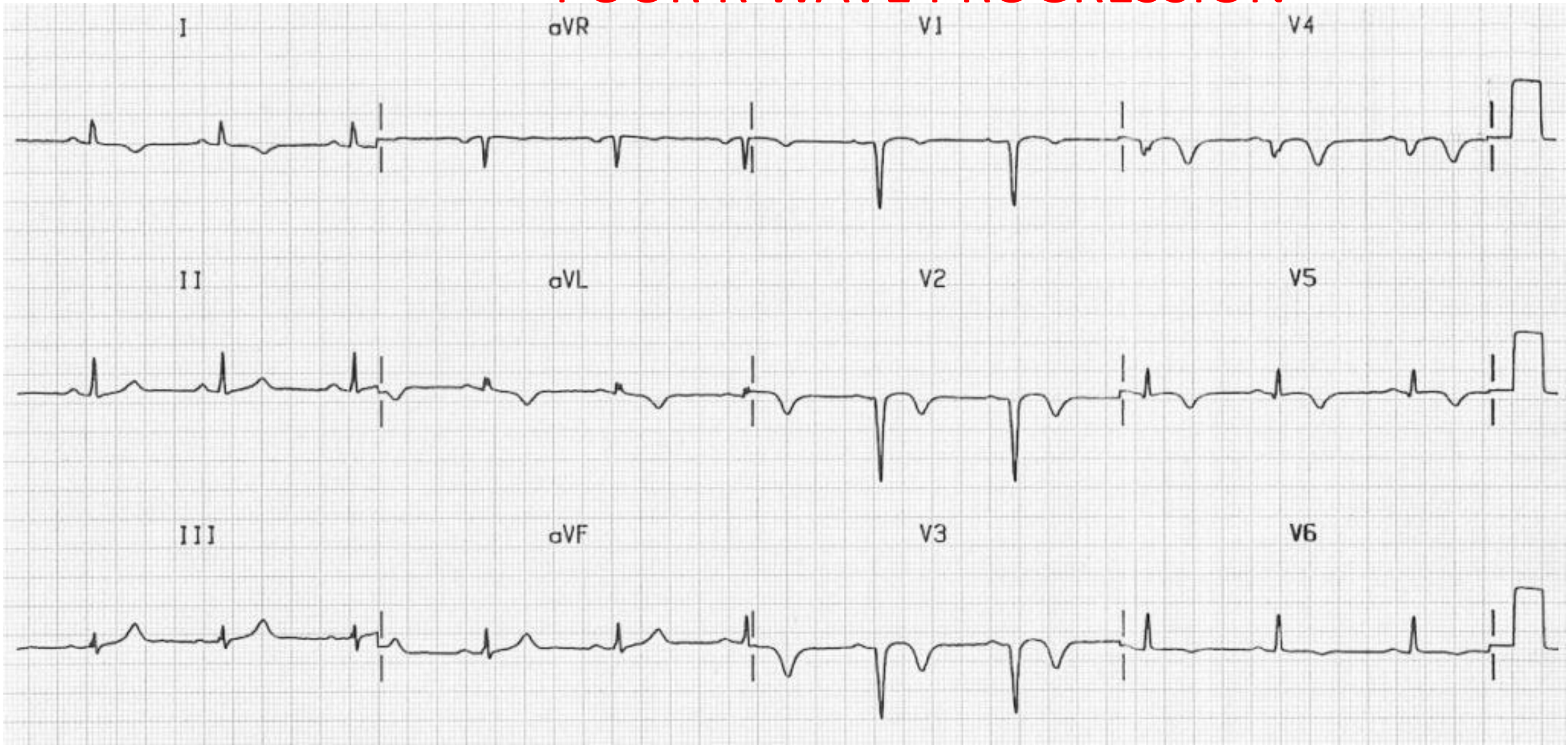

litfl.com

LV & RV hypertrophy

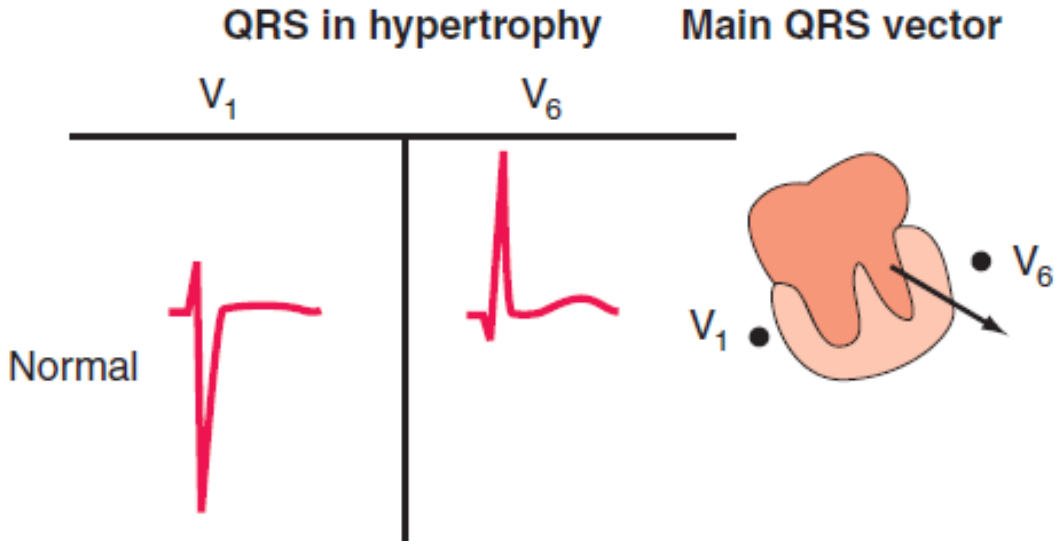

Harrison's Internal Medicine 2022,21th Edition



Bundle branch block

ecgwaves.com

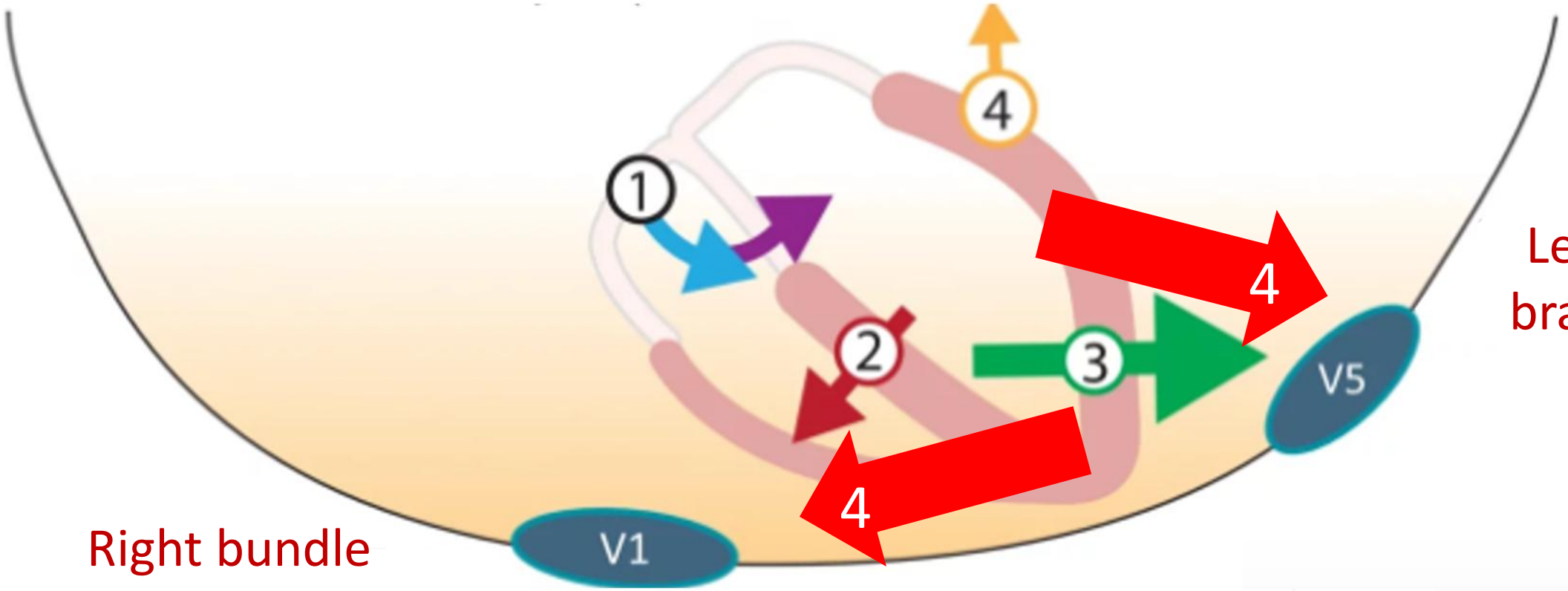

Left bundle branch block

Right bundle branch block

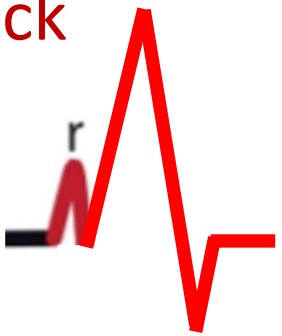

V1

V5



Aberrancy?



What is the mechanism for this run of wide-complex tachycardia?

A. Intermittent preexcitation

B. Ventricular tachycardia

C. Aberration from phase 3 block

D. Aberration from phase 4 block

TEMPORARILY

SVT with Aberrancy

vs

Bundle Branch Block

PERMANENT

Aberrancy?

1. **Tachycardia**-related block
   - Phase 3 block
   - Physiologic encroachment on the refractory period

2. **Bradycardia**-related block
   - Phase 4 block from diseased resting membrane potential depolarization during bradycardia

Electrophysiology and pacing through case studies, Kenneth a. Ellenbogen

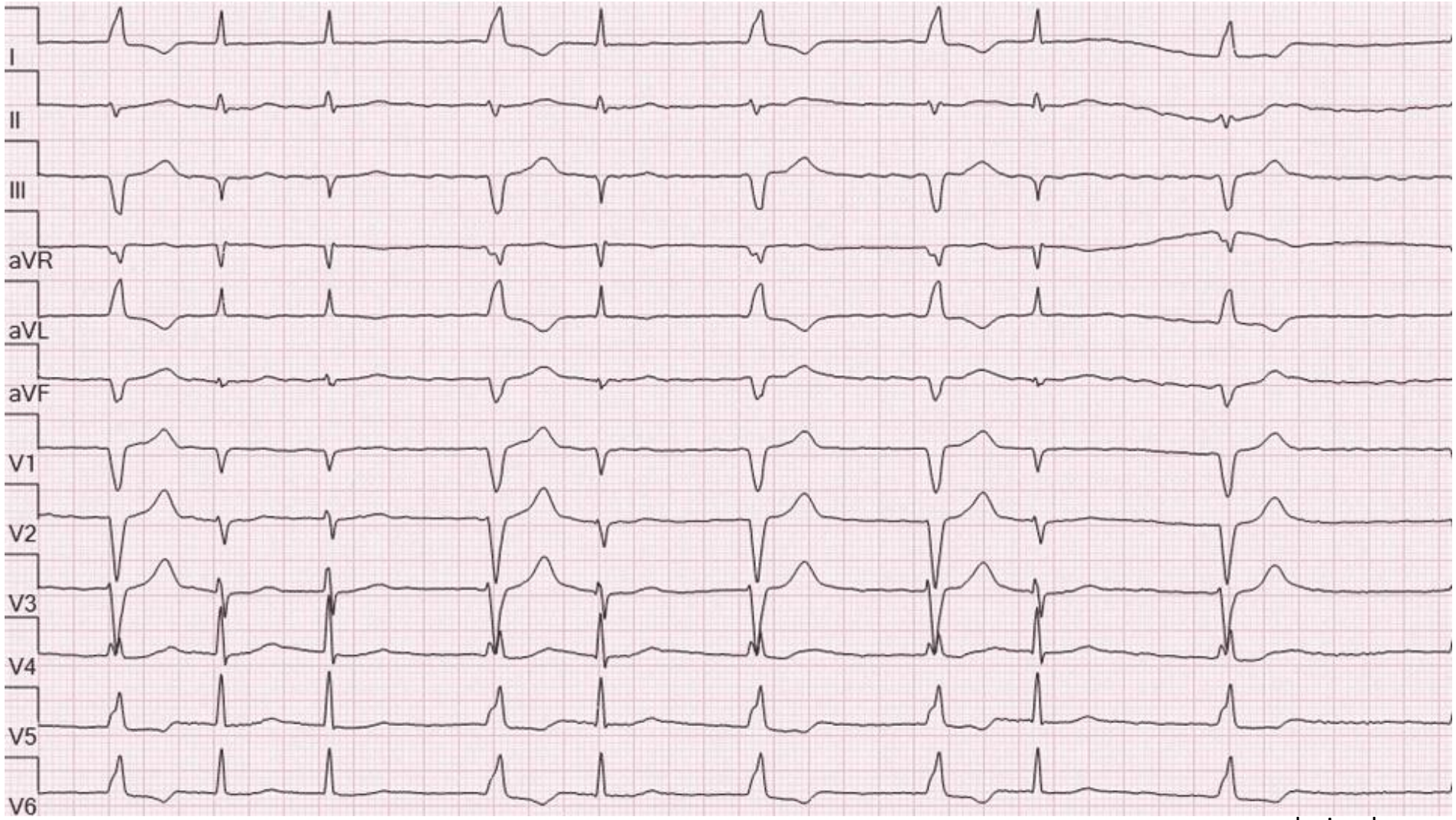

ecgmadesimple.ca

AF with Intermittent LBBB

Bradycardia-Related: Aberration from Phase 4 Block

Aberrancy?

1. **Tachycardia**-related block
   - Phase 3 block
   - Physiologic encroachment on the refractory period

2. **Bradycardia**-related block
   - Phase 4 block from diseased resting membrane potential depolarization during bradycardia

Electrophysiology and pacing through case studies, Kenneth a. Ellenbogen

Why cares? Rule out VT.....

SVT with Aberrancy
vs
Ventricular Tachycardia

Brug

1. No RS in V1-
2. RS interval >
3. AV dissociati
4. VT morpholog

None of the a

Morphological Criteria

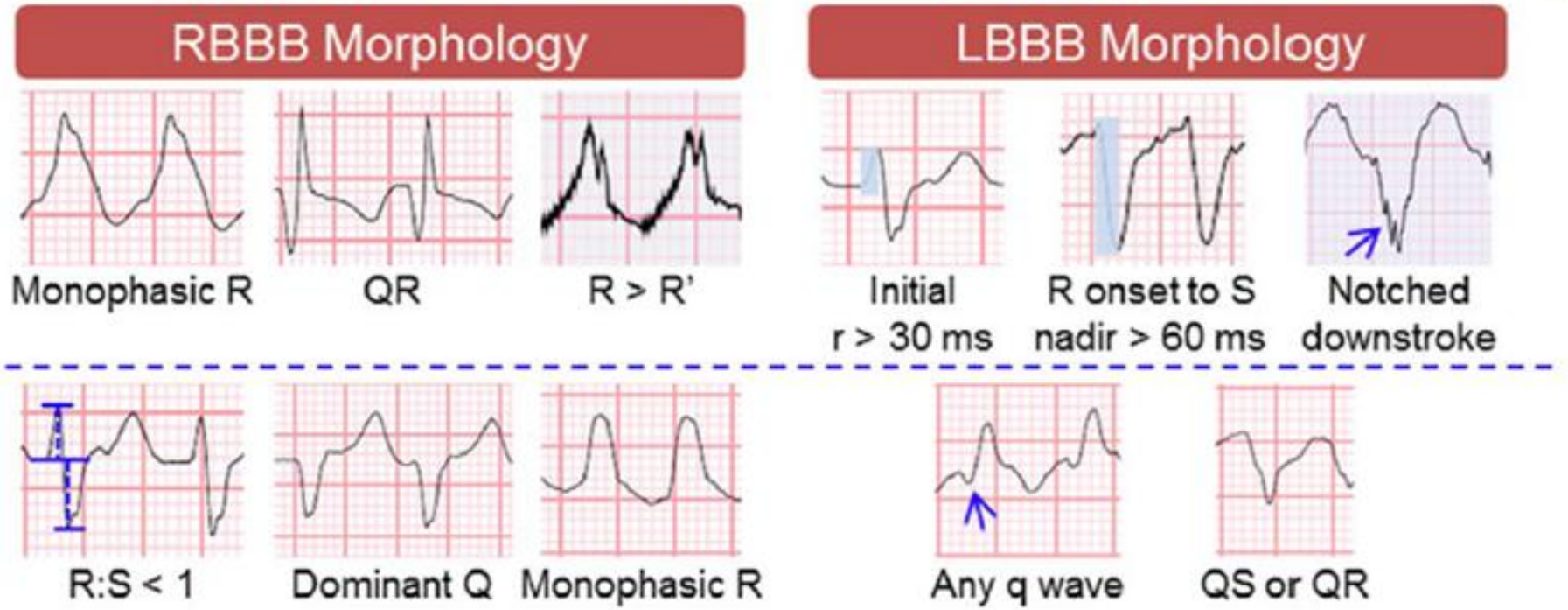

1. Check the axis of tachycardia & SR

- Compare sinus rhythm & WCT ECG
- BBB pattern identical to SR - SVT with bundle branch block
- Different QRS pattern during tachycardia - VT

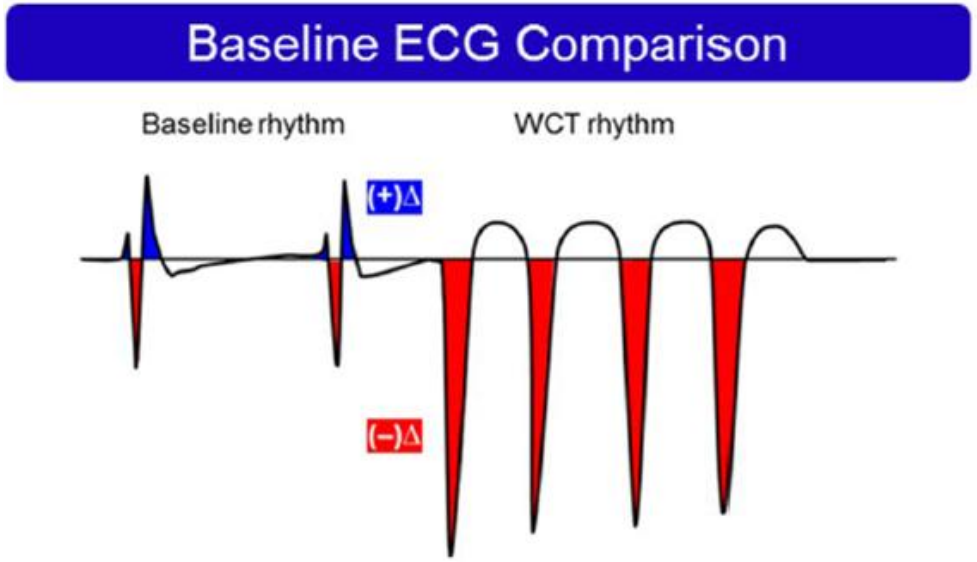

Kashou AH, Noseworthy PA, DeSimone CV, Deshmukh AJ, Asirvatham SJ, May AM. Wide Complex Tachycardia Differentiation: A Reappraisal of the State-of-the-Art. J Am Heart Assoc. 2020

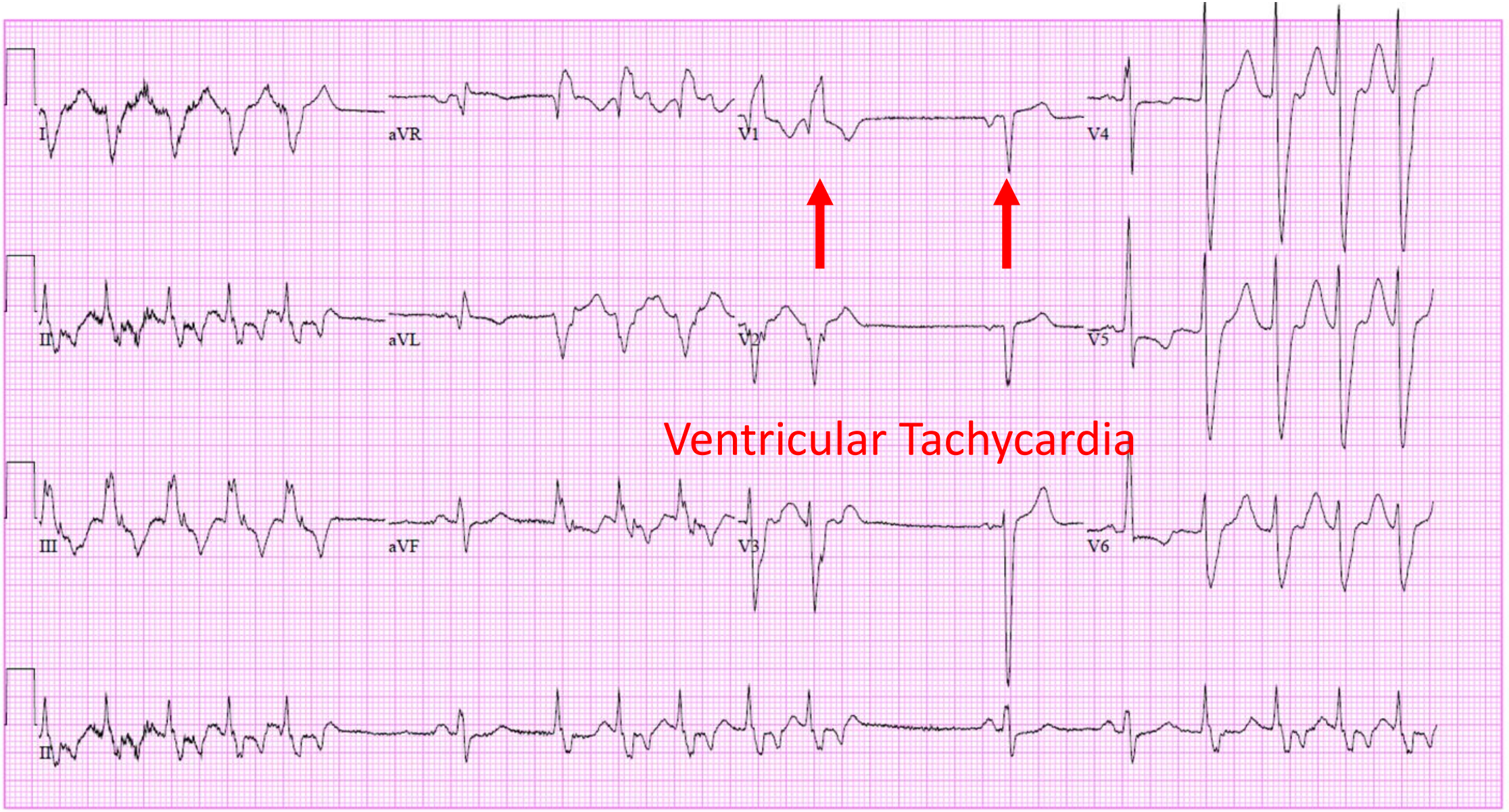
I
aVR
V1
V4
II
aVL
V2
V5
III
aVF
V3
V6
II
Ventricular Tachycardia

2. QRS duration

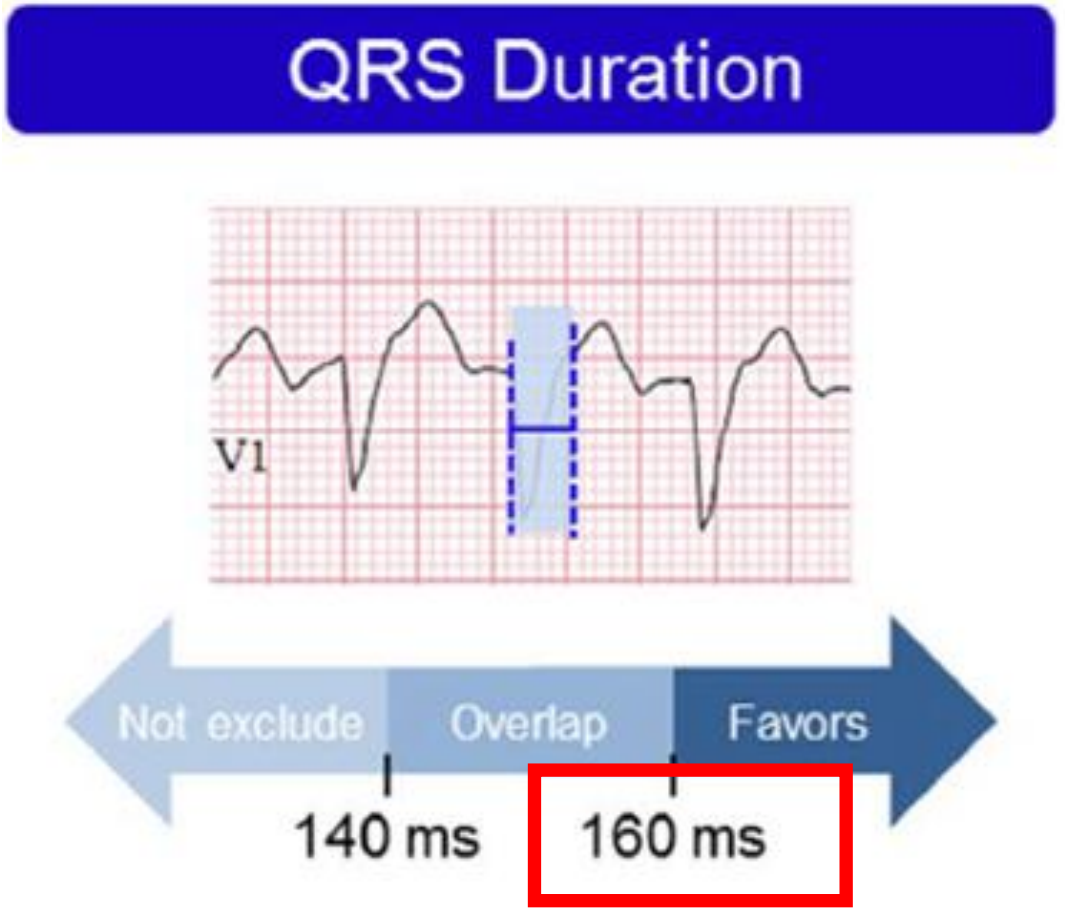

Ventricular Tachycardia

Kashou AH, Noseworthy PA, DeSimone CV, Deshmukh AJ, Asirvatham SJ, May AM. Wide Complex Tachycardia Differentiation: A Reappraisal of the State-of-the-Art. J Am Heart Assoc. 2020

3. Concordance

- Concordance in precordial leads V1-V6
- Positive concordance suggests a basal origin of VT
- Negative concordance suggests an apical origin of VT

Prystowsky E.N., & Klein G.J., & Daubert J.P (2020). *Cardiac Arrhythmias: Interpretation, Diagnosis, and Treatment, 2e*.

Ventricular Tachycardia

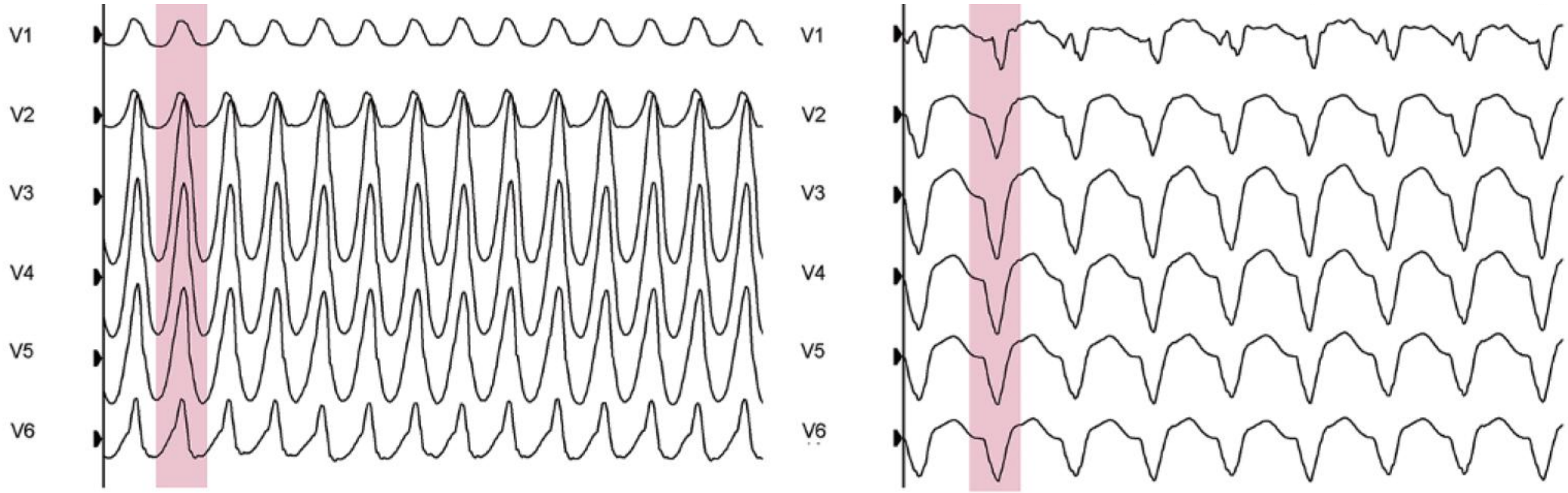

Gianni, Carola & Chen, Qiong & Canpolat, Uğur & Della Rocca, Domenico & Al-Ahmad, Amin & Burkhardt, John & Natale, Andrea. (2020). Wide Complex Tachycardia.

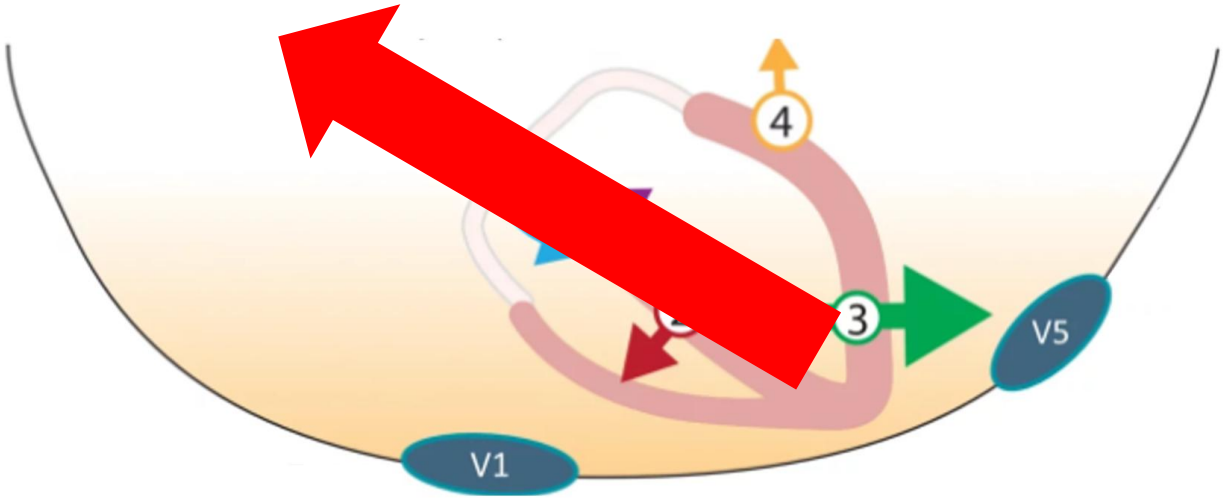

Apical origin of VT

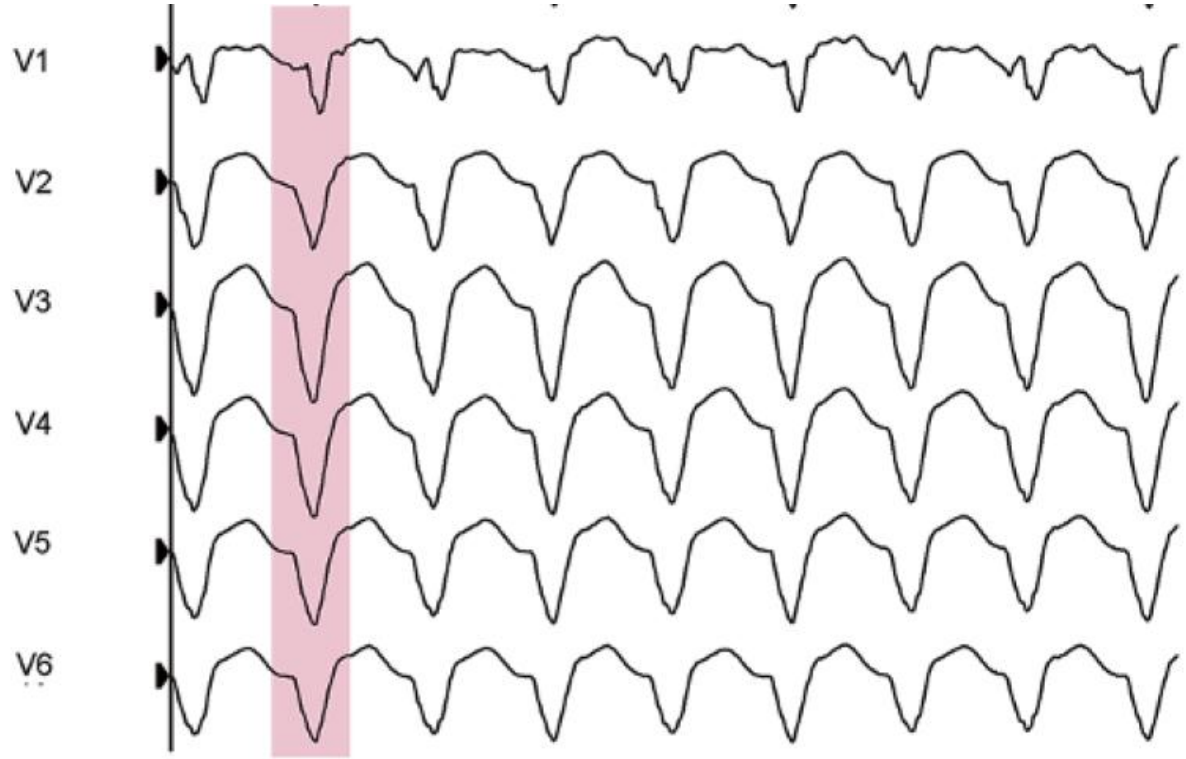

Negative concordance

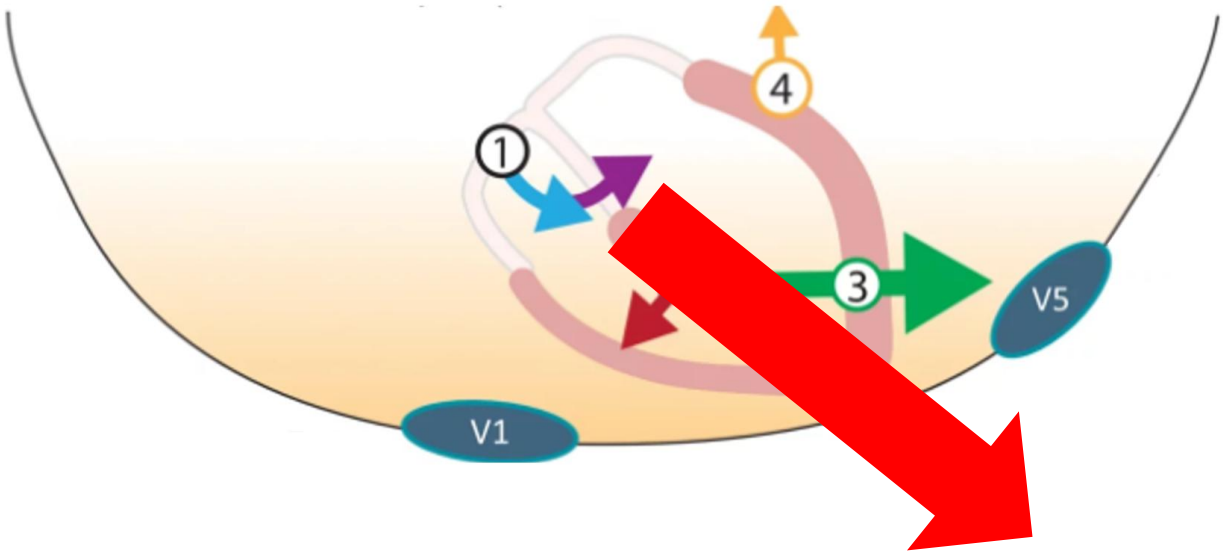

Basal origin of VT

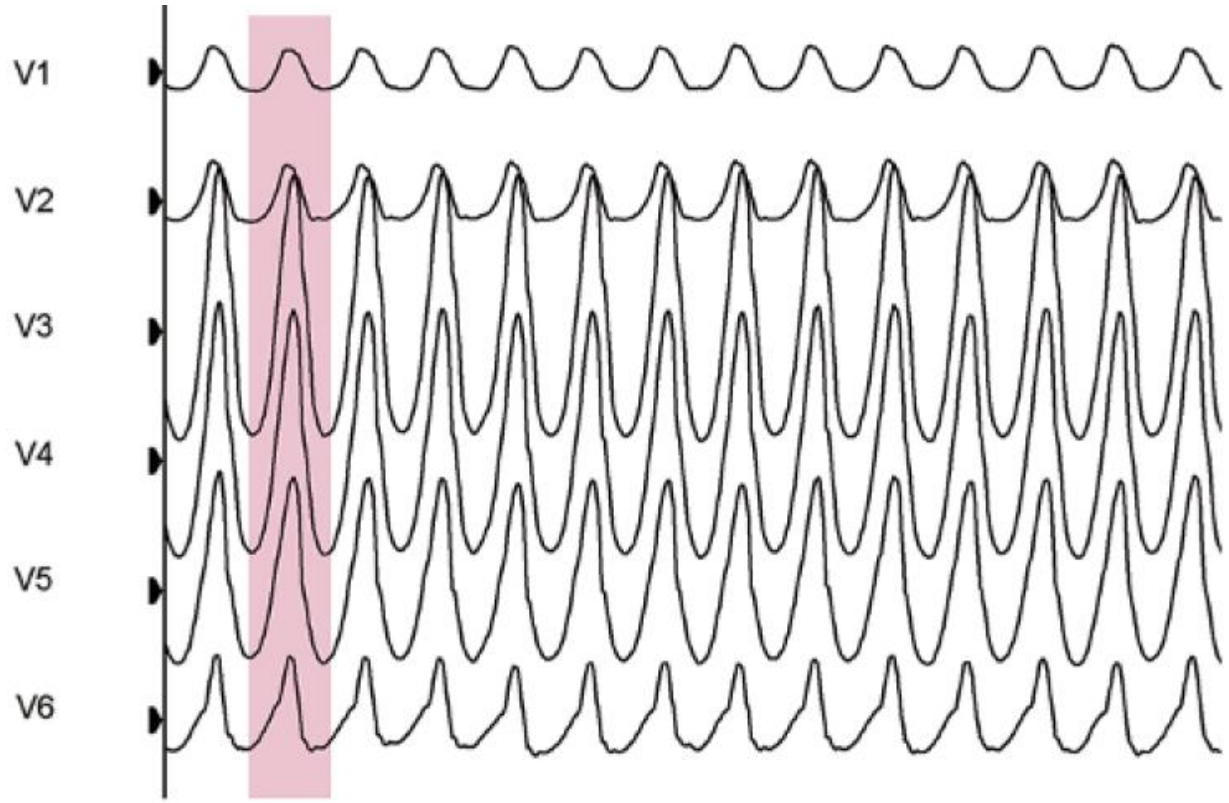

Positive concordance

4. Morphology of QRS

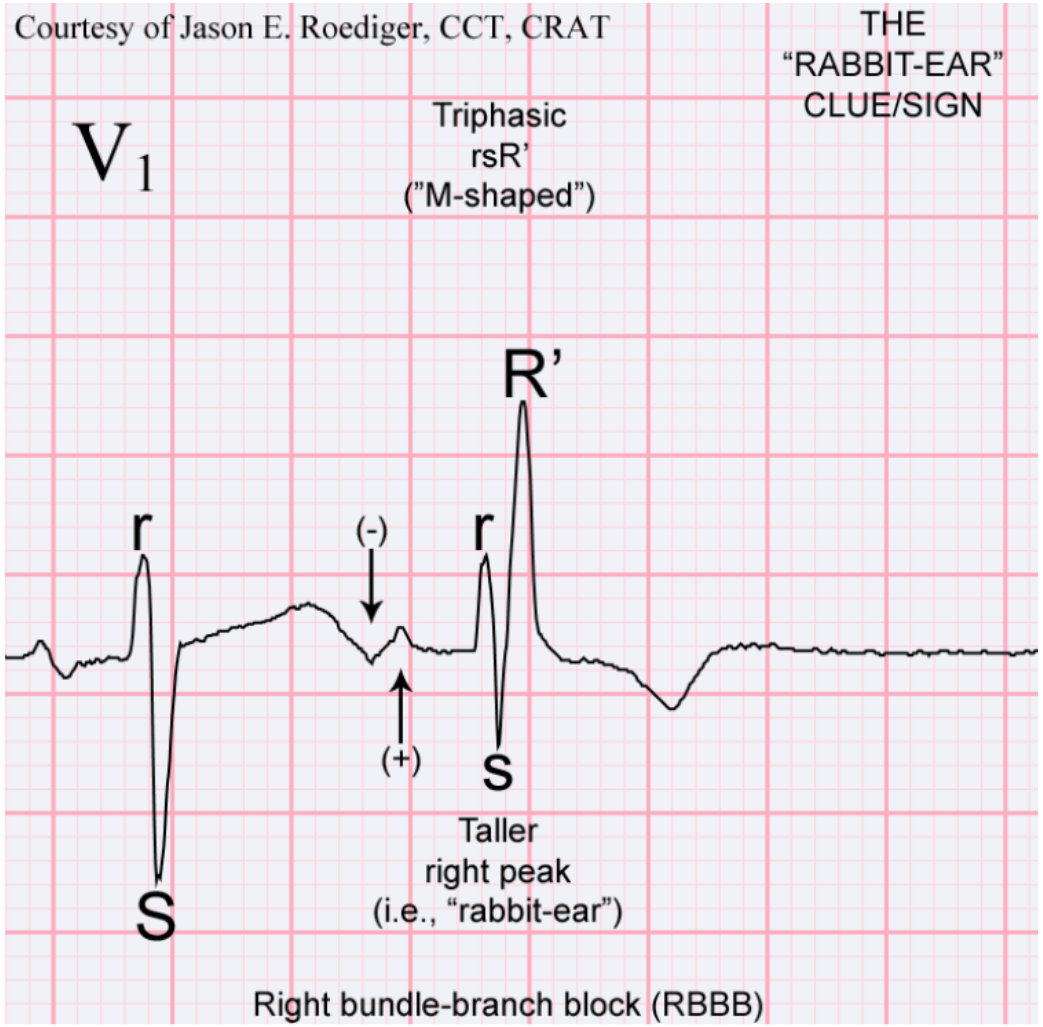

ecgguru.com/ecg/rabbit-ear-sign

Tall rabbit ear at left in V1 - VT

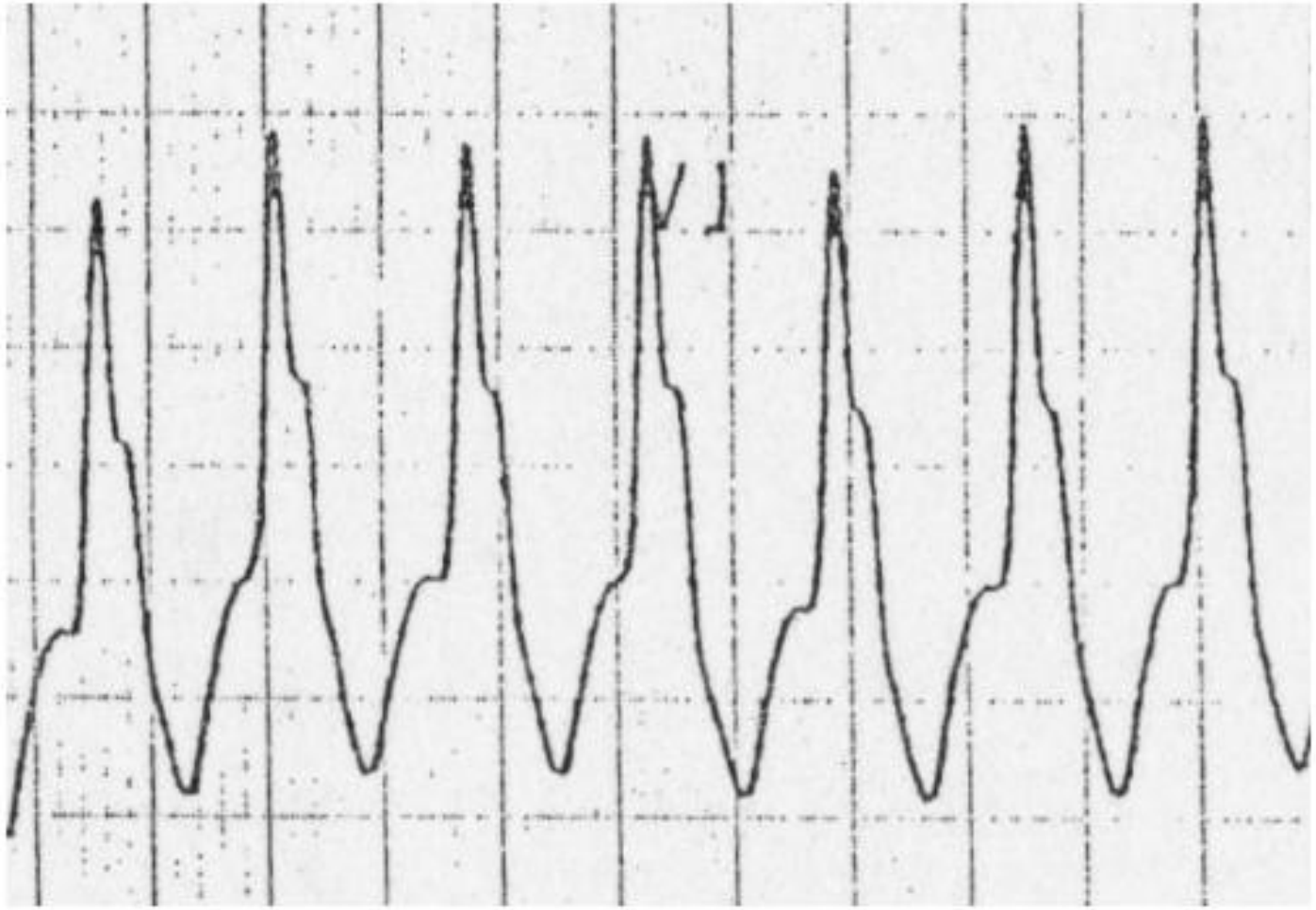

litfl.com

5. If you are not sure….

TREAT AS
Ventricular Tachycardia



ECG application in echocardiography

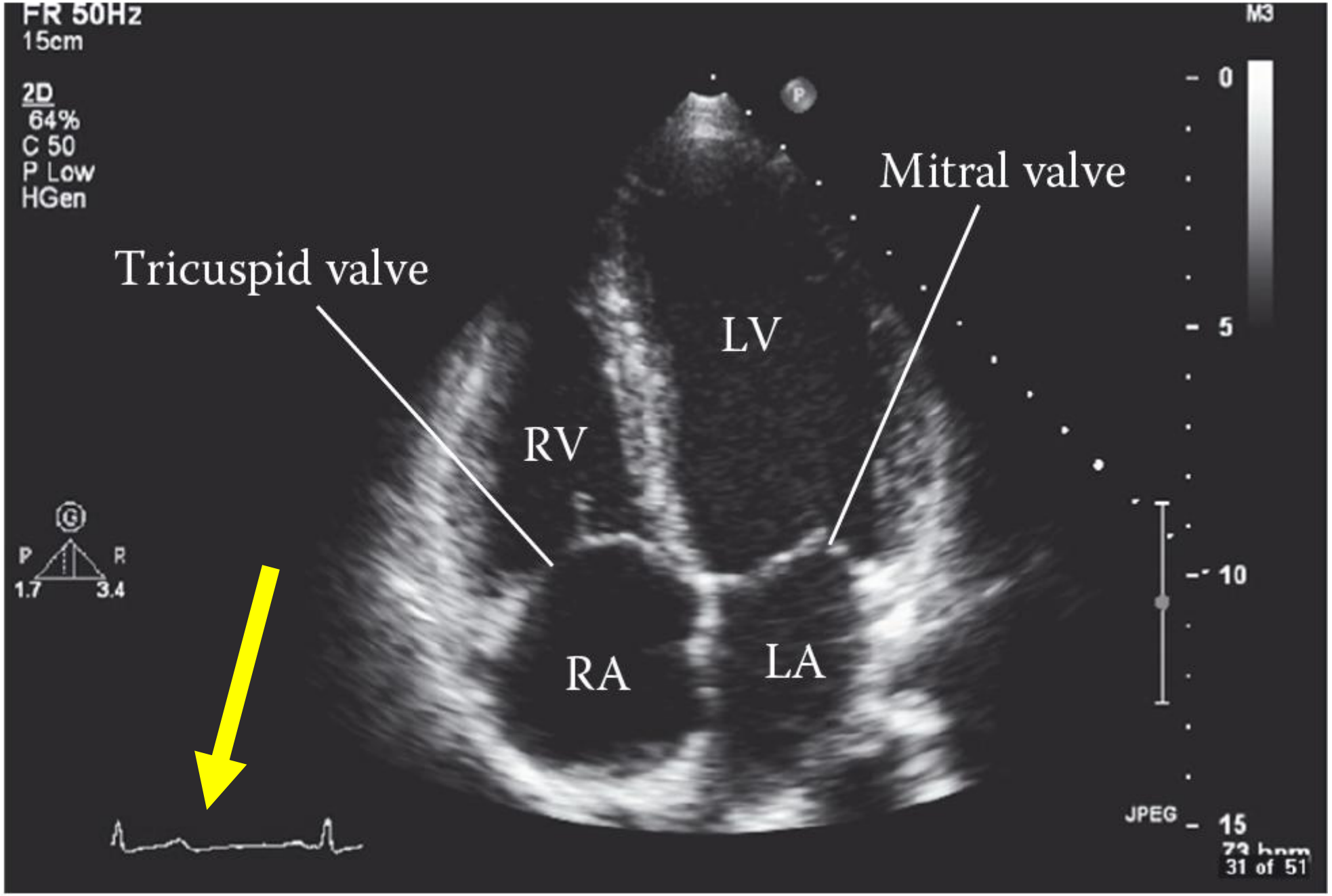
FR 50Hz
15cm
2D
64%
C 50
P Low
HGen
M3
0
5
10
15
JPEG
31 of 51
Tricuspid valve
Mitral valve
LV
RV
RA
LA
P
R
1.7
3.4

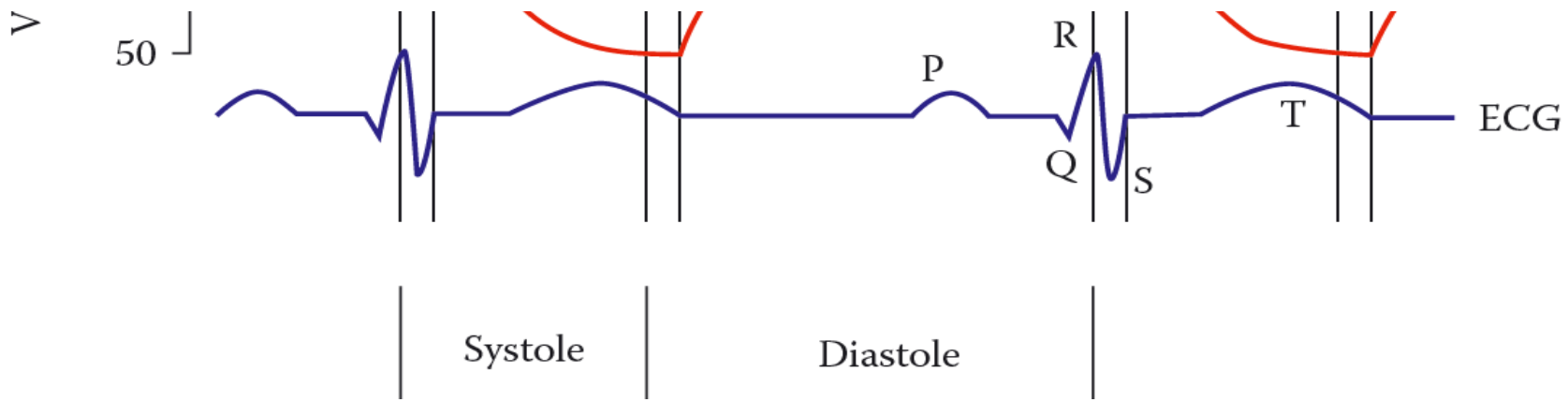
V
50
P
R
Q
S
T
ECG
Systole
Diastole



Premature Ventricular Complexes (PVCs)

24 years old

Male

Bradycardia

HR 48/min

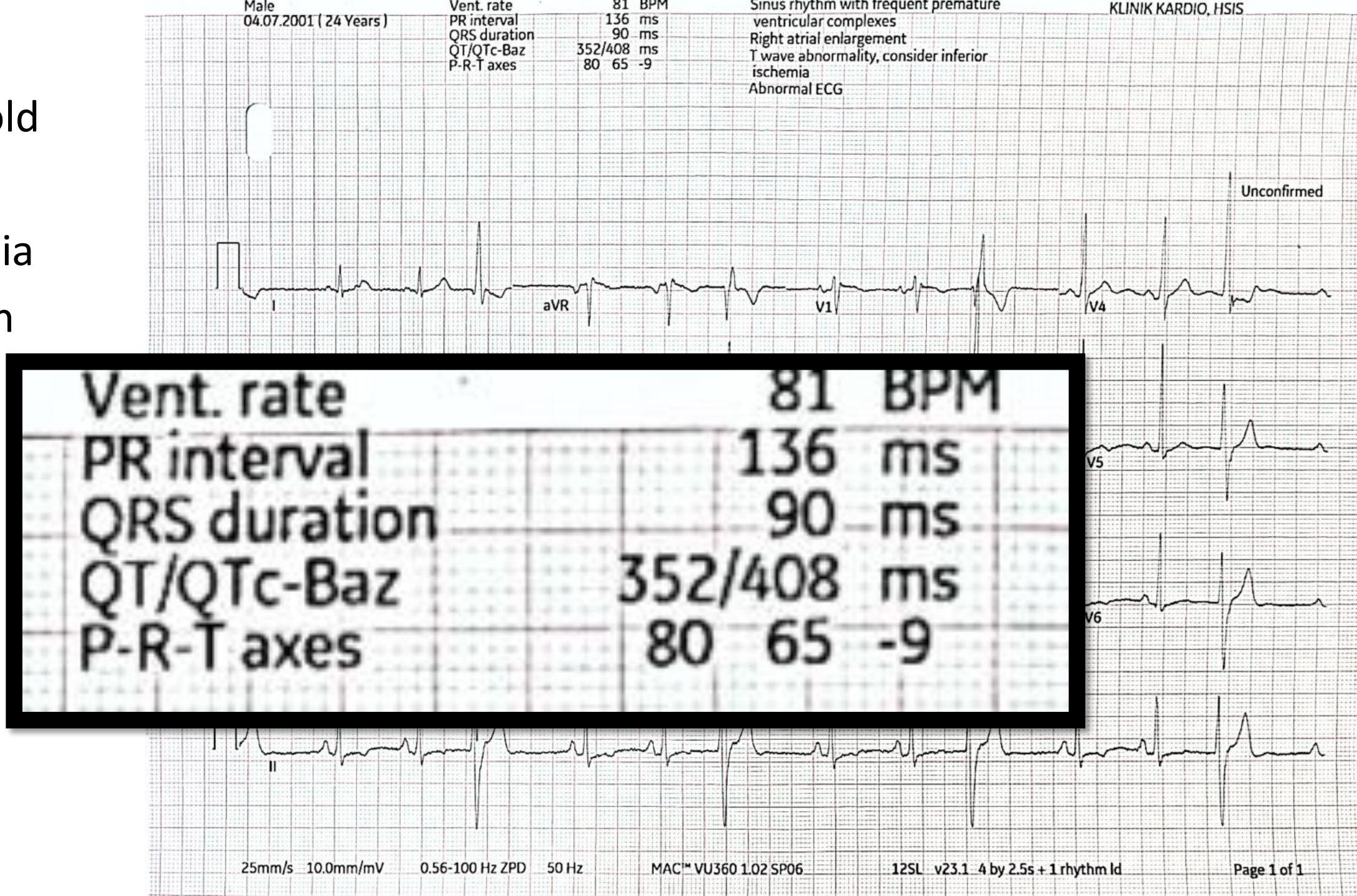

Vent. rate		81	BPM
PR interval		136	ms
QRS duration		90	ms
QT/QTc-Baz	352/408		ms
P-R-T axes	80	65	-9

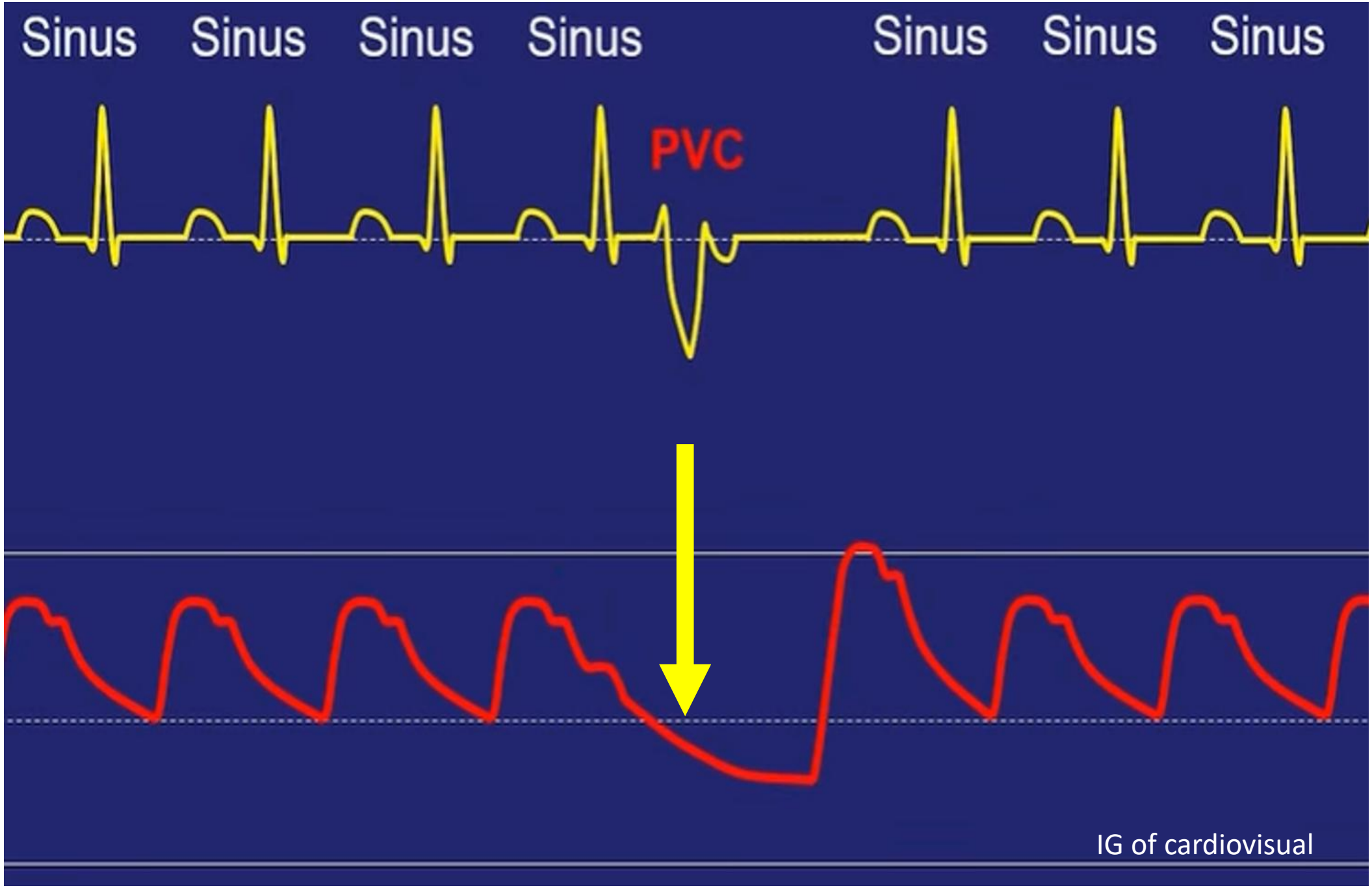
Sinus
Sinus
Sinus
Sinus
Sinus
Sinus
Sinus
PVC
120 mmHg
80 mmHg
IG of cardiovisual


%SpO2
98
bpmPR
75

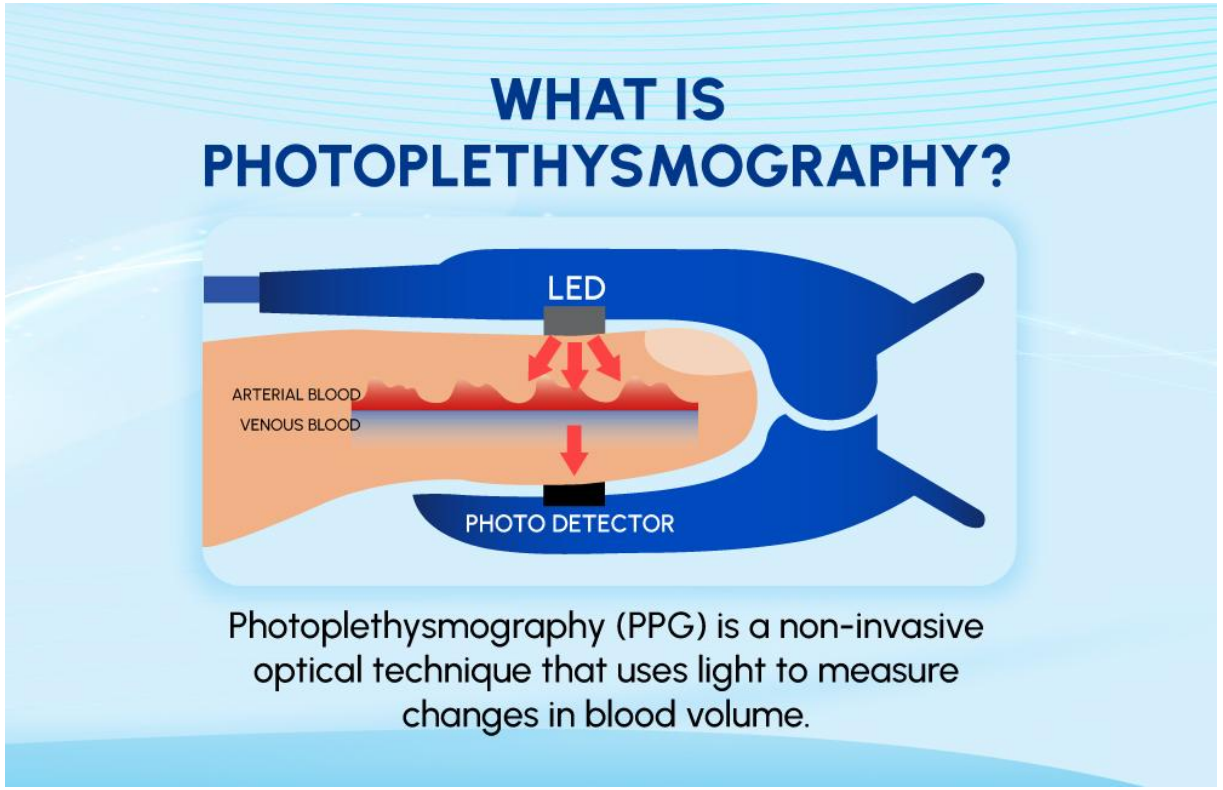
WHAT IS
PHOTOPLETHYSMOGRAPHY?
LED
ARTERIAL BLOOD
VENOUS BLOOD
PHOTO DETECTOR
Photoplethysmography (PPG) is a non-invasive optical technique that uses light to measure changes in blood volume.



SR: 8 beats x 6 =

48 BPM

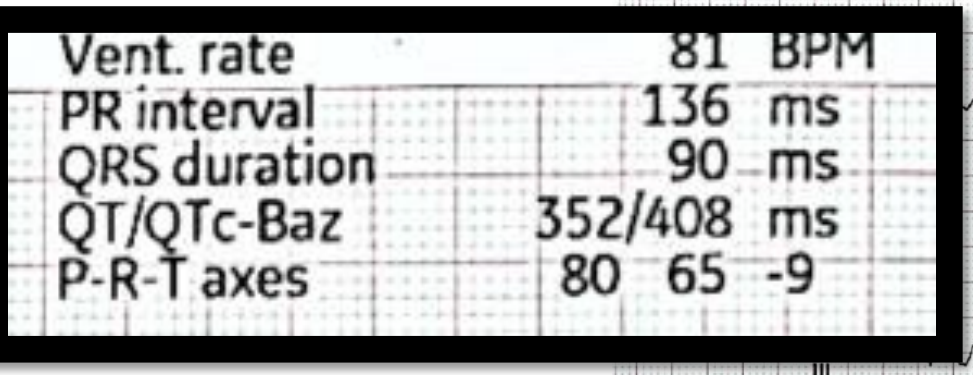

ALL: 13 beats x 6 =

78 BPM

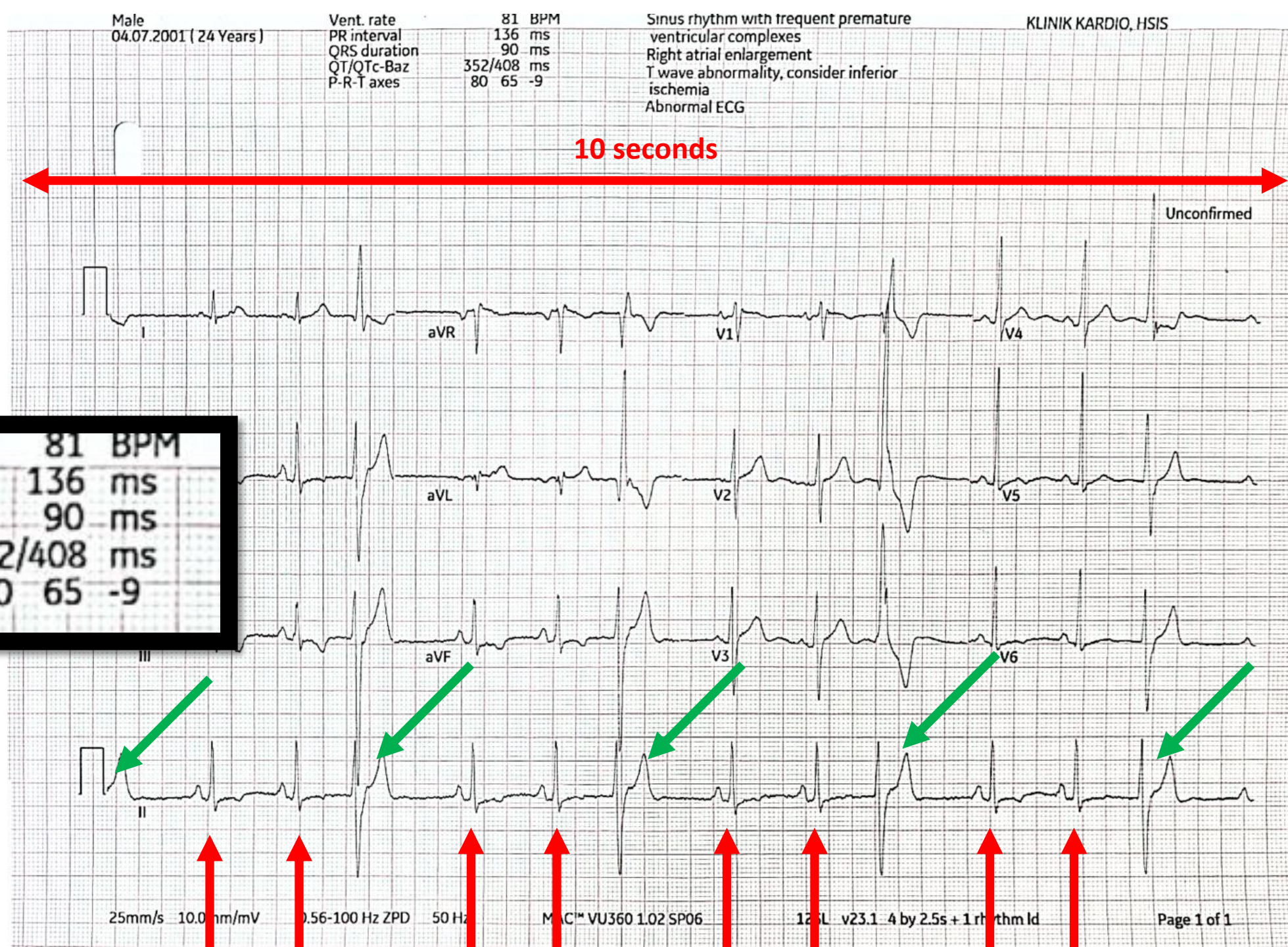

Can we start beta blocker for this patient?

Answer: YES!

What to look in QRS complex in syncope patient?



Mnemonics: Causes of Syncope

Brugada

Delta wave (WPW)

Epsilon wave

LEFT ventricular hypertrophy

RIGHT ventricular strain

39 years old male

- Active smoker
- Family history of sudden death of his siblings
- Referred for syncope 2x prior

- BP 120/70mmHg
- HR 60/min

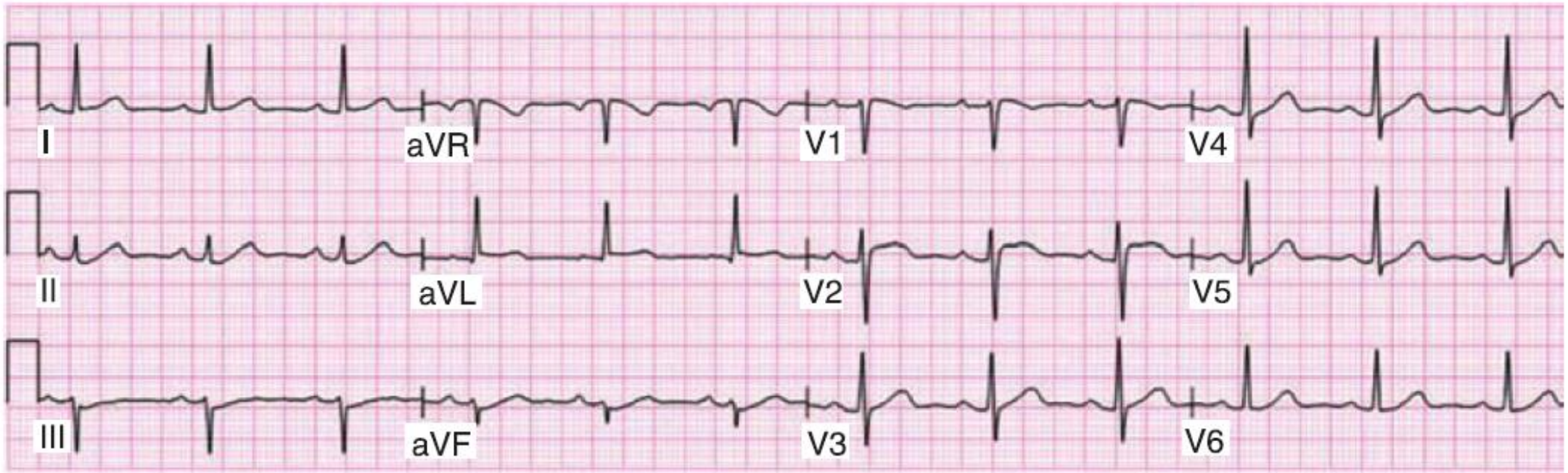

Cardiac Arrhythmias: Interpretation, Diagnosis and Treatment, Second Edition, Eric N. Prystowsky, George J. Klein

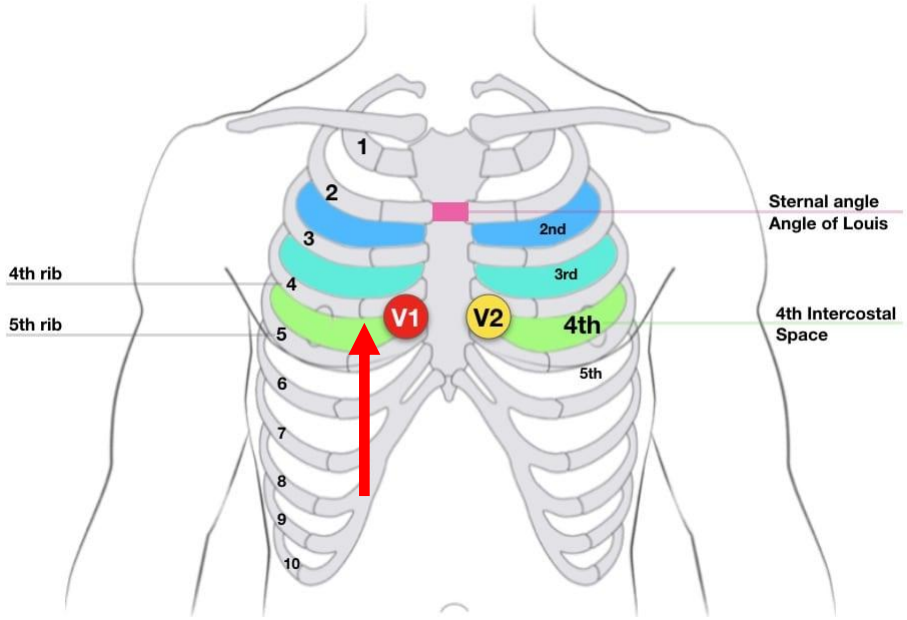

High precordial leads

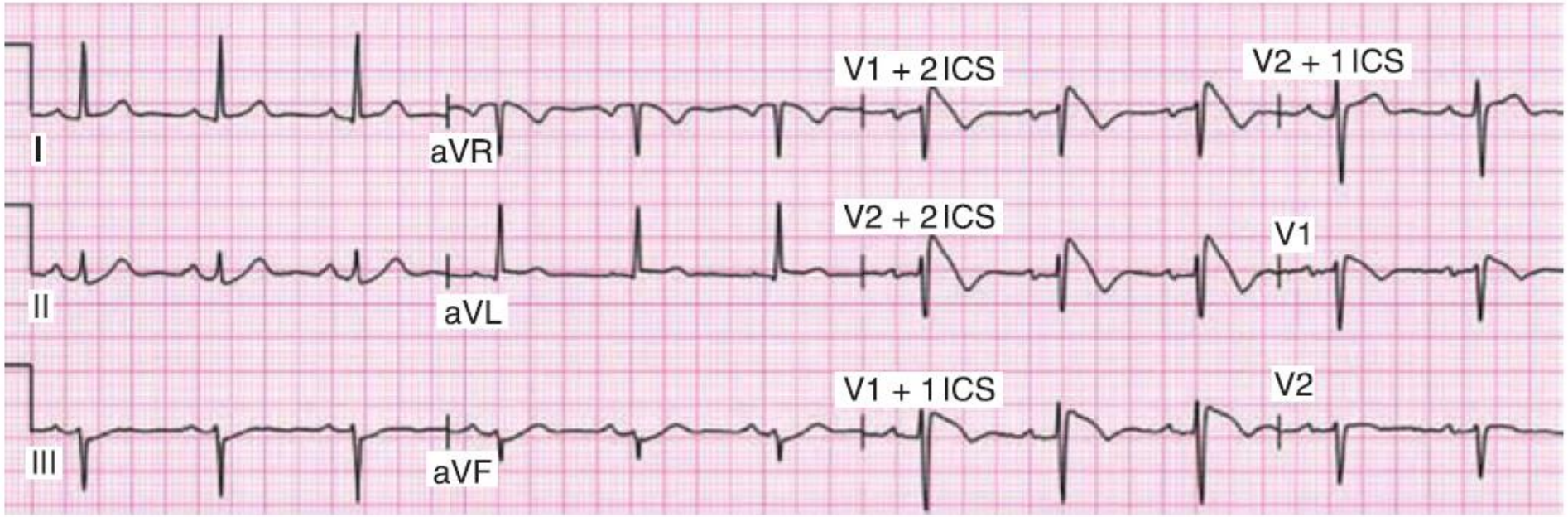

Cardiac Arrhythmias: Interpretation, Diagnosis and Treatment, Second Edition, Eric N. Prystowsky, George J. Klein

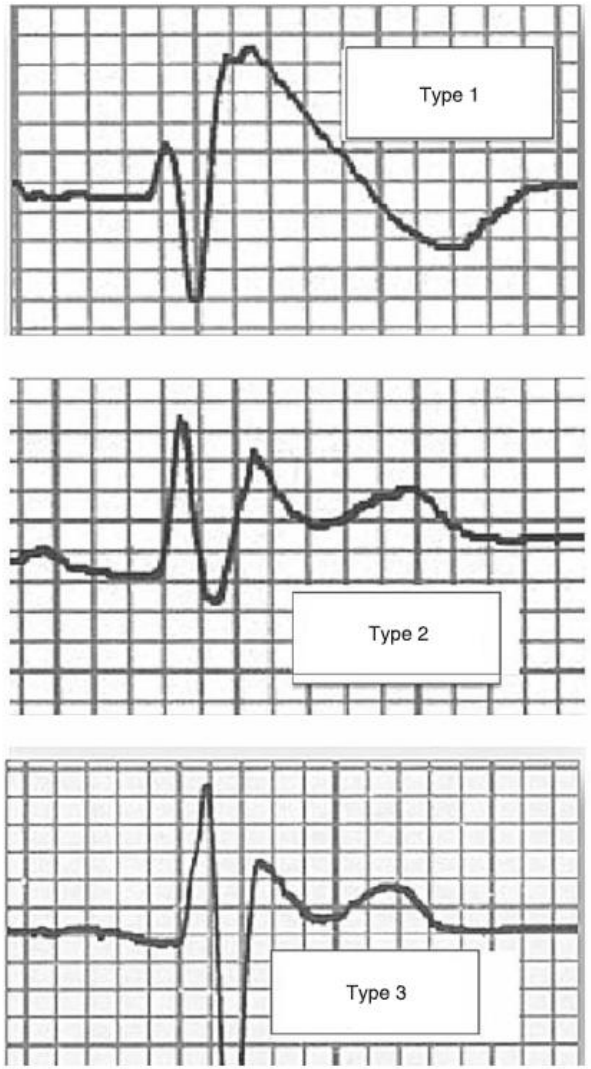

Brugada pattern ECG

Cardiac Arrhythmias: Interpretation, Diagnosis and Treatment, Second Edition, Eric N. Prystowsky, George J. Klein

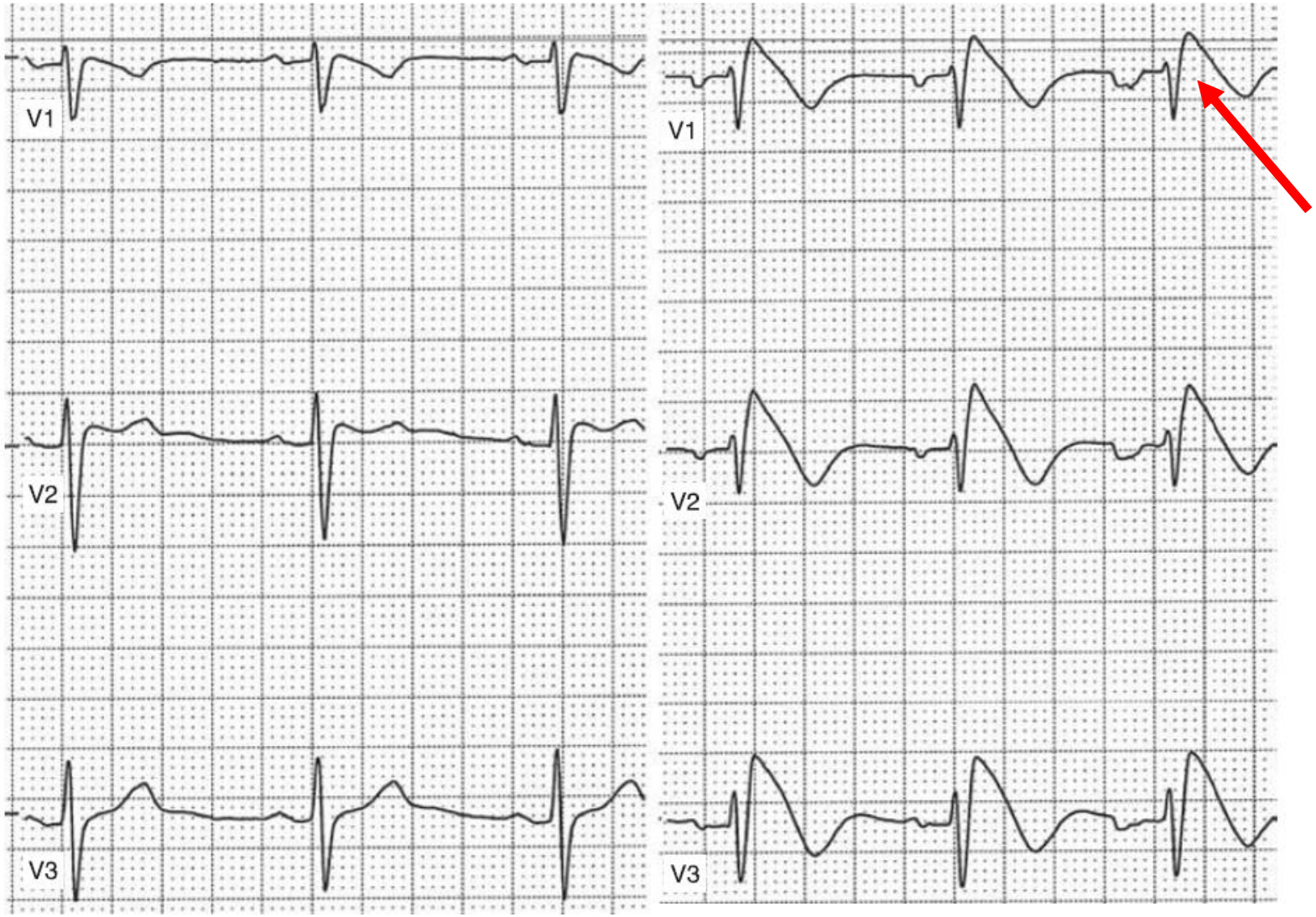

After drug challenge (Ajmaline)



Cove

Cardiac Arrhythmias: Interpretation, Diagnosis and Treatment, Second Edition, Eric N. Prystowsky, George J. Klein

Brugada syndrome - Treatment

- Implantable cardioverter defibrillator (ICD)
- Endocardial / epicardial ablation

Endocardial / epicardial ablation

Circulation

ORIGINAL RESEARCH ARTICLE

Long-Term Outcomes of Brugada Substrate Ablation: A Report from BRAVO (Brugada Ablation of VF Substrate Ongoing Multicenter Registry)

Koonlawee Nademanee, MD; Fa-Po Chung, MD; Frederic Sacher, MD, PhD; Akihiko Nogami, MD, PhD; Hiroshi Nakagawa, MD, PhD; Chenyang Jiang, MD; Meleze Hocini, MD; Elijah Behr, MA, MBBS; Gumpanart Veerakul, MD; Jaap Jan Smit, MD, PhD; Arthur A.M. Wilde, MD, PhD; Shih-Ann Chen, MD; Kohei Yamashiro, MD; Yuichiro Sakamoto, MD; Itsuro Morishima, MD, PhD; Mithilesh K. Das, MD; Apichai Khongphatthanayothin, MD; Saran Vardhanabhuti, PhD; Michel Haissaguerre, MD

Clinical Perspective

What Is New?

- In a large cohort of highly symptomatic patients with Brugada syndrome, epicardial substrate ablation treatment is safe and effective in preventing ventricular fibrillation recurrence during a long-term follow-up period.
- Normalization of type 1 Brugada ECG after ablation, both with and without sodium channel blockade, suggests elimination of ventricular fibrillation substrates and is associated with excellent outcomes, resulting in patients with no overlapping early repolarization ECG pattern and free of ventricular fibrillation recurrence.

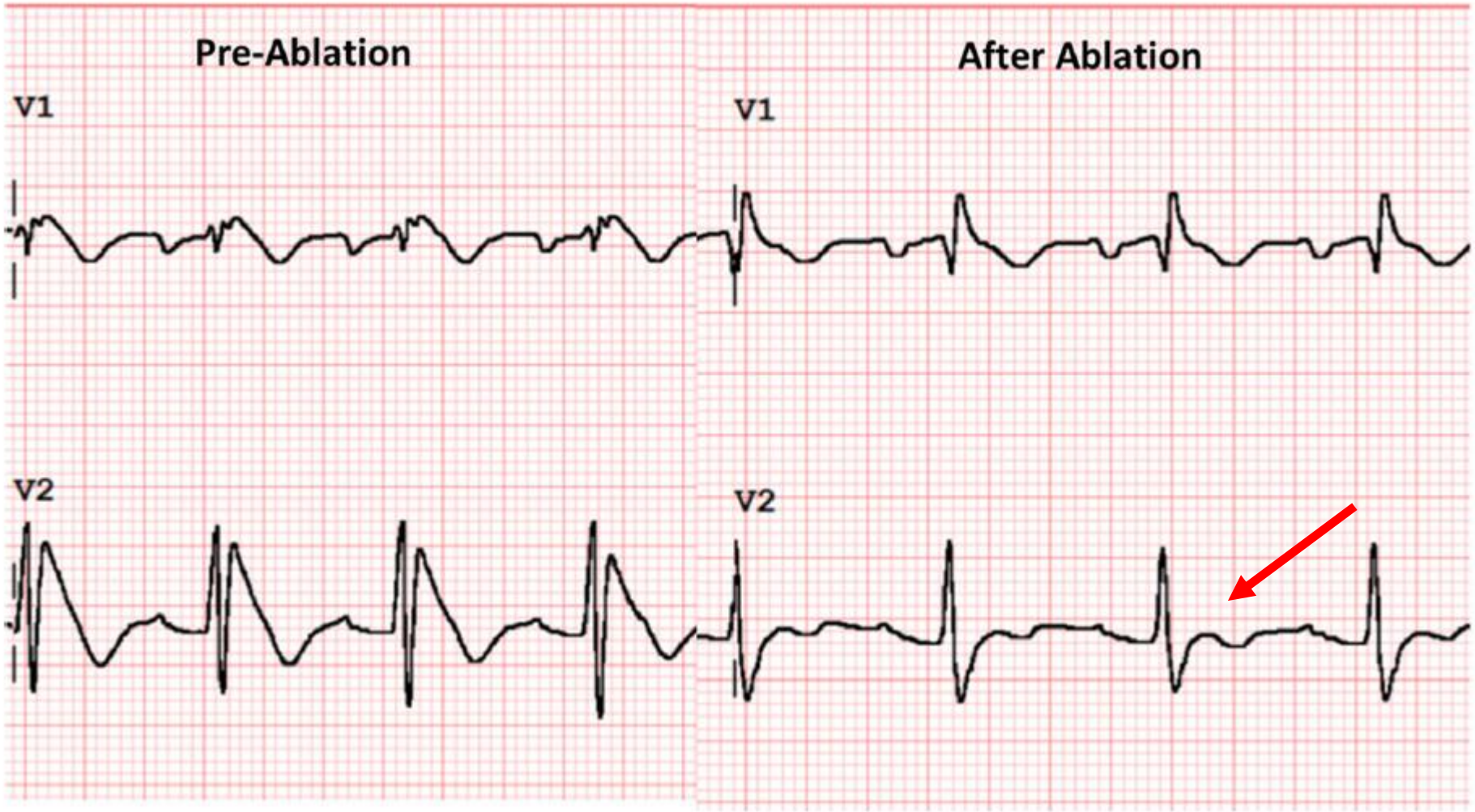

https://doi.org/10.1007/s11886-021-01479-2

27 years old male

- Active smoker
- Palpitation for 3 months
- Had presyncope prior to this

- GCS 15/15
- BP 120/70 mmHg
- HR 70/min

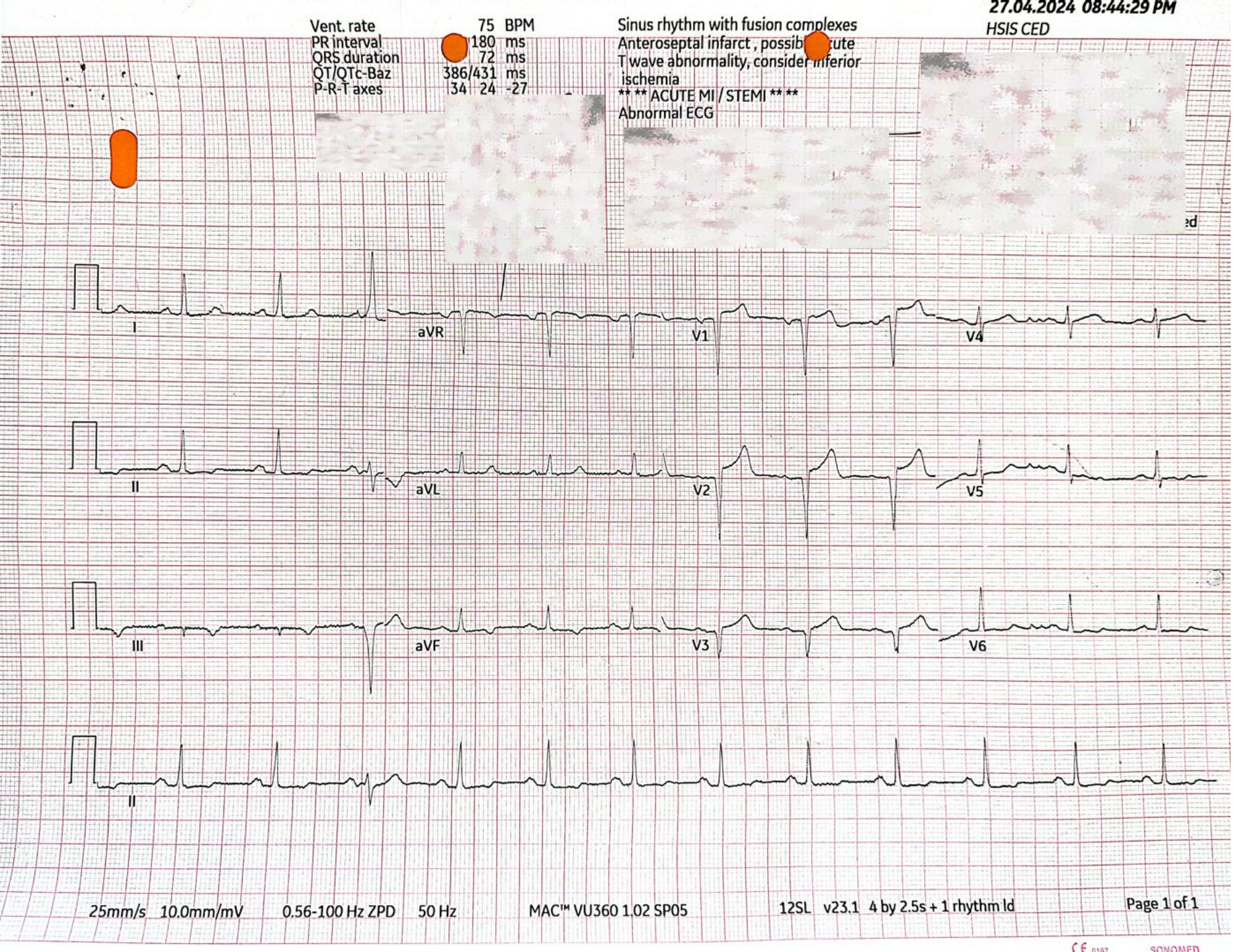

Day 1 admission

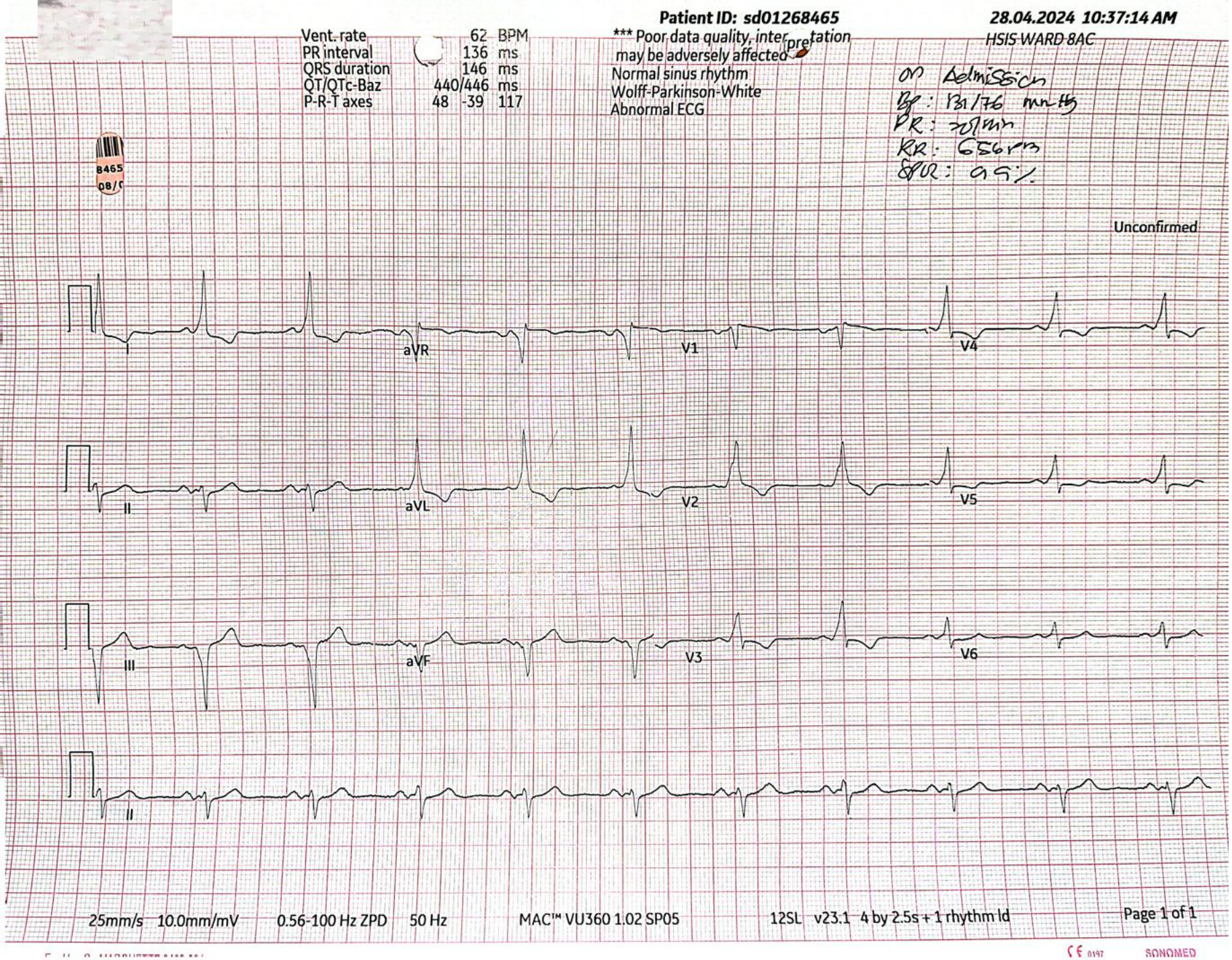

Day 2 admission

Wrong patient?

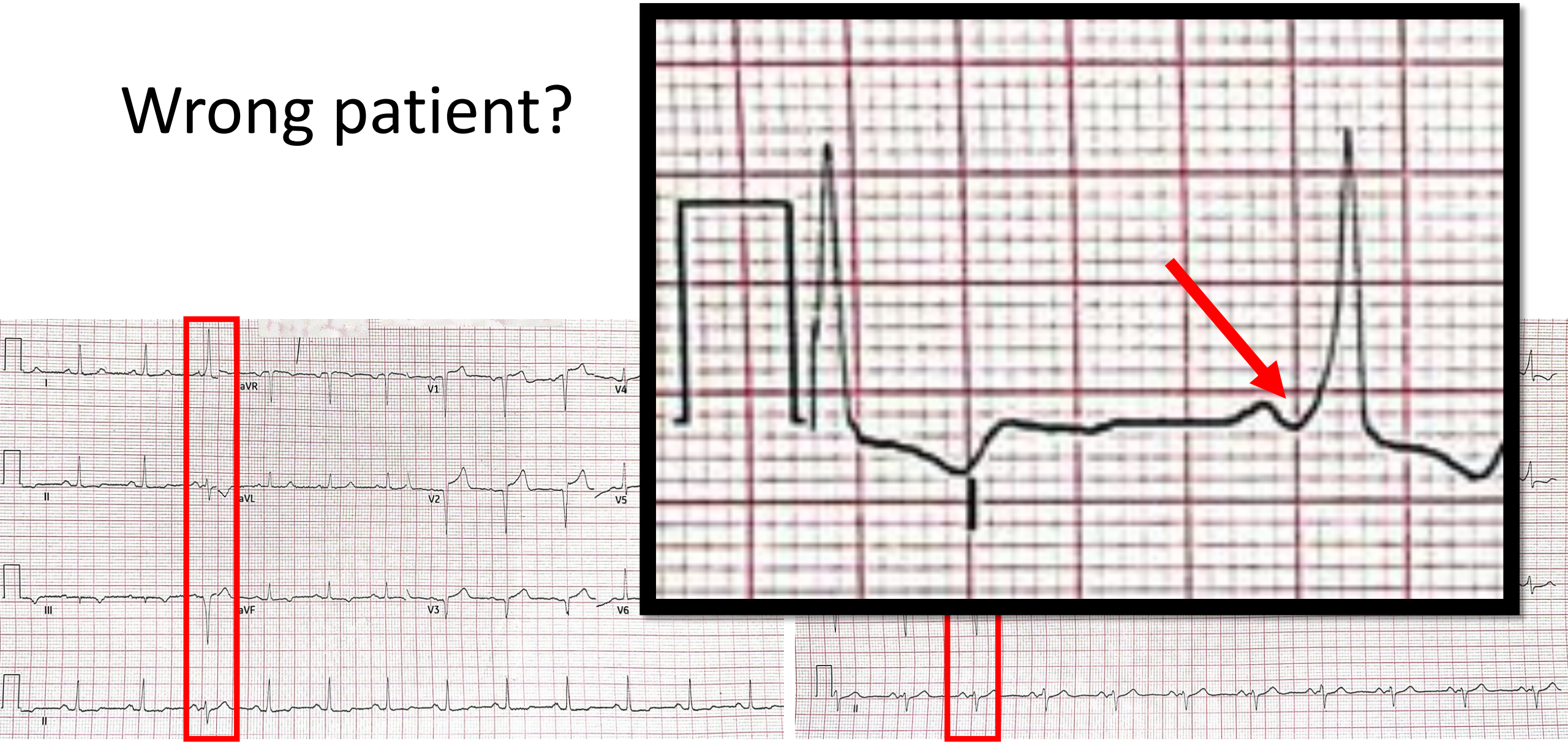

Intermittent pre-excitation (WPW)

Where is the accessory pathway?

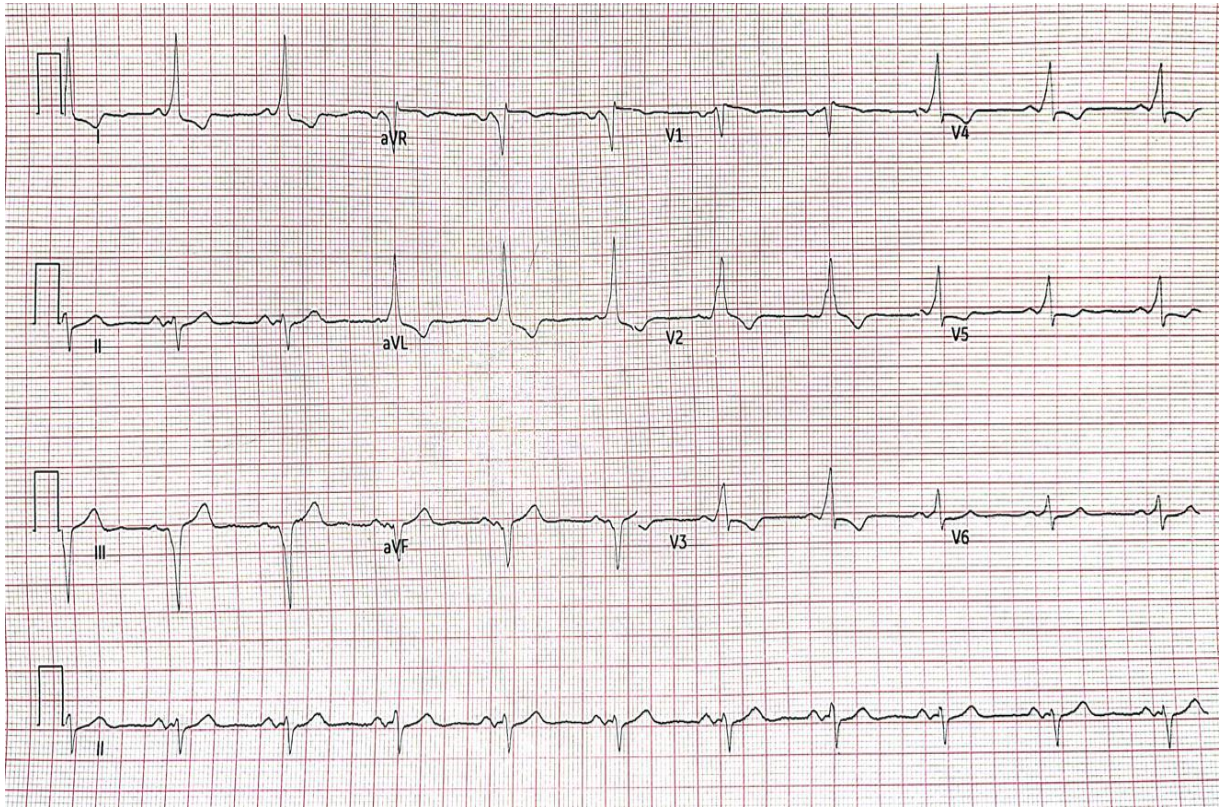

Easy-WPW

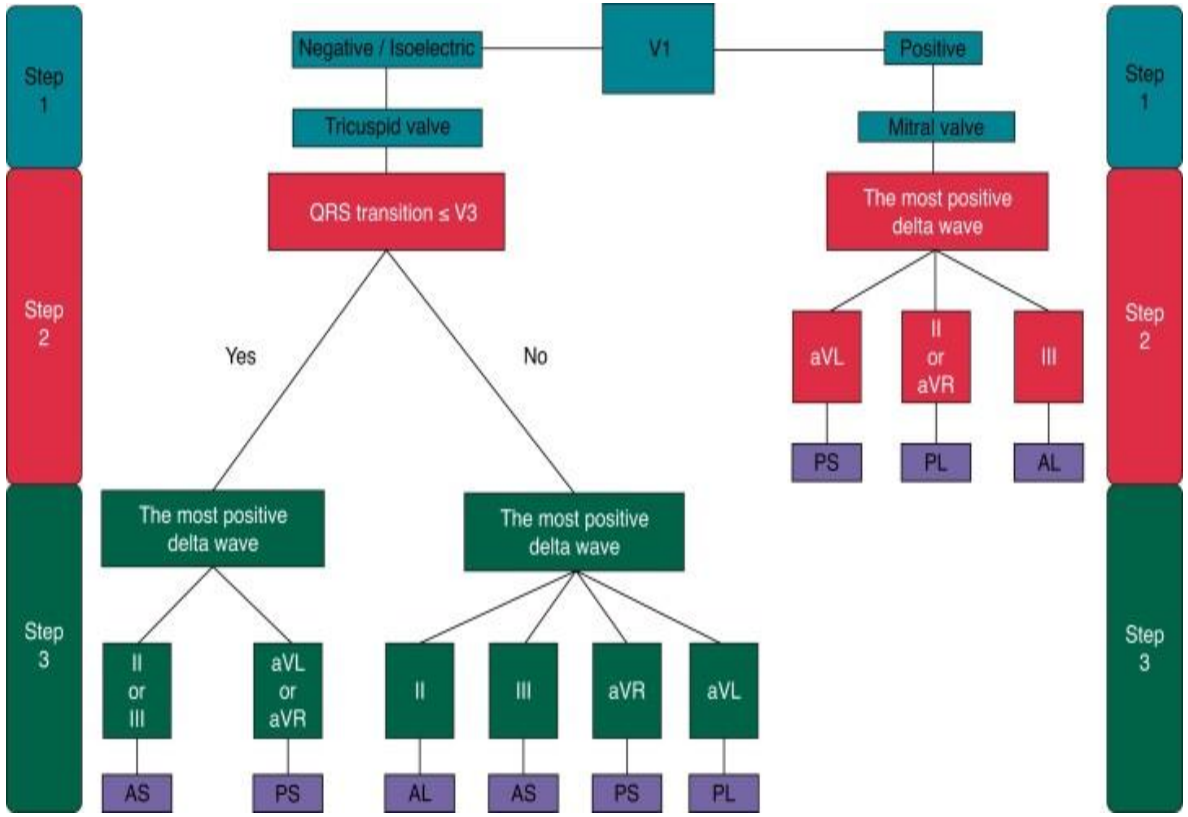

doi: 10.1093/europace/euac216

Epsilon wave - ARVC

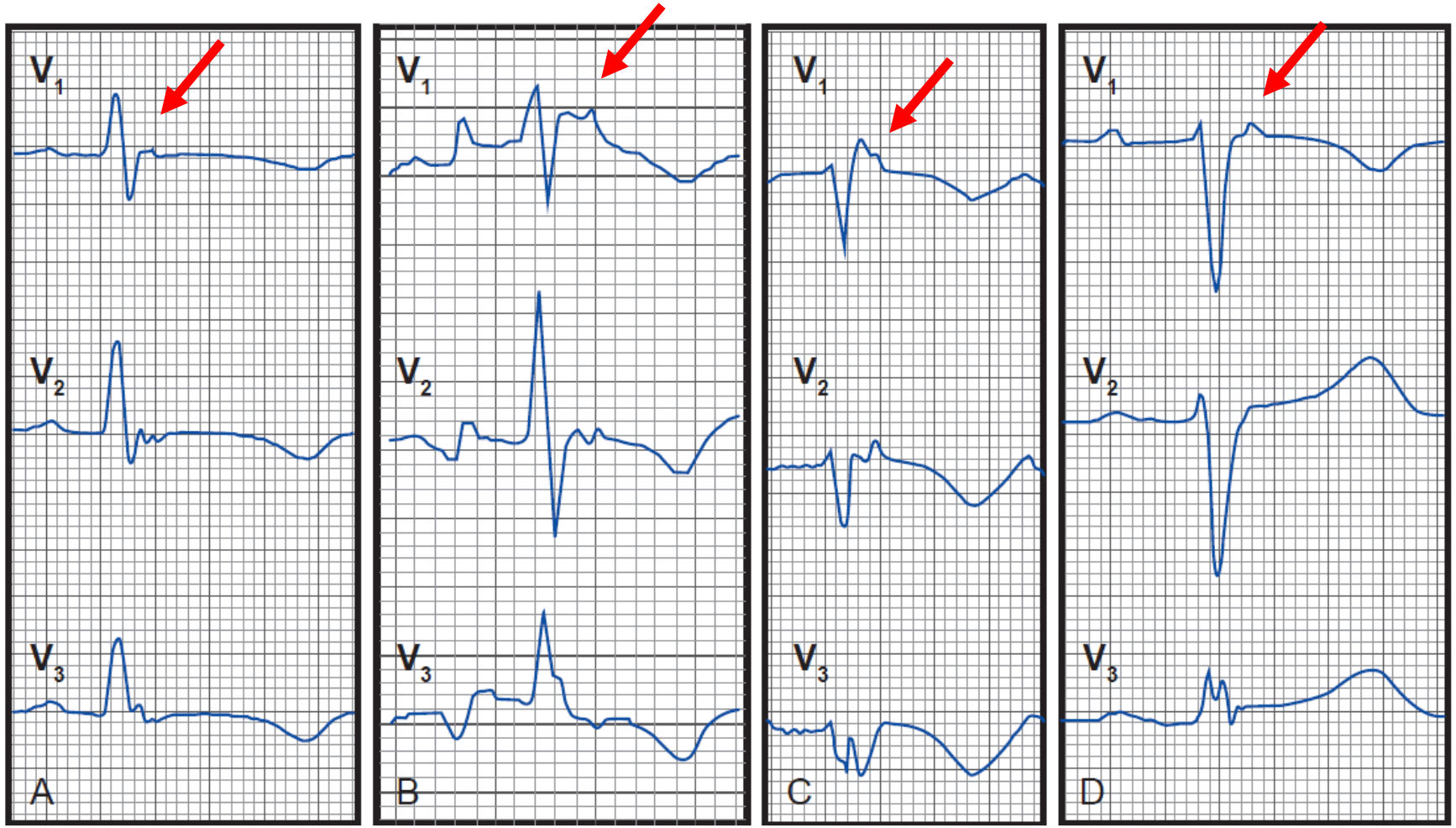

Braunwald's Clinical Arrhythmology and Electrophysiology, 3rd Edition

Take home messages:

1. Importance of vector & axis
2. Basic of ventricular depolarization
3. Identify the clues of SVT or VT
4. Look hard for ECG signs in patient with syncope

