BASIC ECG INTERPRETATION

SALLEHUDDIN BIN NOORDIN

PENOLONG PEGAWAI PERUBATAN TBK (U6)

JABATAN KARDIOLOGI PUSAT JANTUNG HOSPITAL SULTAN IDRIS SHAH

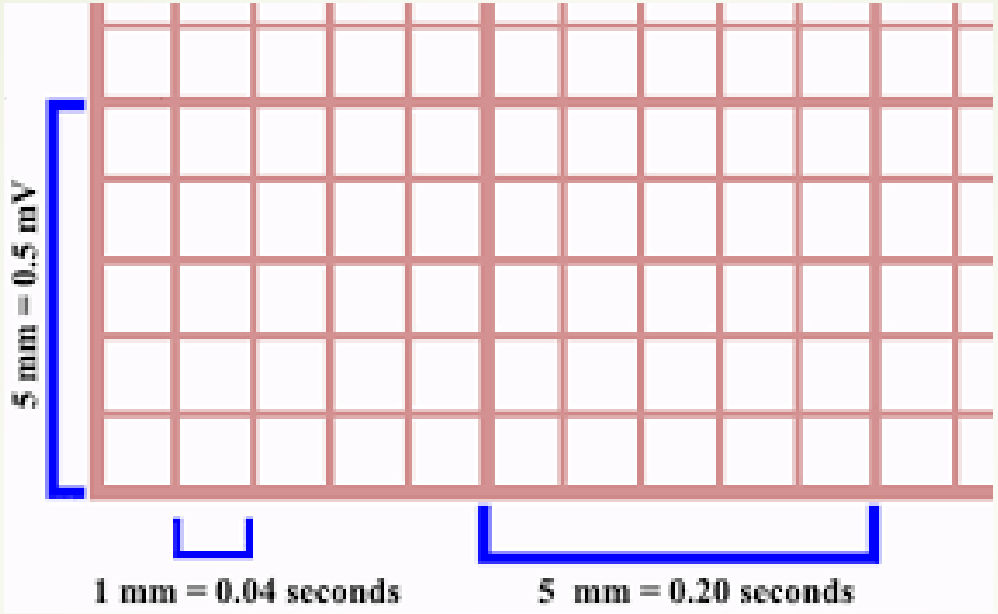

•**ECG Grid:** Each small square on the ECG paper represents 0.04 seconds (40 milliseconds) horizontally and 0.1 mV vertically. Five small squares make up one large square, which represents 0.2 seconds (200 milliseconds) horizontally and 0.5 mV vertically.

•**Leads:** An ECG is recorded using multiple leads, each providing a different view of the heart's electrical activity. The standard 12-lead ECG includes limb leads (I, II, III, aVR, aVL, aVF) and chest leads (V1-V6).

ECG CALIBRATION

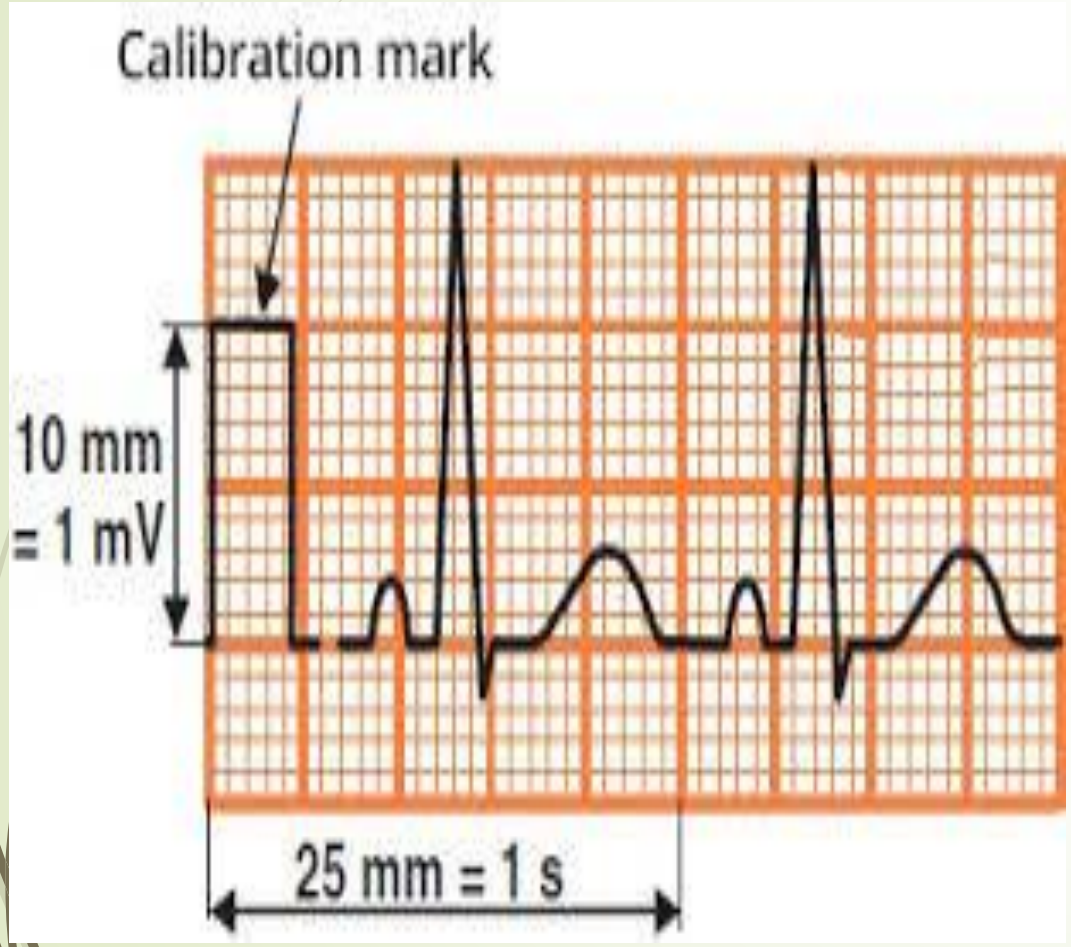

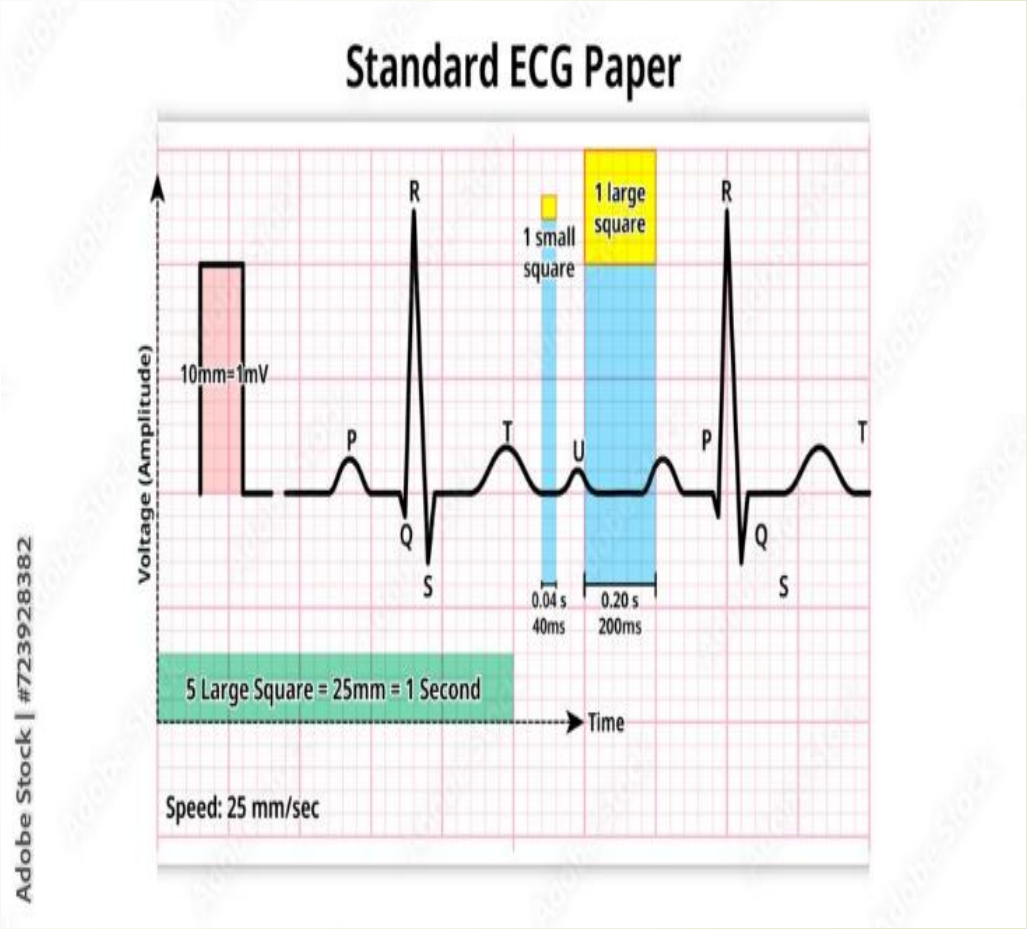

CARDIAC CONDUCTION SYSTEM

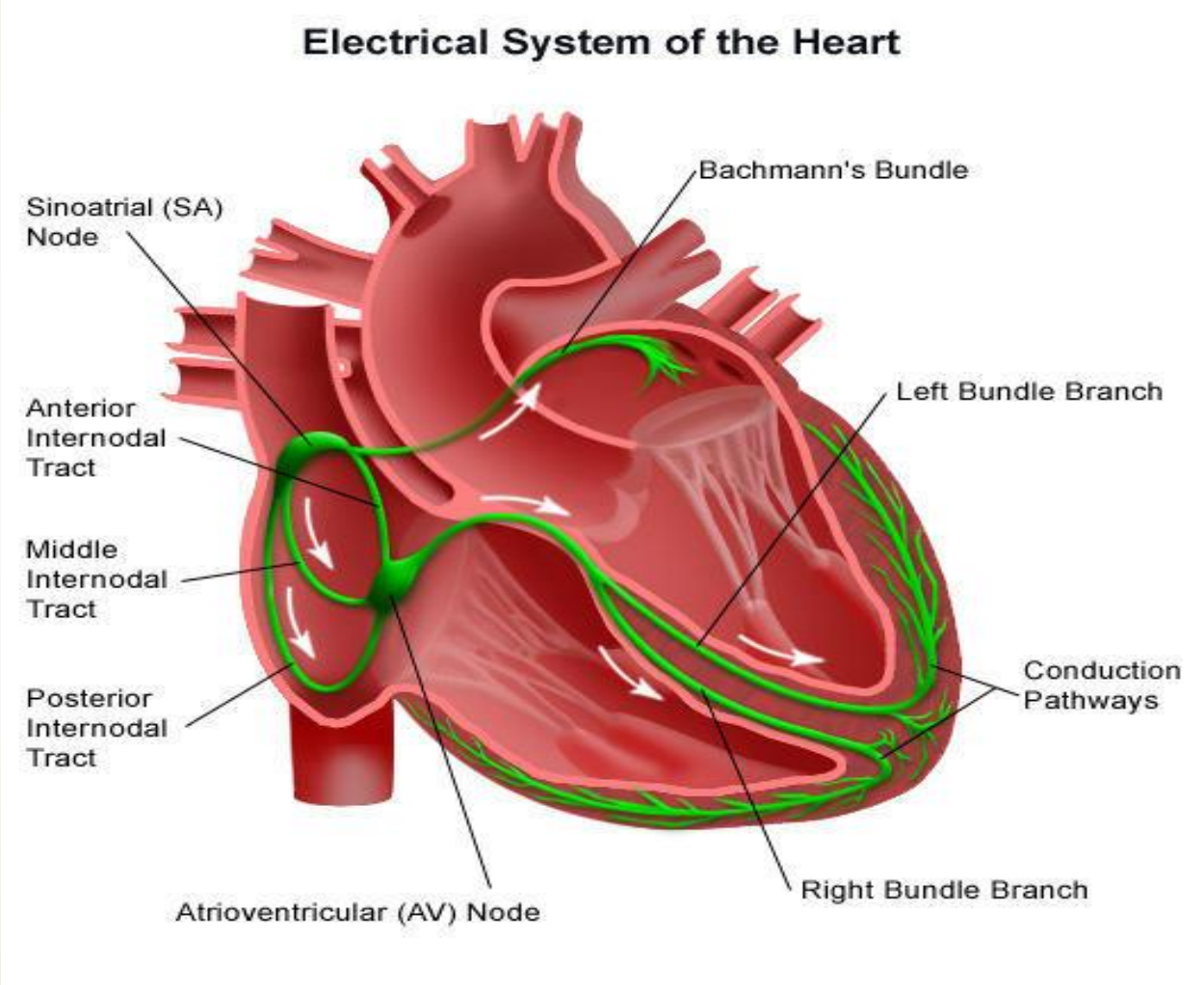

THE INTERVALS

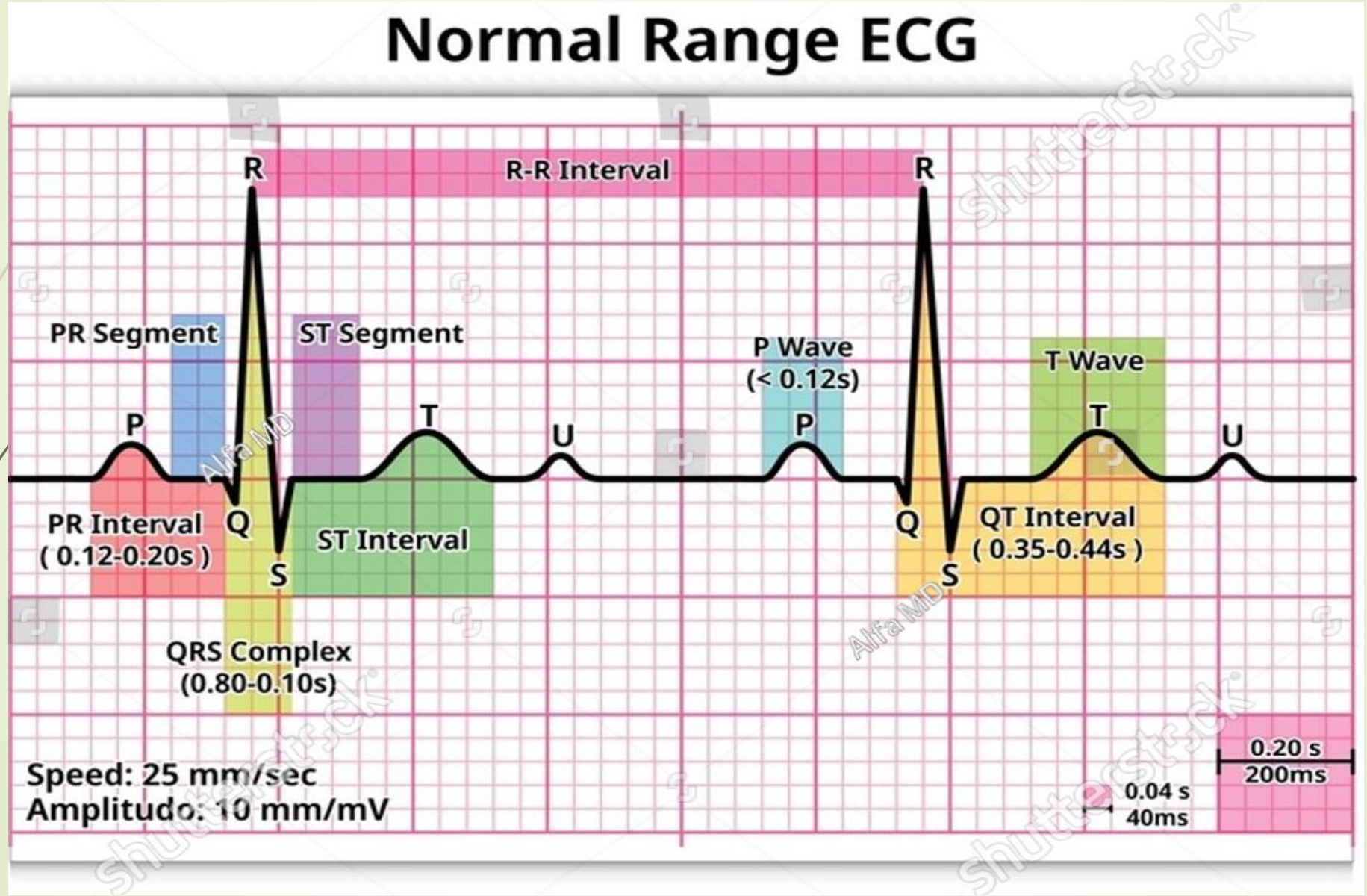

UNDERSTANDS THE INTERVALS

P wave	represents **atrial depolarization** (contraction of the atria)
PR Interval	from **start of P to start of QRS**. Reflects atrial to ventricular conduction. **Normal: 0.12–0.20 seconds**
PR Segment	flat line between P wave and QRS. **AV node delay**
QRS Complex	represents **ventricular depolarization** (contraction of the ventricles). **Normal duration: 0.06–0.10 seconds**
ST Segment	flat line from **end of S to start of T**. Early ventricular repolarization
R-R Interval	time between R waves. **Used for heart rate calculation**
T Wave	represents **ventricular repolarization**
QT Interval	from the **start of the QRS complex to the end of the T wave**. Reflects total time for ventricular depolarization and repolarization. **Normal: ~0.35–0.44 seconds**

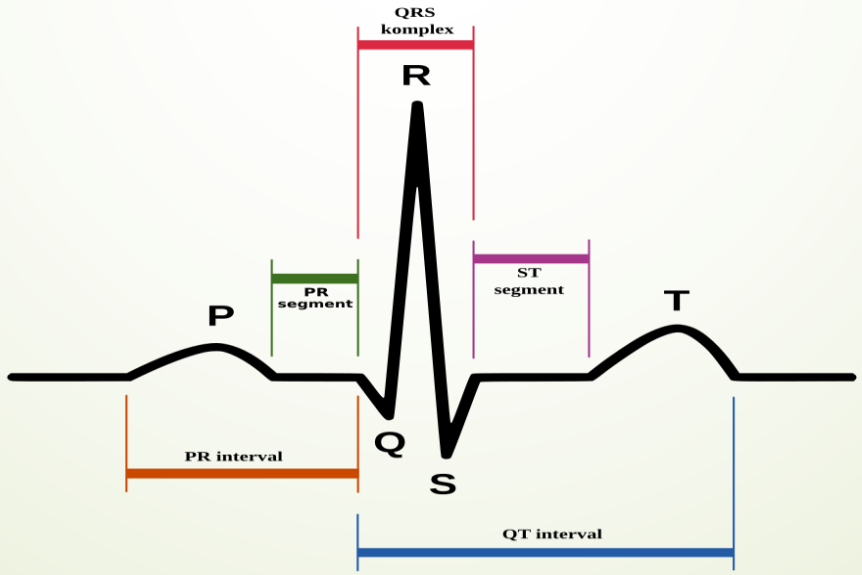

WHAT SHOULD YOU OBSERVE FIRST

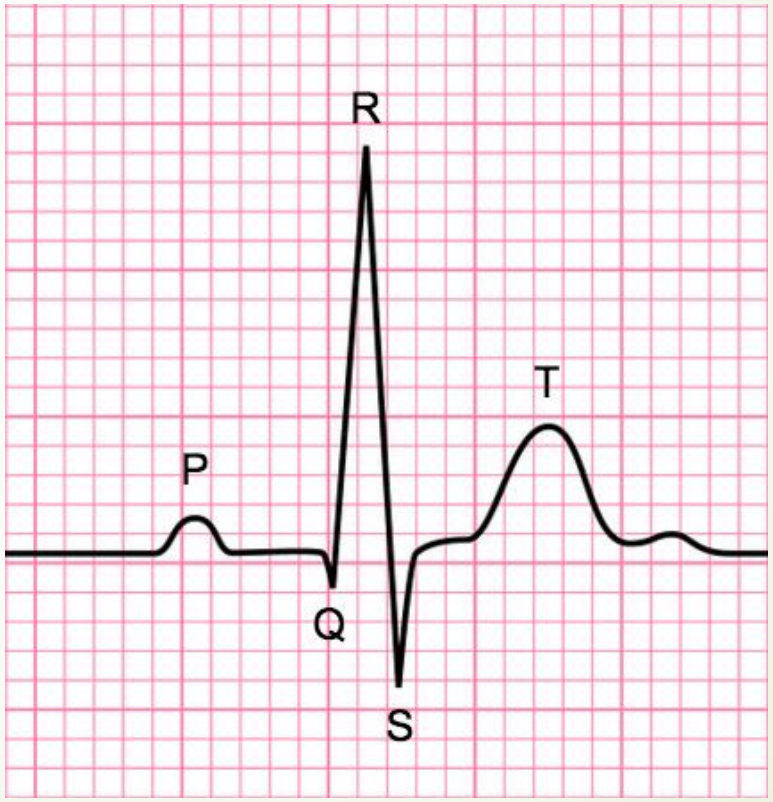

Equal P's and QRS

P = 7 QRS = 7

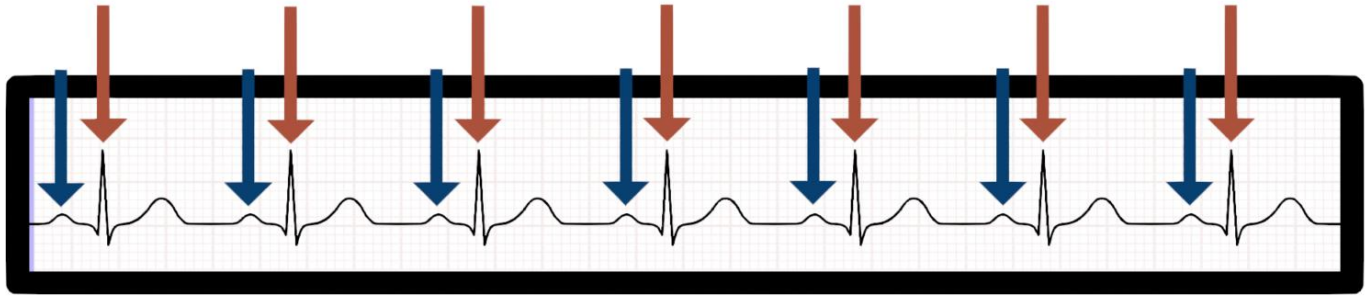

THE STEPS

- RATE
- RHYTHM
- P WAVES
- PR INTERVAL
- QRS
- ST SEGMENT
- T WAVE
- CONCLUSION

THE RATE

- 300 / BIG BOX
- 1500 / SMALL BOX
- 6 INCHES METHOD
- 10 INCHES METHOD

300 METHOD

- 300 / BIG BOX

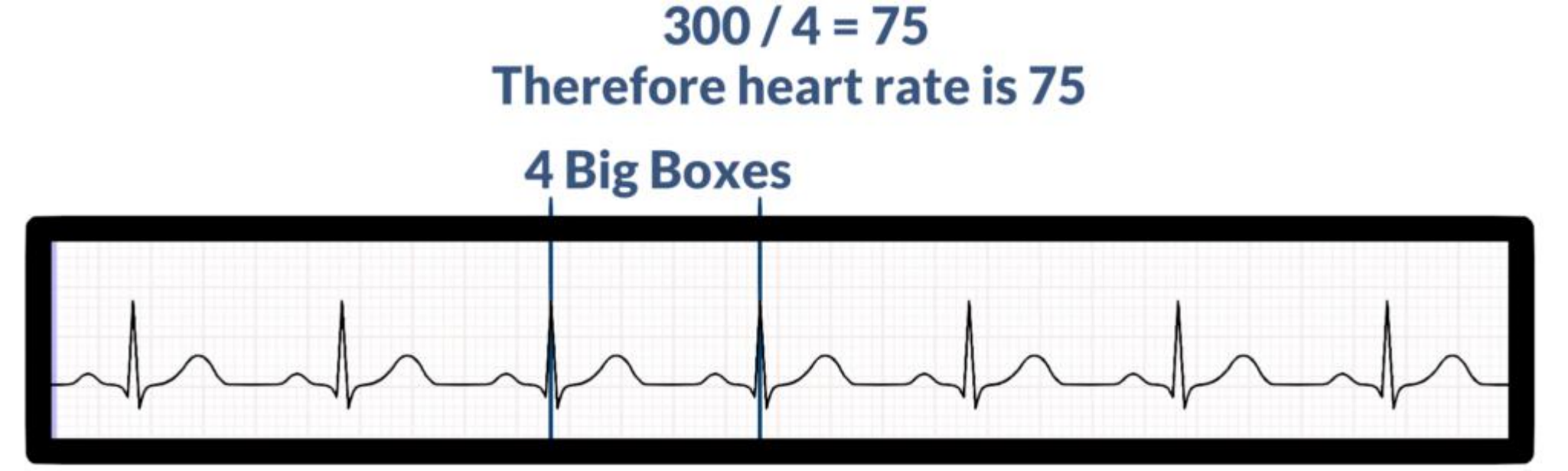

1500 METHOD

- 1500 / SMALL BOX

1500 / 20 = 75
Therefore heart rate is 75

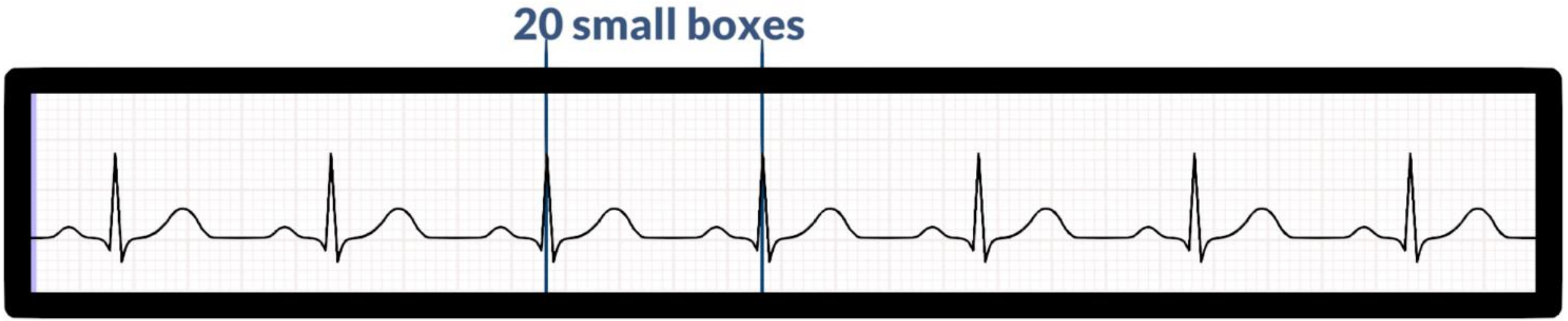

6 INCHES METHOD

- NORMALLY USE FOR IRREGULAR RHYTHM
- MULTIPLY BY 10

7 x 10 = 70

Therefore heart rate is 70



10 INCHES METHOD

- NORMALLY USE FOR IRREGULAR RHYTHM
- MULTIPLY BY 6



THE RYTHM

Regular Rhythm

Equal R-R Interval

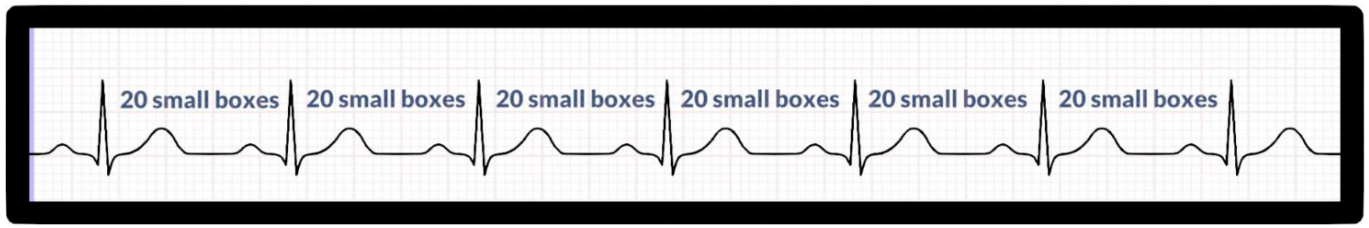

Irregular Rhythm

Unequal R-R Interval

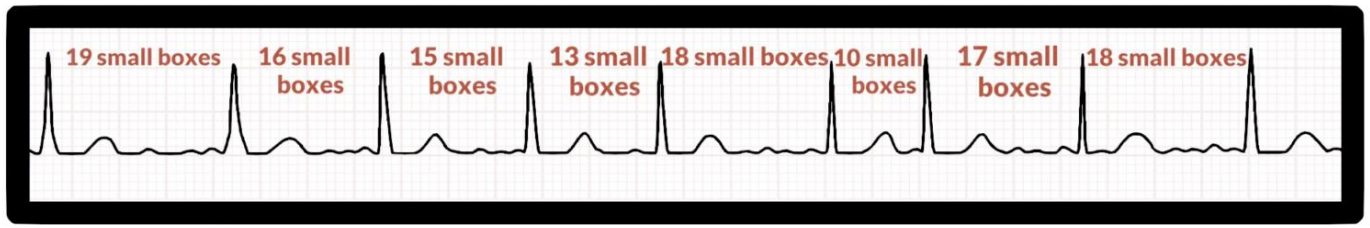

P WAVE

- The P wave on an ECG represents atrial depolarization, initiating atrial contraction, with a normal duration of <0.12
- It is typically smooth, rounded, and upright in leads II, III, and aVF, and biphasic in V1. Key findings include peaked P-waves (right atrial enlargement) or notched P-waves (left atrial enlargement).

Duration: <120ms (less than three small squares).
Morphology: Smooth, rounded, and upright in lead II.
Rhythm: One P wave should precede every QRS c

PAY ATTENTION TO:
1.Do all P waves deflect in the same direction?
2.Do all P waves have the same morphology (form)?

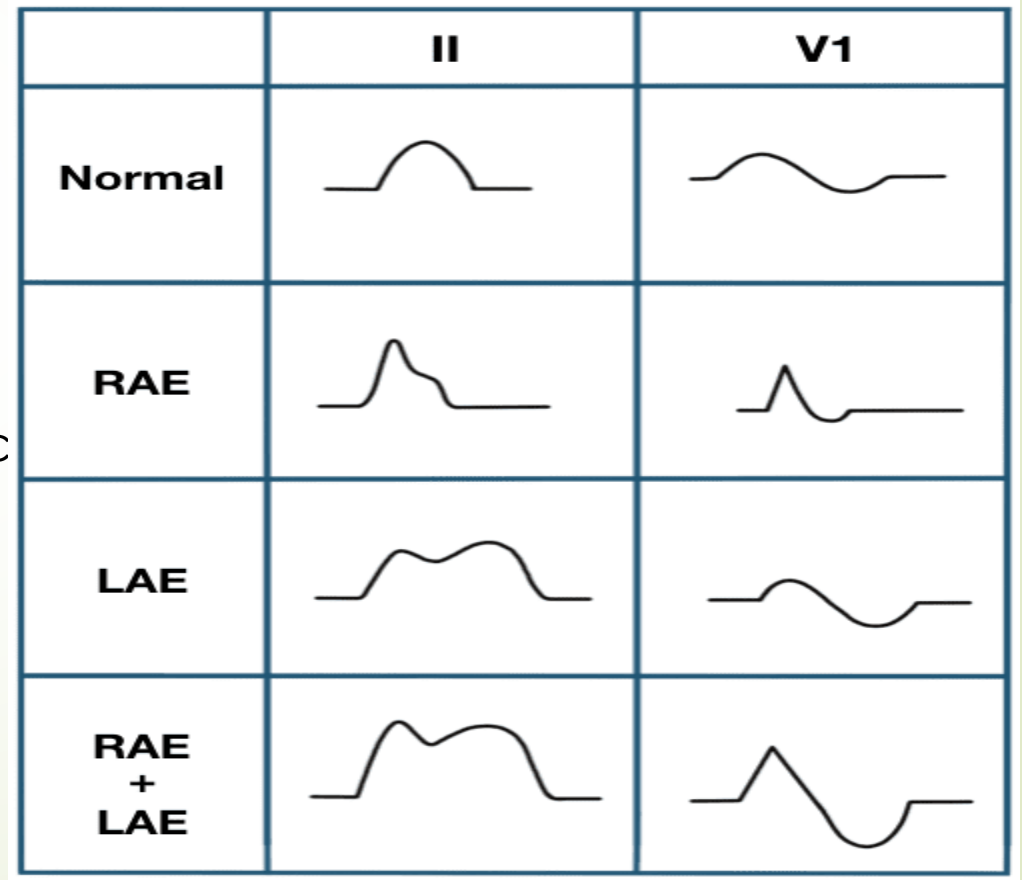

THE PR INTERVAL

Is the PRI within standard limits? (PRI standard limits are within 0.12 seconds to 0.20 seconds, or, 3 to 5 small boxes

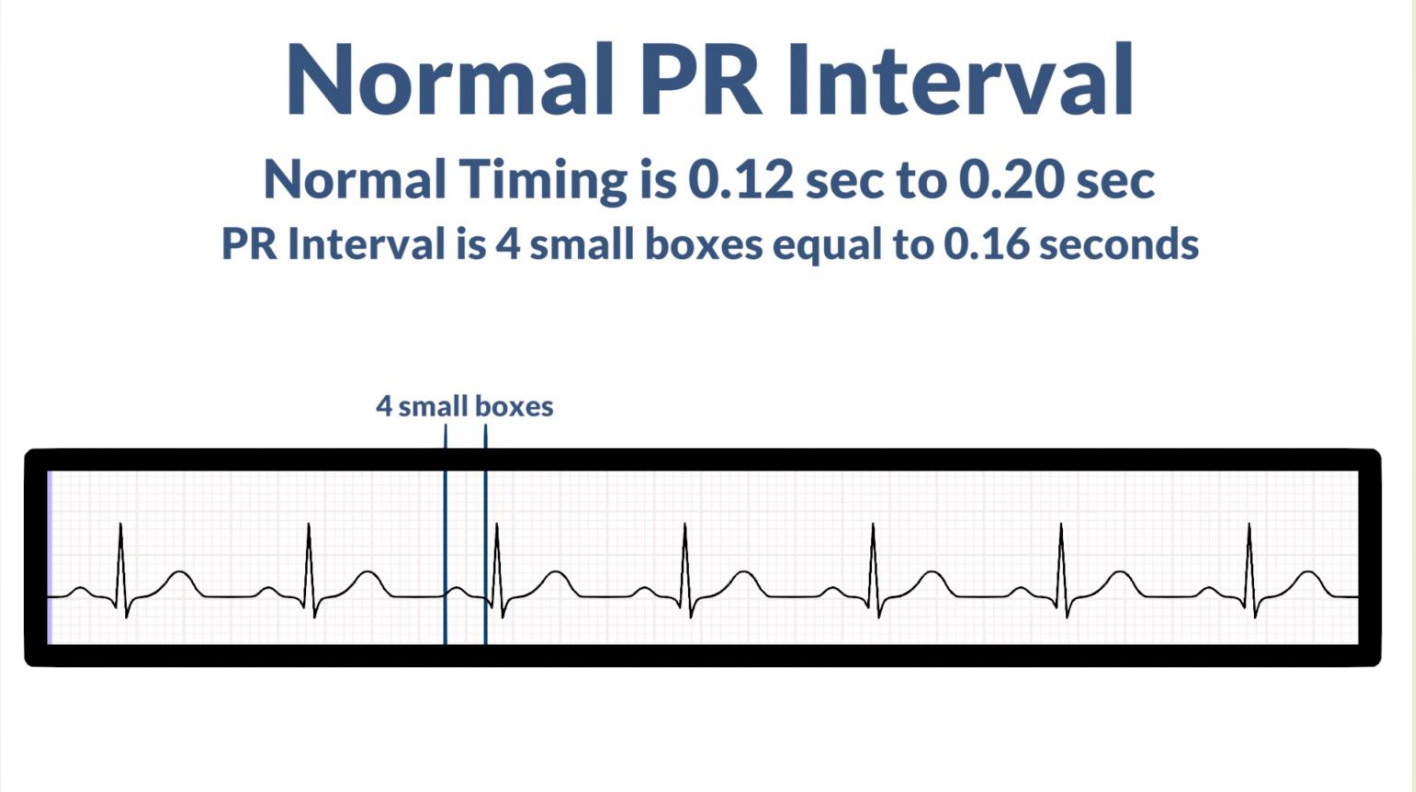

THE QRS

- Do all QRS complexes deflect in the same and expected direction?
- Do all QRS complexes have the same morphology (form)?
- Is the QRS complex within standard limits? (QRS complex standard limits are within 0.06 seconds to 0.12 seconds, or, 1.5 to 3 small boxes).

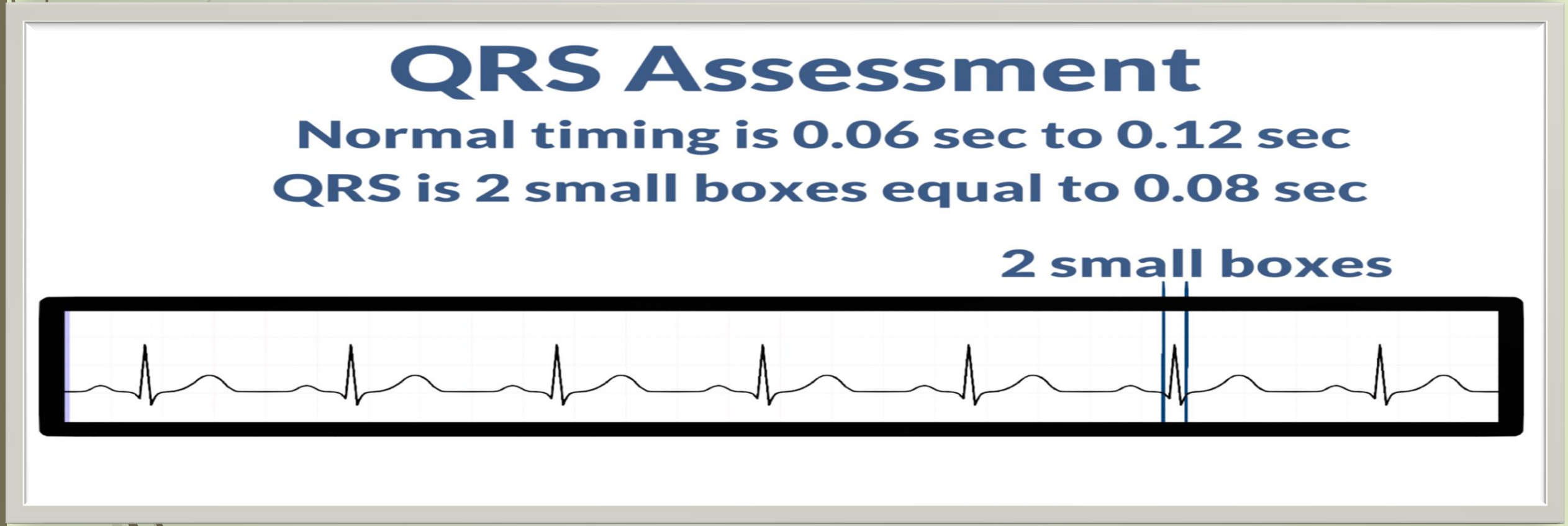

LEAD 1	LEAD AVF	AXIS
 POSITIVE	 POSITIVE	NORMAL
 POSITIVE	 NEGATIVE	LEFT AXIS DEVIATION
 NEGATIVE	 POSITIVE	RIGHT AXIS DEVIATION

"LEFT THUMB IS LEAD 1, RIGHT THUMB IS AVF.
THUMBS POINTS IN THE DIRECTION OF THR QRS

ST SEGMENT

Part of an ECG between the end of the QRS complex (S wave) and the start of the T wave, representing the period when the ventricles are fully depolarized and contracting. It is use to identify myocardial ischemia, infarction (heart attack), and other serious conditions.

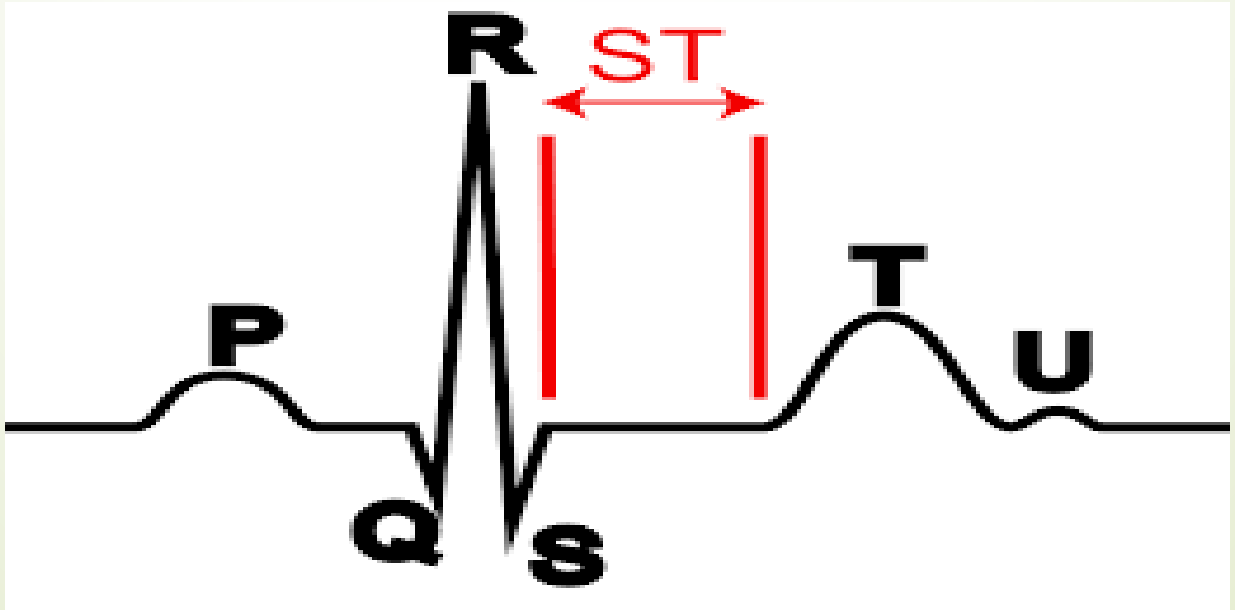

WHAT YOU SHOULD OBSERVE

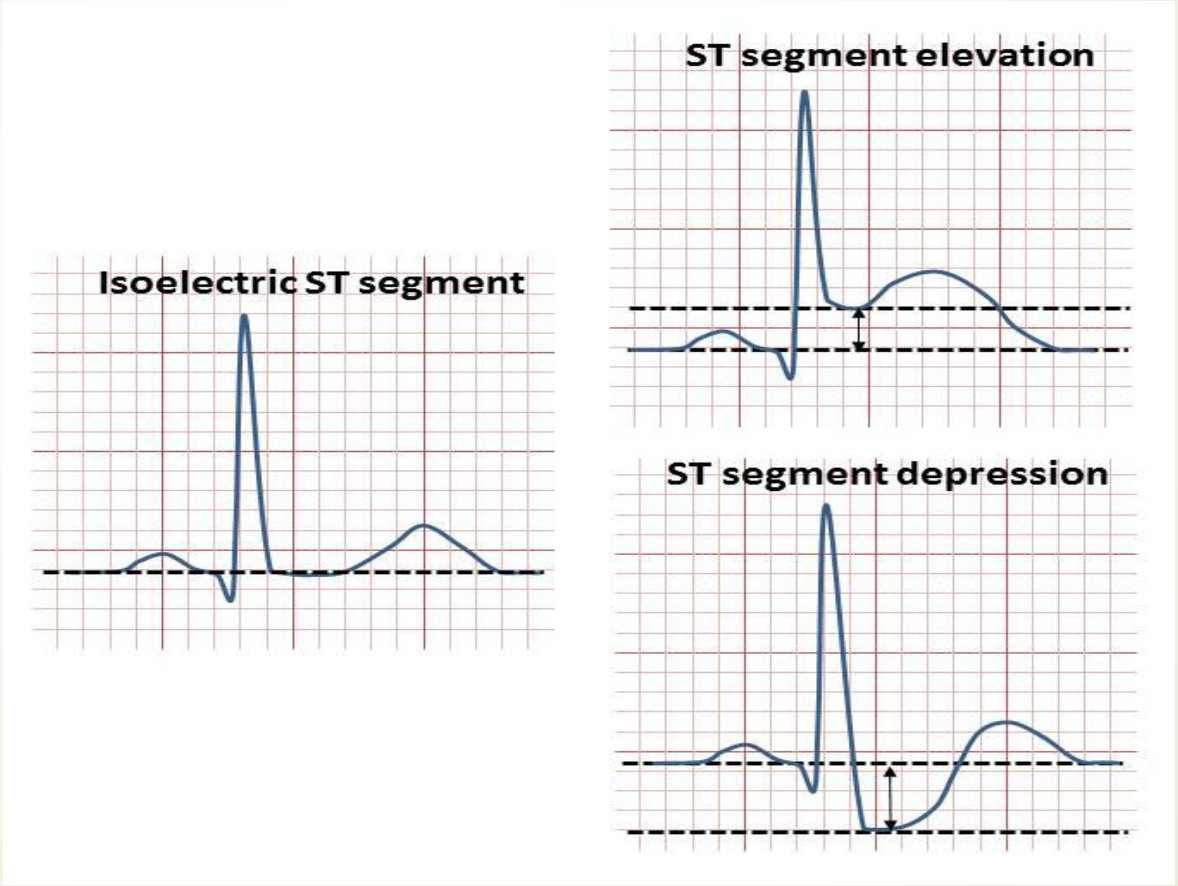

ST ELEVATION

signifies acute, transmural myocardial injury often caused by an occlusive thrombus in an artery. It is the hallmark of an ST-Elevation Myocardial Infarction (STEMI) (a medical emergency) when 1 mm elevation appears in two or more contiguous leads, or 1.5–2.5 mm in leads V2–V3 depending on age/sex.

- **General:** ST elevation at the J-point in 2+ contiguous leads Of 1 mm (0.1 mV) in limb leads.
- **V2–V3 Leads:** 2 mm in men age 40, 2.5 mm in men <40, or 1.5 mm in women.

Contiguous Leads & Locations:

- **Inferior (II, III, aVF):** Right Coronary Artery (RCA) or Left Circumflex (LCx).
- **Lateral (I, aVL, V5, V6):** Left Circumflex (LCx) or Left Anterior Descending (LAD).
- **Anterior/Septal (V1–V4):** Left Anterior Descending (LAD)

ST DEPRESSION

- occurs when the ST segment falls below the isoelectric baseline, often signaling subendocardial myocardial ischemia (lack of oxygen to the heart muscle).

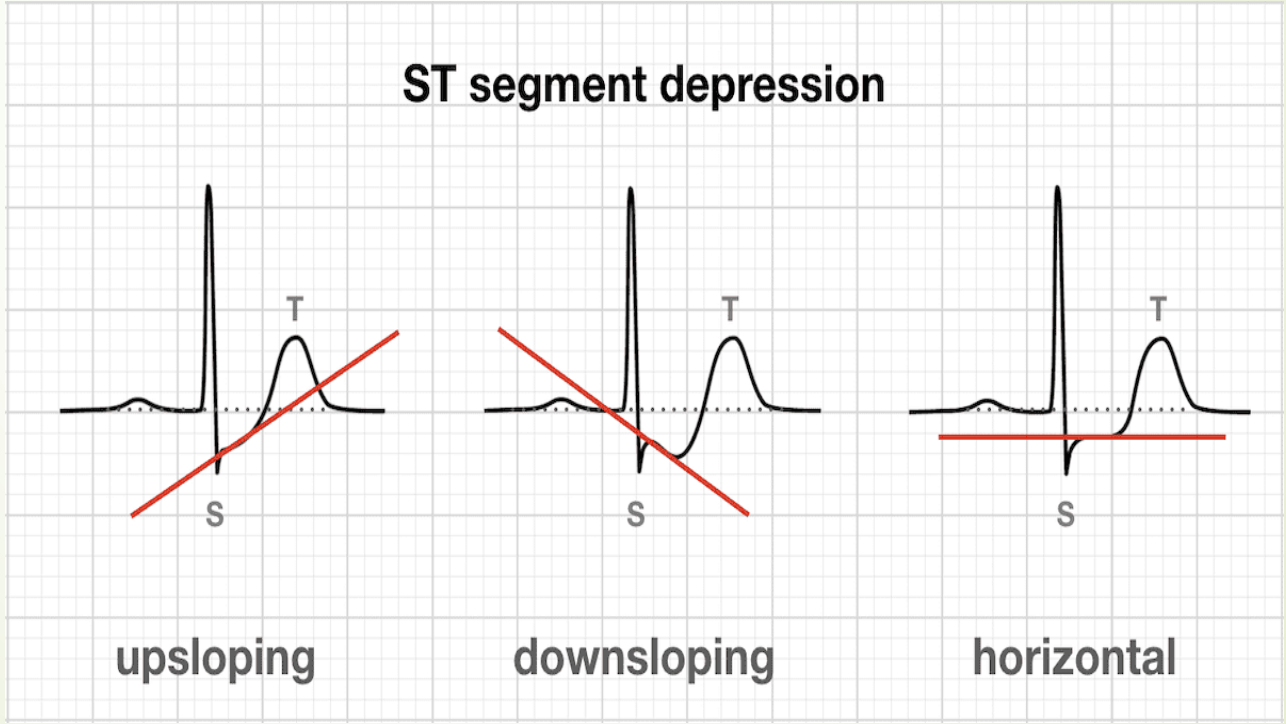

The junction (J-point) between the QRS complex and ST segment is displaced downward, typically >0.5 mm in two or more anatomically contiguous leads.

- **Ischemic Causes:** Most commonly indicates subendocardial ischemia, such as non-ST-elevation myocardial infarction (NSTEMI) or unstable angina.
- **Non-Ischemic Causes:**
  - **Medications:** Digoxin toxicity.
  - **Electrolyte Imbalance:** Hypokalemia.
  - **Structural Heart Disease:** Left Ventricular Hypertrophy (LVH).
  - **Conduction Abnormality:** Left Bundle Branch Block (LBBB).
  - **Tachycardia:** Rapid heart rates.
- **Morphology:**
  - **Horizontal or Downsloping:** Highly specific for ischemia.
  - **Upsloping:** Less specific for ischemia, can be seen in normal variants.

THE T WAVE

- represents **ventricular repolarization**, which is the process where the heart's ventricles relax and return to their resting electrical state (phase 3 of the cardiac action potential).
- **Normal Morphology:** Typically, the T wave is upright, slightly asymmetrical (slower upslope, faster downslope), and positive in most leads, particularly I, II, and V4-V6.
- **Clinical Significance of Abnormalities:**
  - **Inverted/Negative T waves:** Can indicate myocardial ischemia, infarction, or ventricular strain.
  - **Peaked/Tall T waves:** Often indicate hyperkalemia.
  - **Flat/Flattened T waves:** Often indicate hypokalemia.

- WHAT SHOULD YOU SEE

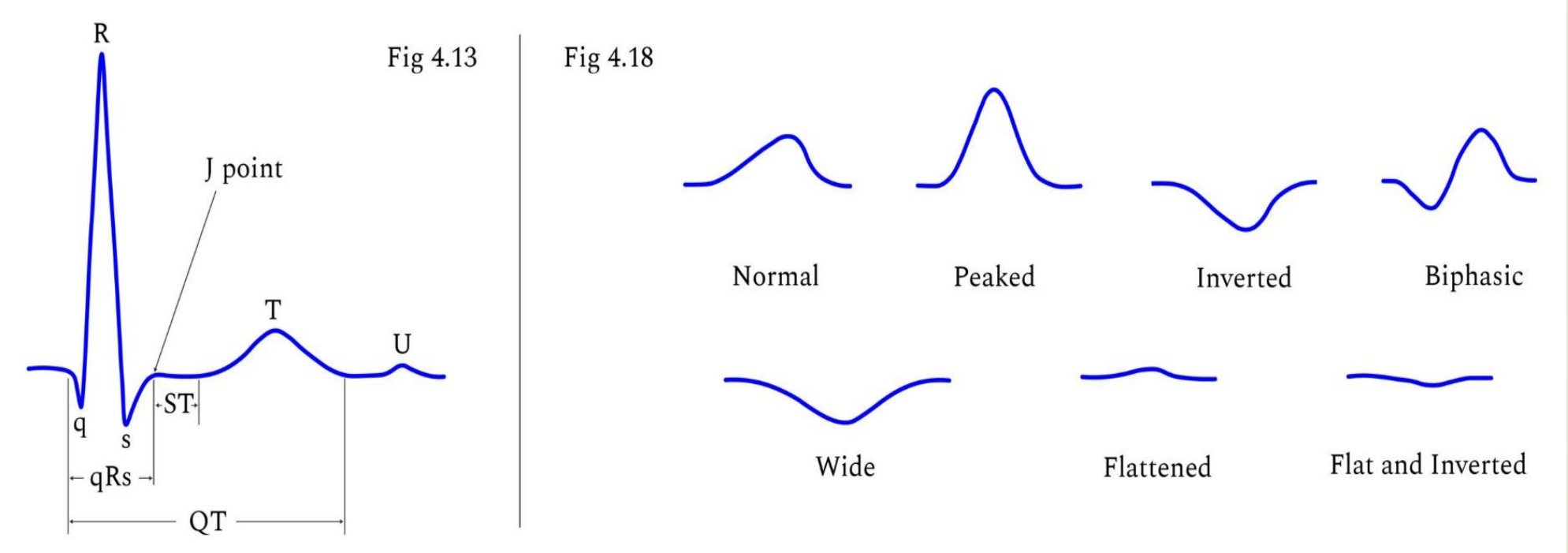

QT INTERVAL

- The QT interval on an electrocardiogram (ECG) measures the time from the start of the QRS complex to the end of the T-wave, representing ventricular depolarization and repolarization (contraction and relaxation).

A normal QT interval is typically 0.35–0.44 seconds, with prolonged intervals (>450ms in men, >460ms in women) increasing the risk of Torsades de Pointes and sudden cardiac death.

HOW TO MEASURE QT INTERVAL

- **Measurement:** It is measured from the beginning of the QRS complex to the end of the T-wave.
- **Heart Rate Dependency:**
- The interval varies with heart rate, necessitating the use of the **corrected QT interval (QTc)** (usually via Bazett's formula) to standardize measurements to a heart rate of 60 bpm

Normal Limits: Generally, a QTc than 440ms is considered normal. QTc is usually slightly longer in females.

Measuring the QTc

A prolonged QT interval may lead to some dangerous arrhythmias.
It varies due to heart rate and thus is 'normalized' to a person's heart rate.
Let's calculate some corrected QT intervals (QTc).
Step 1. Measure the QT in seconds
Step 2. Measure the R to R interval (RR or R-R) in seconds
Step 3. Get the Square root of the RR interval
Step 4. Divide the QT (sec) by the square root of the RR
A normal QTc is <0.46 sec in women and <0.45 sec in men.
A QTc >0.50 is dangerously prolonged.

RR: 24.5 x .04 = .98 sec

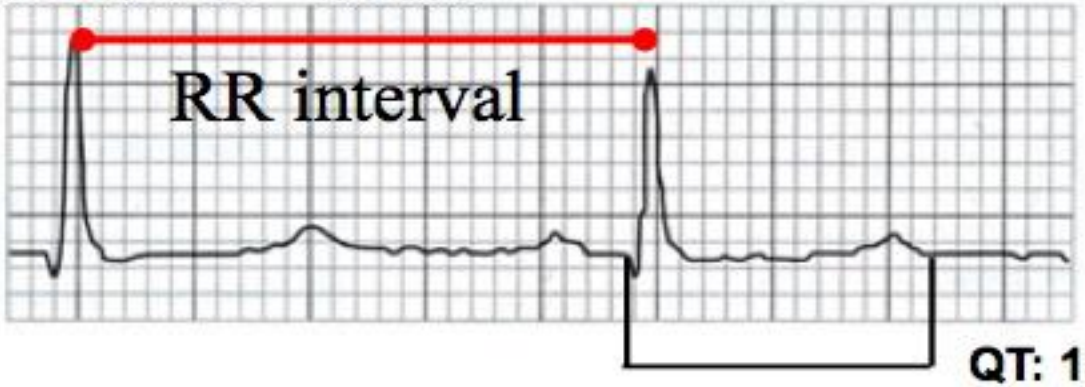

QT: 13 x .04 = .52 sec

$$QTc = \frac{QT}{\sqrt{RR}} = \frac{.52}{\sqrt{.98}} = \frac{.52}{.989} = .525 \text{ or } .53 \text{ sec}$$

EXAMPLE

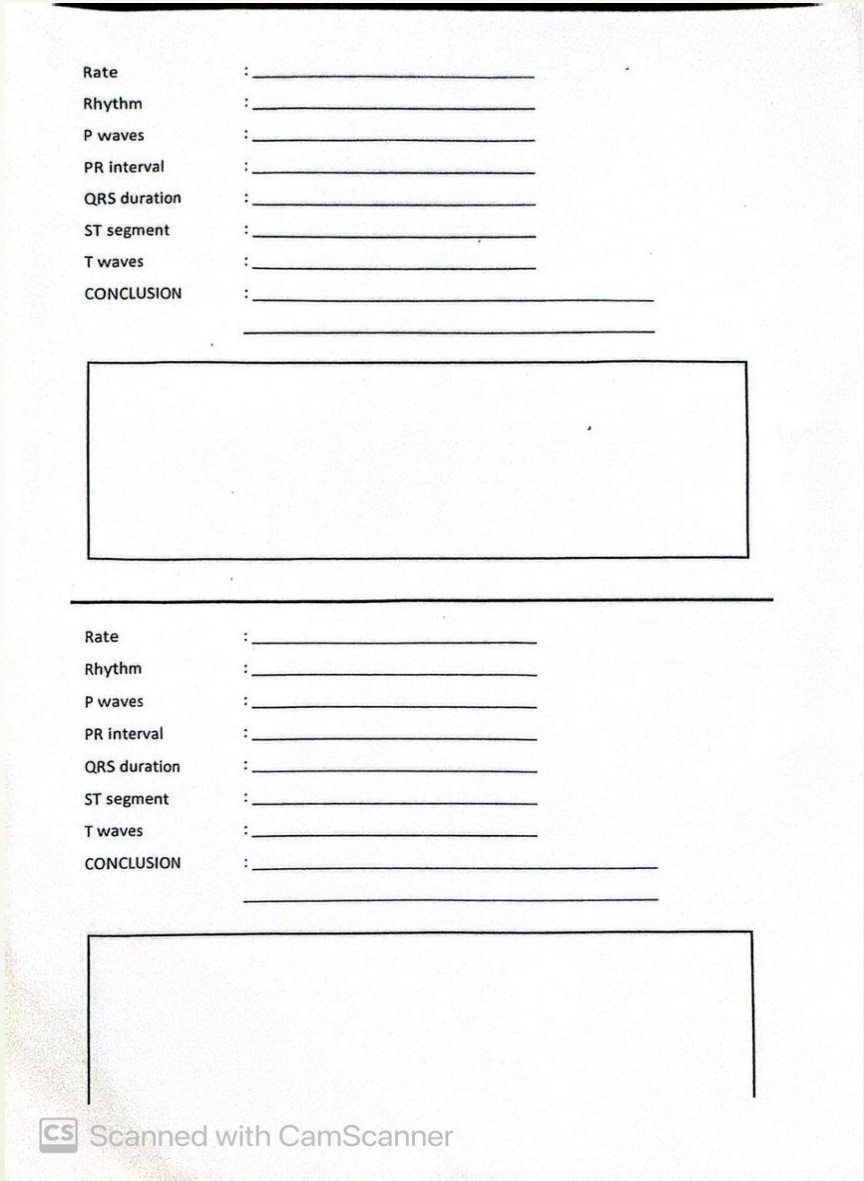

Rate :
Rhythm :
P waves :
PR interval :
QRS duration :
ST segment :
T waves :
CONCLUSION :

Rate :
Rhythm :
P waves :
PR interval :
QRS duration :
ST segment :
T waves :
CONCLUSION :

Scanned with CamScanner

DATE:

1) Rate

i) method 1

$\frac{300}{3.2 \text{ big squares}} = 94$ bpm

ii) method 2

$\frac{1500}{16 \text{ small squares}} = 94$ bpm

iii) method 3

HR x 10 wave in 6 inch strip (6s)

$-9 \times 10 = 90$ bpm

2) Rhythm

-Rhythm is regular

3) P wave

-P wave is present, rounded and smooth.

-Width: 2 small squares x 0.04 sec = 0.08 sec

-Height: a) 1 small squares x 0.1mv = 0.1mv

b) 1 small square x 1mm = 1mm

∴ P wave is normal (normal range 0.04 sec - 0.12 sec)

-P wave is present upright in leads :- I, II, III, aVL, aVF, V_1, V_2, V_3, V_4, V_5, V_6

-P wave is present inverted in leads :- aVR

4) PR interval

-3.5 small squares x 0.04 sec = 0.14 sec

∴ PR interval is normal (normal range 0.12 - 0.20 sec)

5) QRS complex

-QRS complex is narrow

-Width: 2 small squares x 0.04 sec = 0.08 sec

-Height: a) 2 small squares x 0.1mv = 0.2 mv

b) 2 small squares x 1mm = 2mm

∴ QRS complex is normal (normal range 0.06 - 0.12 sec)

-QRS complex present positive deflection in leads :- I, II, aVL, aVF, V_1, V_2, V_3, V_4, V_5, V_6

-QRS complex present negative deflection in leads :- III, aVR, II, V_2

-Q wave is present pathological in leads :- III, aVF which is Q wave is more than 25% from R wave.

6) ST segment

-ST segment is elevated in leads : Lead II (2 small box), III (3 small box), aVF (2 small box)

∴ There is acute inferior myocardial infarction.

-ST segment is isoelectric line in leads :- aVR, V_4, V_5, V_6, V_1

-ST segment depression in leads :- V_2, V_3, I, aVL

7) P-QRS complex relationship

-P wave follow by QRS complex with 1:1 relationship

8) T wave

-T wave is present, inverted.

-Width : 3 small squares x 0.04 sec = 0.12 sec

-Height : a) 1.5 small squares x 0.1mv = 0.15 mv

b) 1.5 small squares x 1mm = 1.5mm

∴ T wave is normal (normal range 0.08 - 0.12 sec)

-T wave is present upright in leads :- I, aVL, V_2, V_3, V_5, V_6

-T wave is present inverted in leads :- II, III, aVF, V_1, V_4

-T wave is isoelectric line in leads :- aVR

9) QT interval

$QTC = \frac{QT \text{ (sec)}}{\sqrt{RR \text{ interval}}}$

$QTC = \frac{9 \text{ small squares} \times 0.04 \text{ sec}}{\sqrt{16 \text{ small squares} \times 0.04 \text{ sec}}}$

$QTC = \frac{0.36 \text{ sec}}{\sqrt{0.64 \text{ sec}}}$

$QTC = \frac{0.36 \text{ sec}}{0.80 \text{ sec}}$

$QTC = 0.45$ sec

∴ QT interval is normal (normal range 0.35 sec - 0.45 sec)

10) Axis

i) Lead I = Positive deflection

Lead aVF = Negative deflection

∴ Left axis deviation

ii) Lead I = 7mm

Lead aVF = -5 + 4 = -1 mm

$\angle = -9°$

11) conclusion

- Acute inferior myocardial infarction
- Probable posterior myocardial infarction
- High lateral myocardial ischemia
- ~~Left axis deviation~~ Normal axis
- Sinus rhythm.

Friday

SECASO

SELANGOR CARDIAC SONOGRAPHER SOCIETY


Thank you!