SALFORD & CO.

# ECG PLACEMENT

Basic ECG COURSE 2026

Presented by:
PPP MUHAMMAD AMIRUL NASRALLAH BIN NASRUN



SALFORD & CO.

# WHAT IS ECG CAN IDENTIFY??



SALFORD & CO.

# MYOCARDIUM INFARCTION

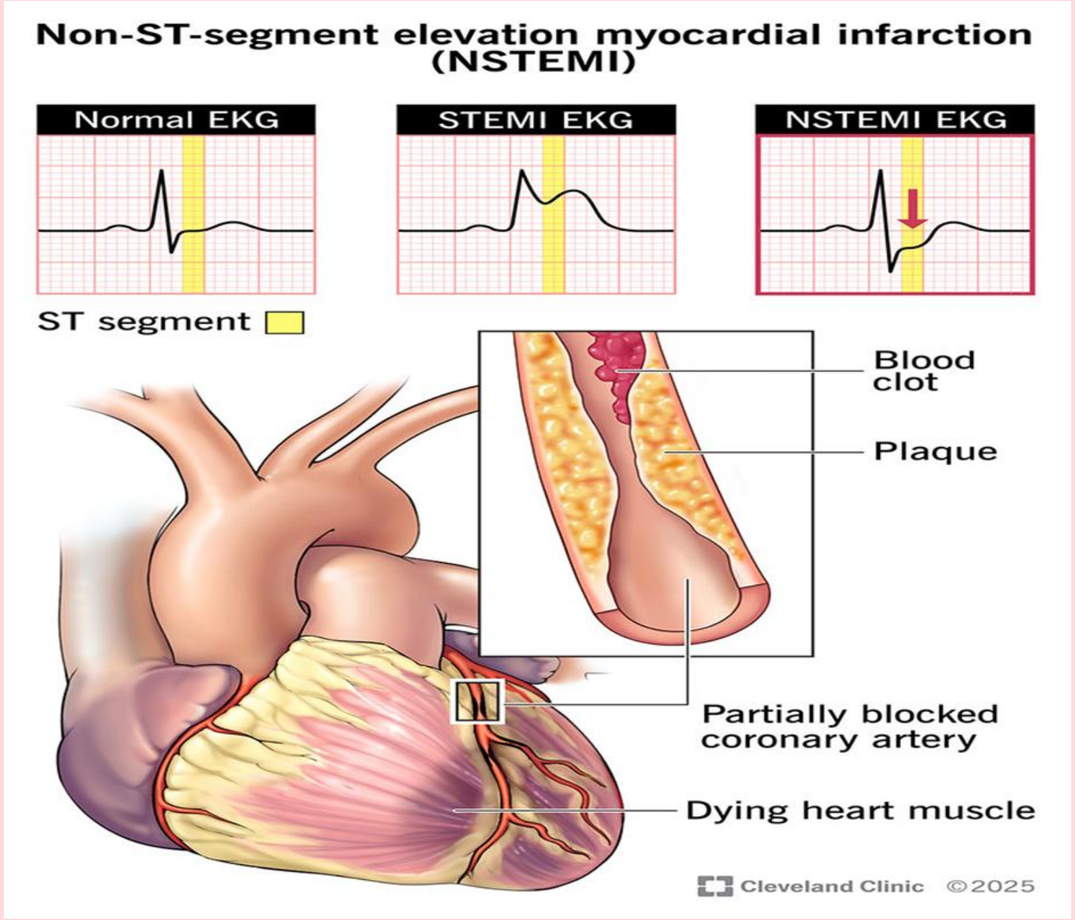




# Arrhythmia

## Tachycardia

- Atrial Fibrillation
- Atrial Flutter
- Supraventricular Tachycardia

## Bradycardia

- Sinus node dysfunction
- Heart block

# Electrolyte imbalance

**Occurs when certain mineral levels in your blood get too high or too low**

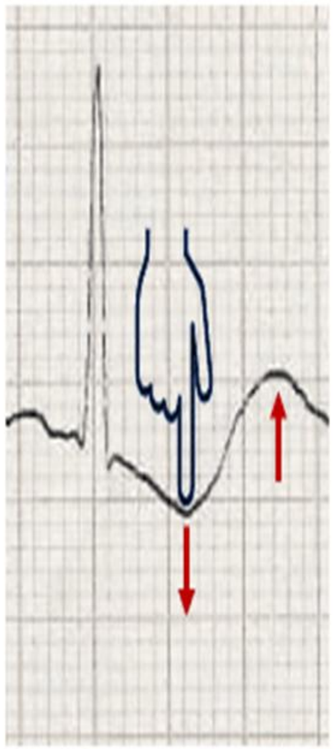

## Hypokalaemia

T wave inversion
ST depression
Prominent U wave

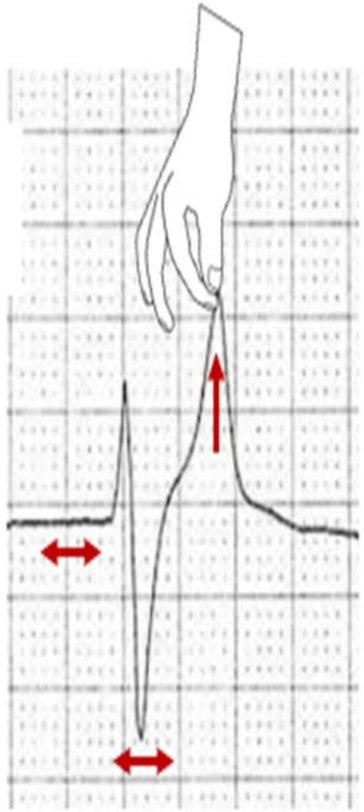

## Hyperkalaemia

Peaked T waves
P wave flattening
PR prolongation
Wide QRS complex

LIFE IN THE FASTLANE

# ECG LEADS

- **The standard ECG has 12 leads**

3 standard Limb Leads

3 Augmented Limb Leads

6 Precordial Leads



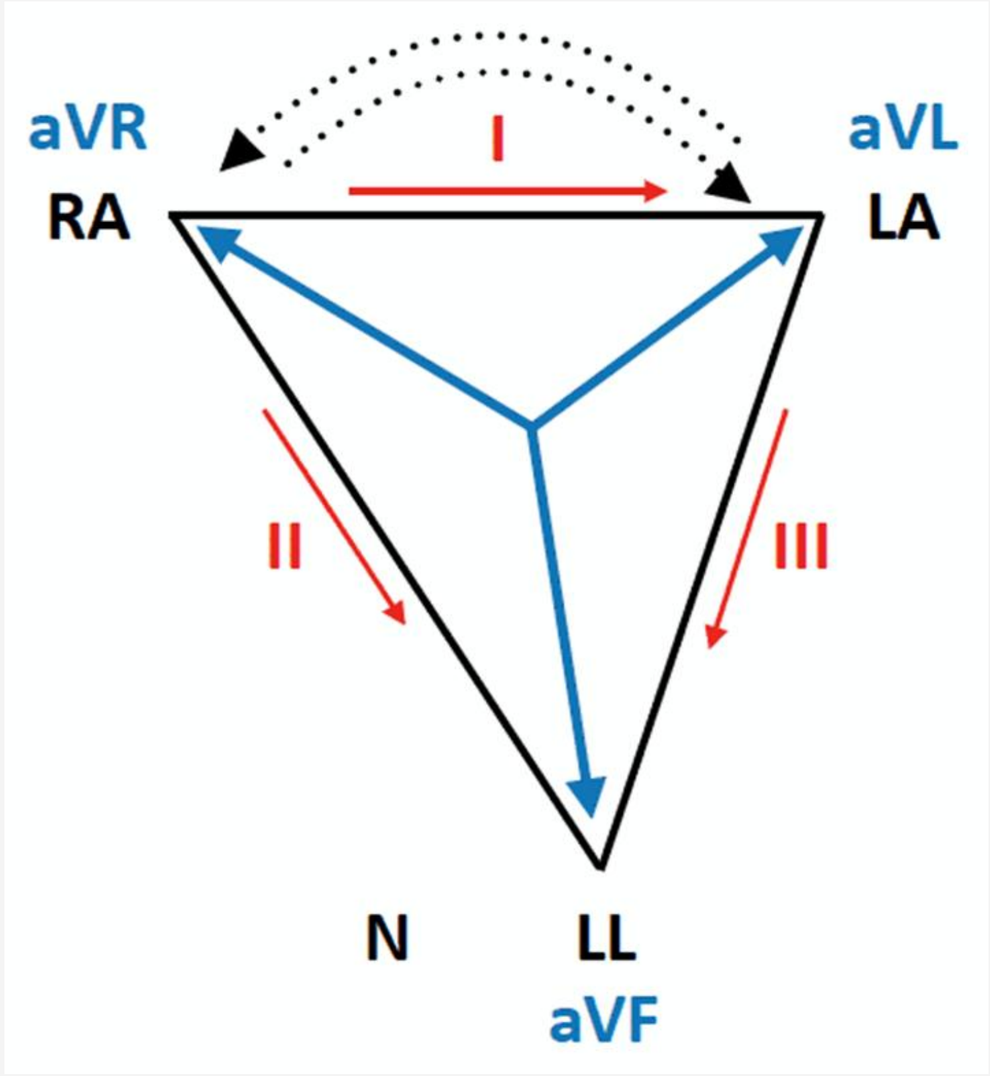

# Standard ECG Placement

| Precordial Lead Placement | |
|---|---|
| V1 | 4th intercostal space, right sternal margin |
| V2 | 4th intercostal space, left sternal margin |
| V3 | Midway between V2 & V4 |
| V4 | 5th intercostal space, left mid-clavicular line |
| V5 | 5th intercostal space, left anterior axillary line |
| V6 | 5th intercostal space, left mid-axillary line |

| Limb Lead Placement | |
|---|---|
| RA | Right arm or shoulder |
| LA | Left arm or shoulder |
| RL | Right leg or lower right abdomen |
| LL | Left leg or lower left abdomen |

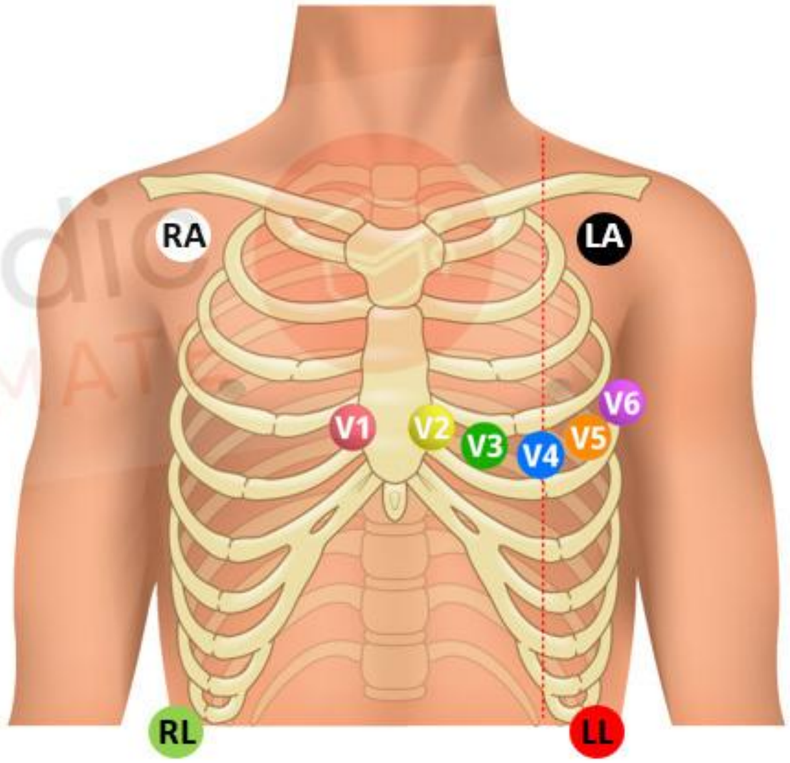

# Ecg Placement

- 12-lead ECG
- 10 electrodes required to produce 12-lead ECG
  - 4 Electrodes on all 4 limbs (RA, LL, LA, RL)6 Electrodes on precordium (V1–6)
- 12-lead Precordial lead placement
  - V1: 4th intercostal space (ICS), RIGHT margin of the sternum
  - V2: 4th ICS along the LEFT margin of the sternum
  - V4: 5th ICS, mid-clavicular line
  - V3: midway between V2 and V4
  - V5: 5th ICS, anterior axillary line (same level as V4)
  - V6: 5th ICS, mid-axillary line (same level as V4)

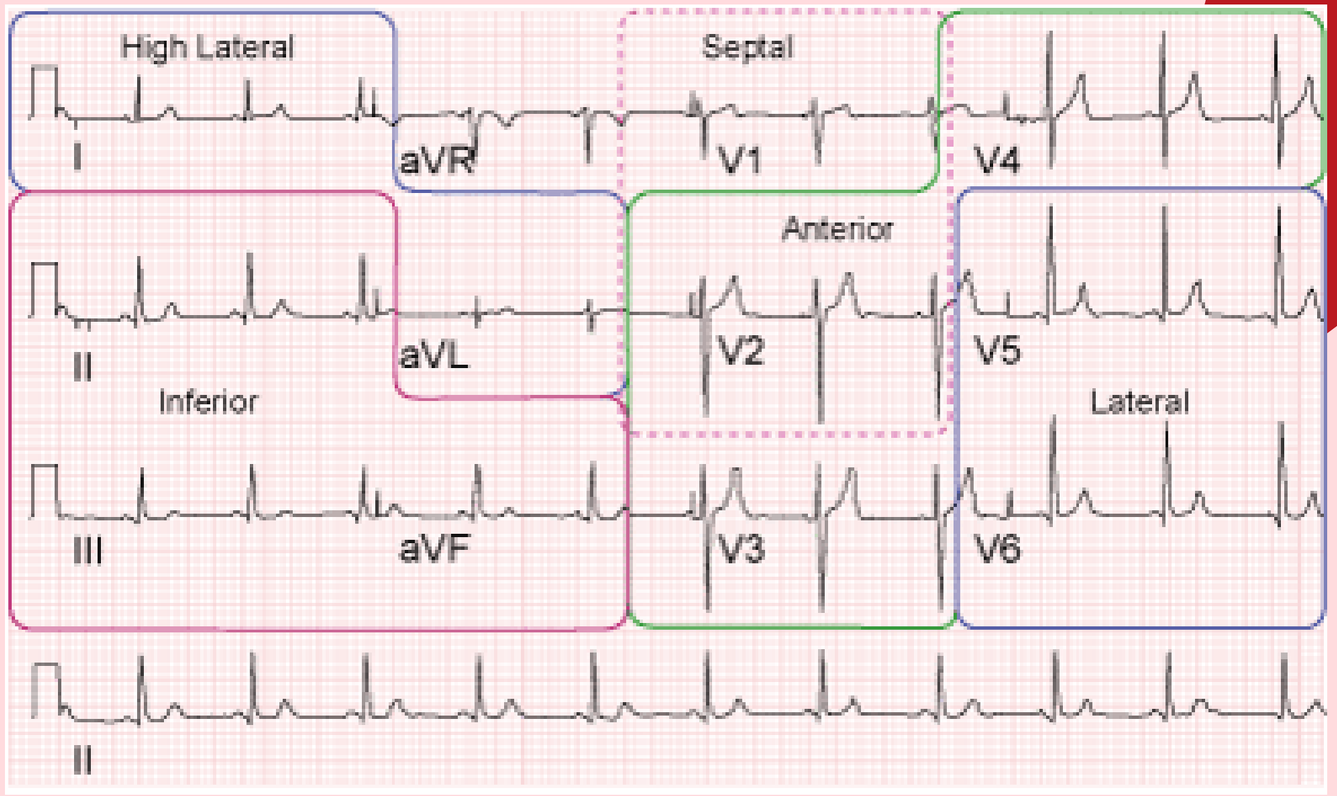

# Right Sided ECG

**A right-sided ECG is typically done when you suspect right ventricular involvement, most commonly in cases of right ventricular myocardial infarction (RVMI), which often occurs with inferior MI.**

## Indication of right sided ECG

- Inferior STEMI ( ST elevation in lead II,III and aVF
- Dextrocardia



SALFORD & CO.

# RIGHT SIDED CHEST LEAD PLACEMENT

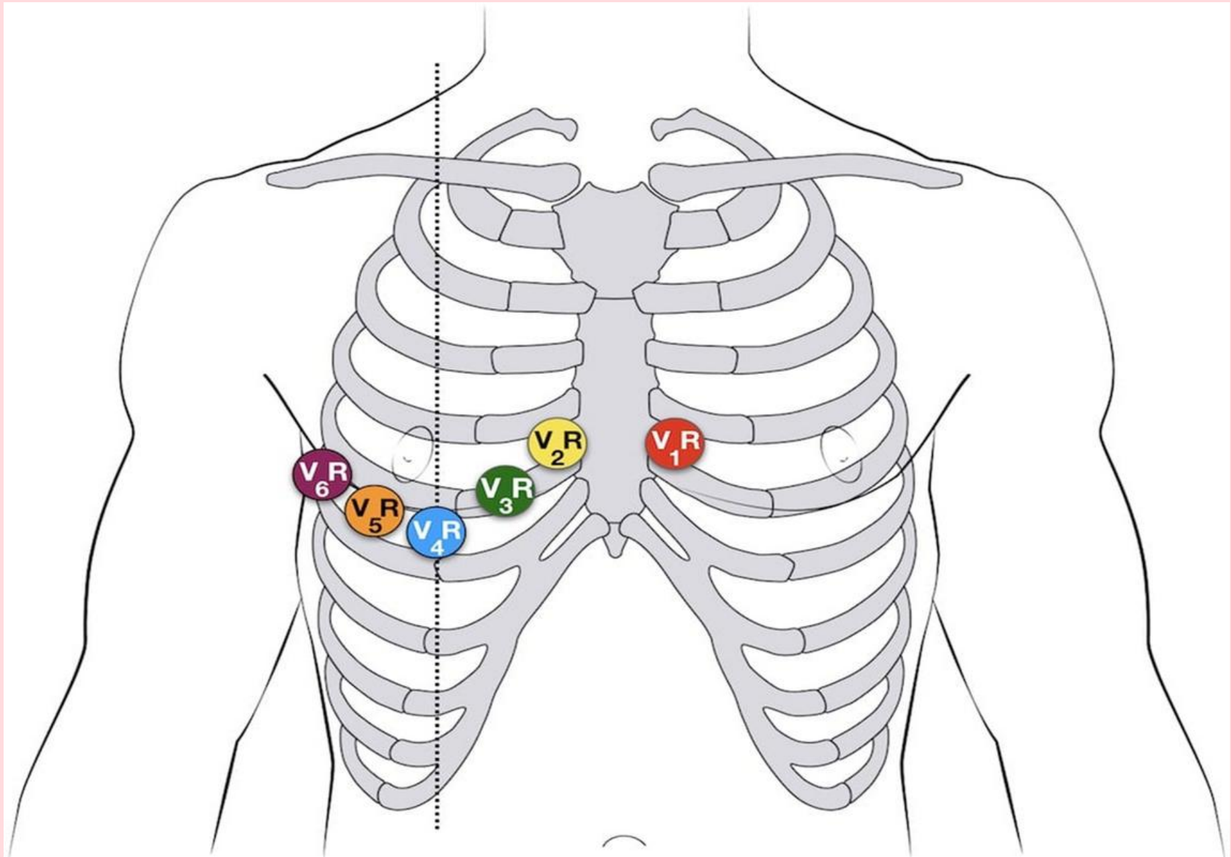

# Case sharing

## Demographic

- 60 Y/male
- Referred from GP
- Chronic Smoker
- Chest pain for 3 Hrs radiating to left arm & jaw.
- a/w diaphoresis, nausea
- Pain Score: 8/10

### Clinical Examination

- Alert, Concious
- B/P : 96/50mmHG
- HR : 106 bpm
- Lung : Clear, Equal A/e

# Example 1a

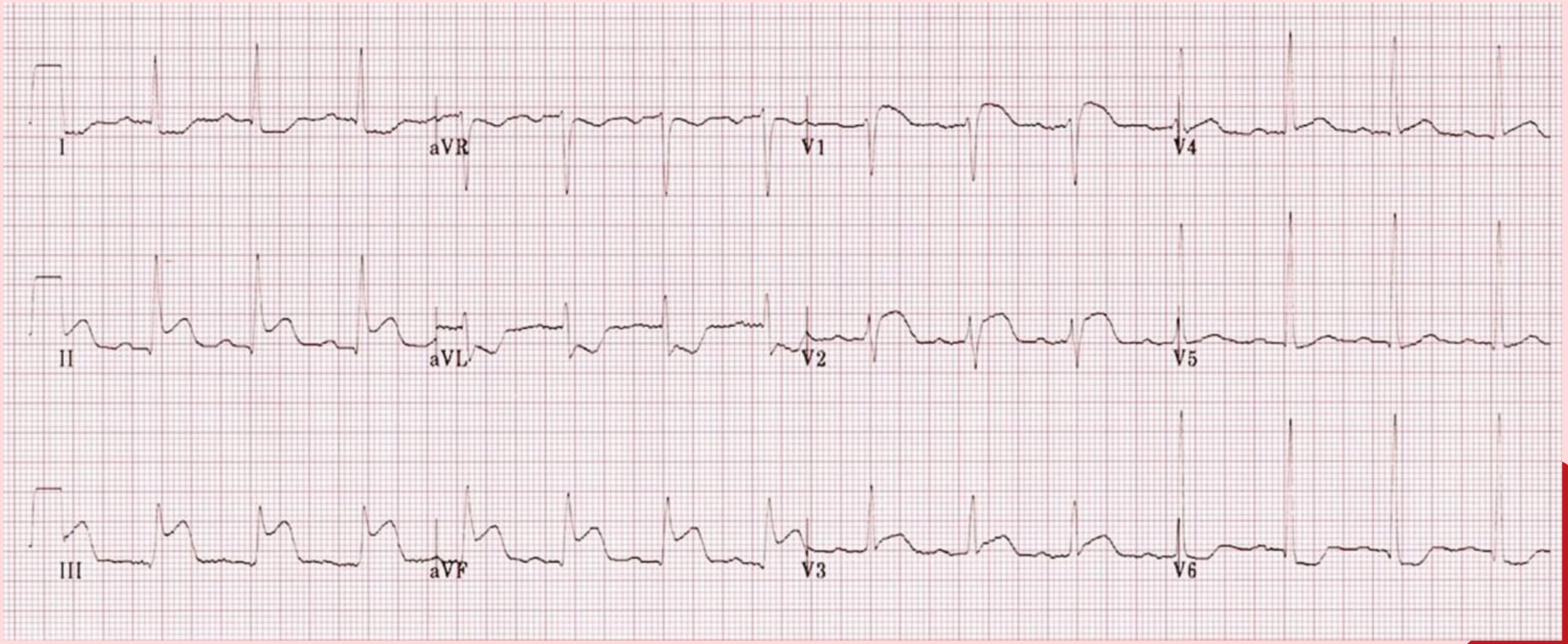

# Example 1b

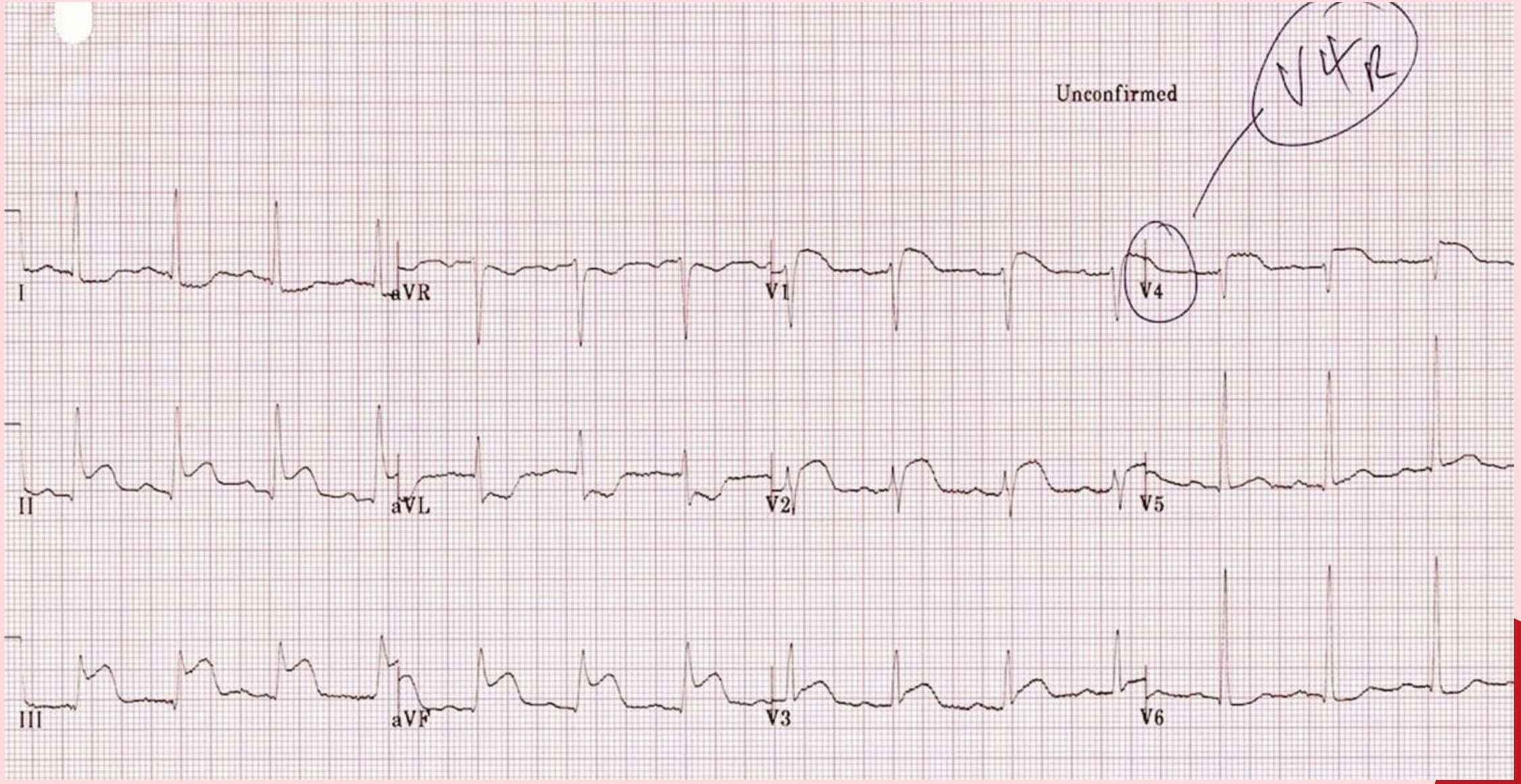

# Coronary angiography

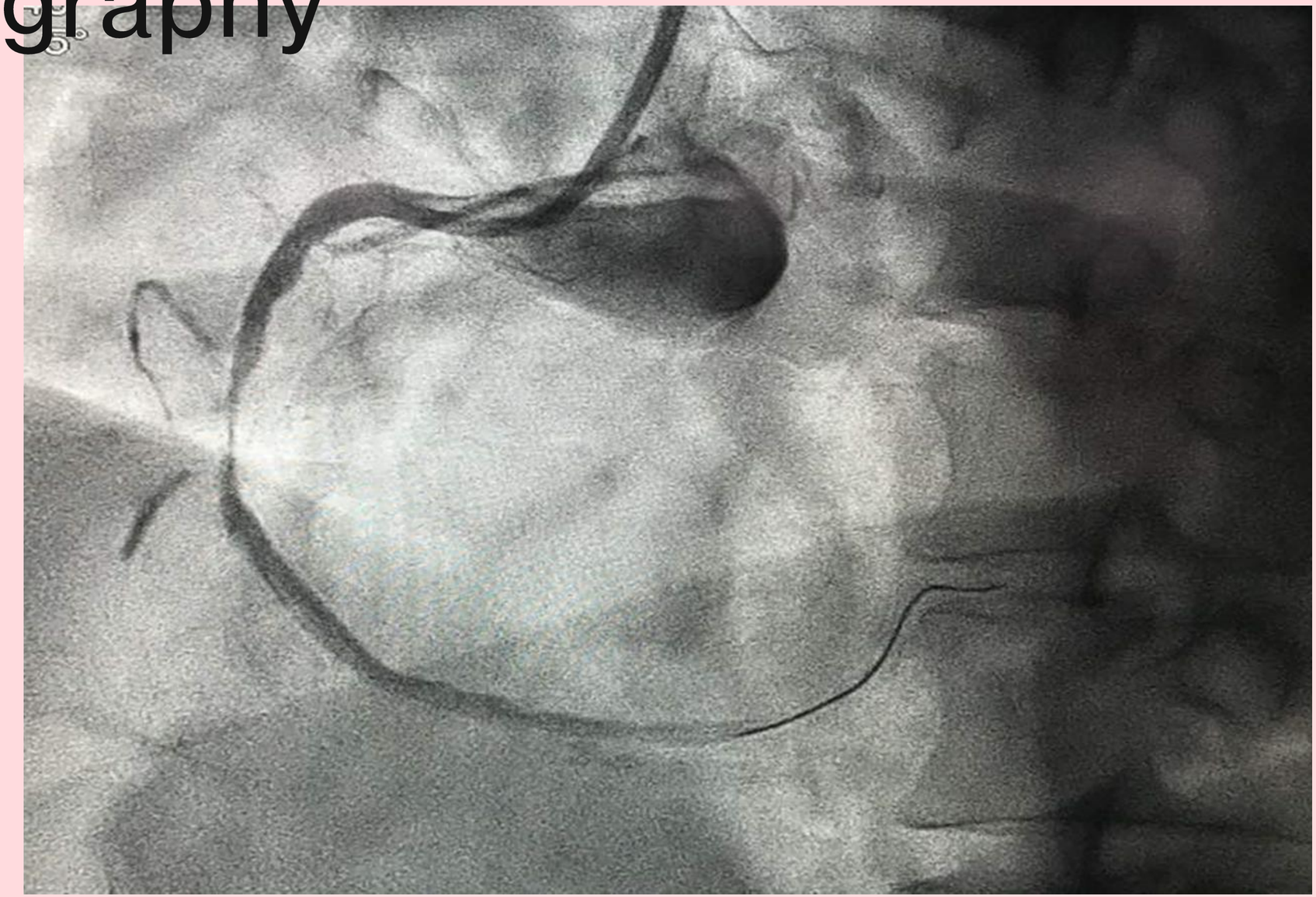

# Pci done to RCA

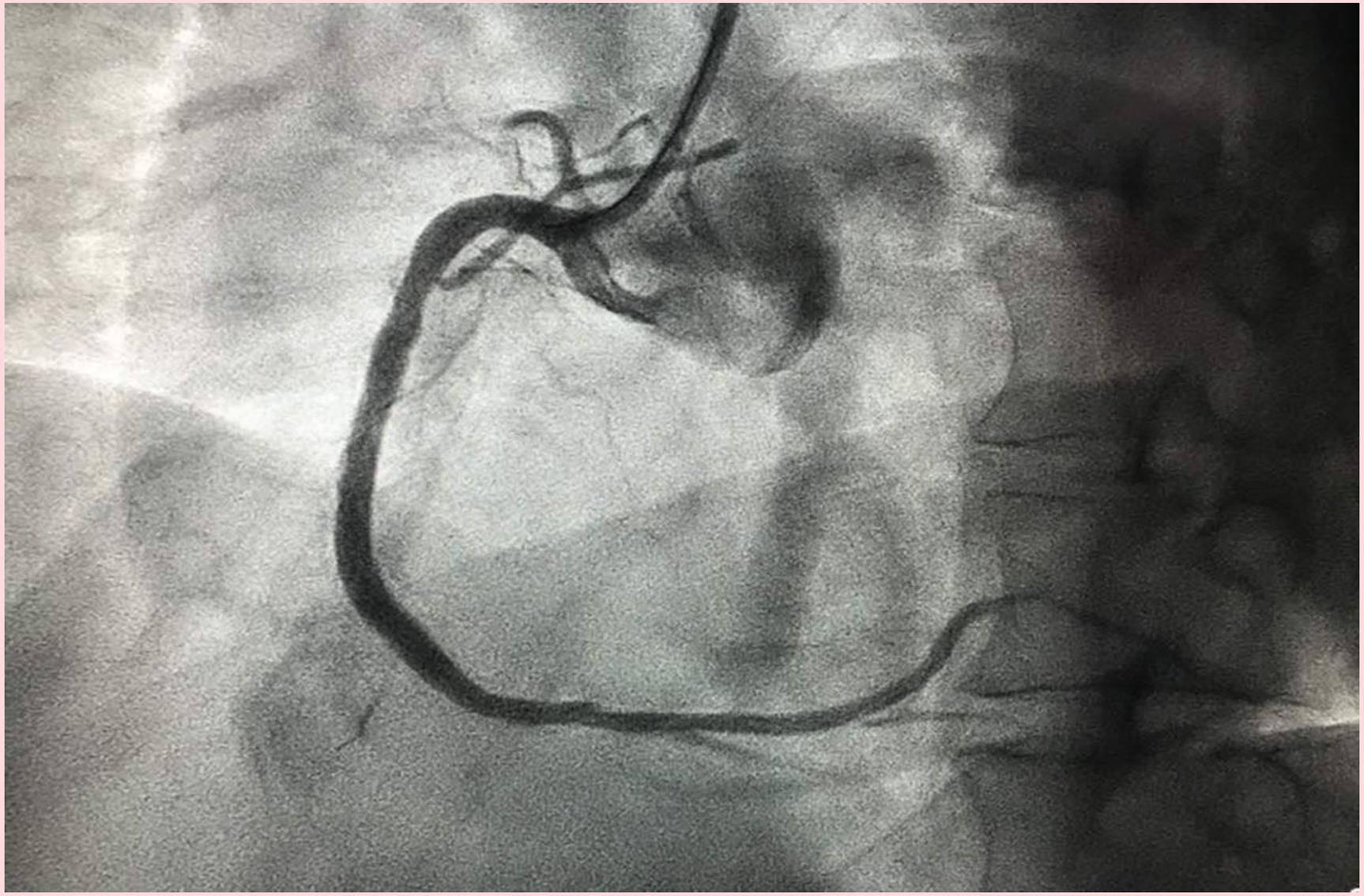

# Dextrocardia

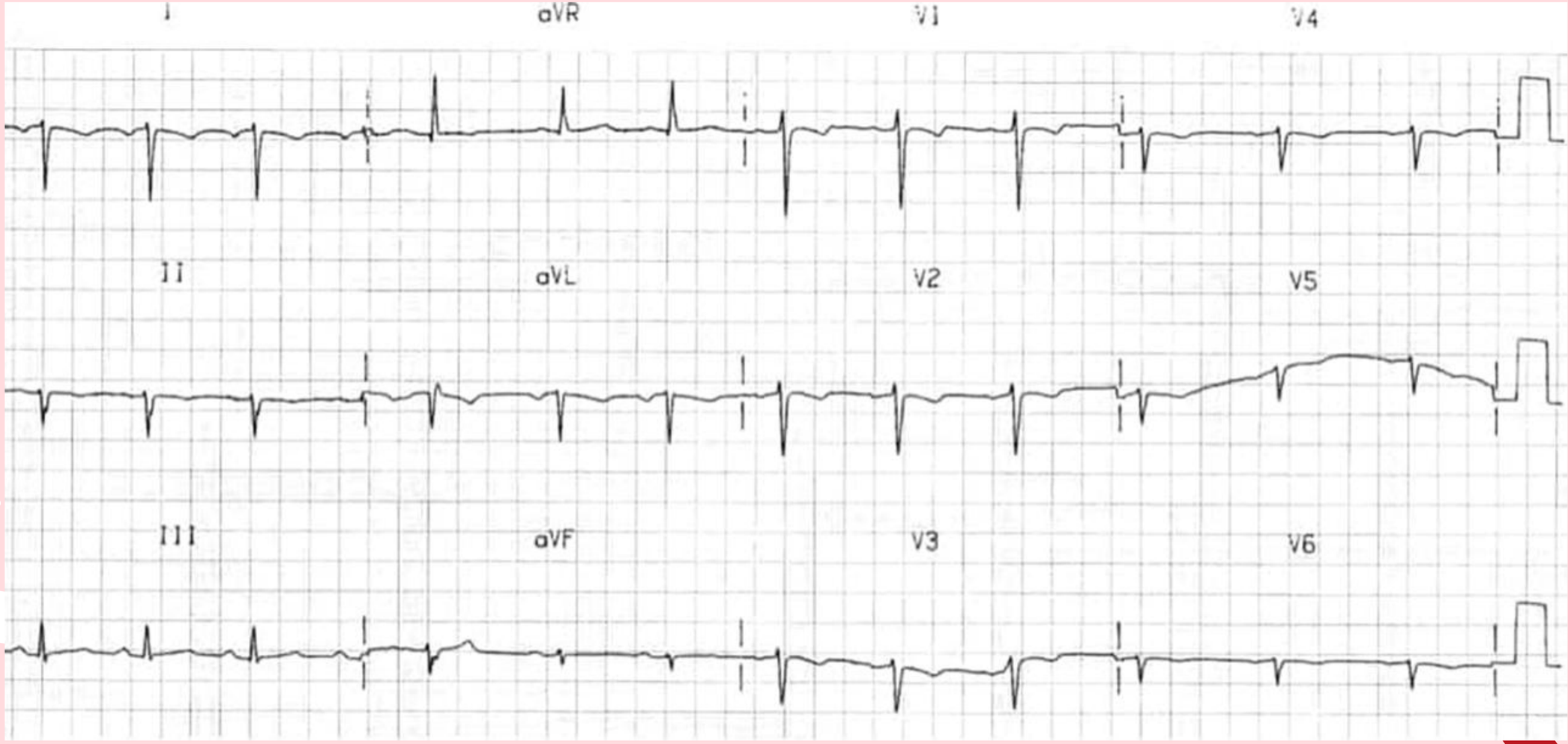

# Dextrocardia

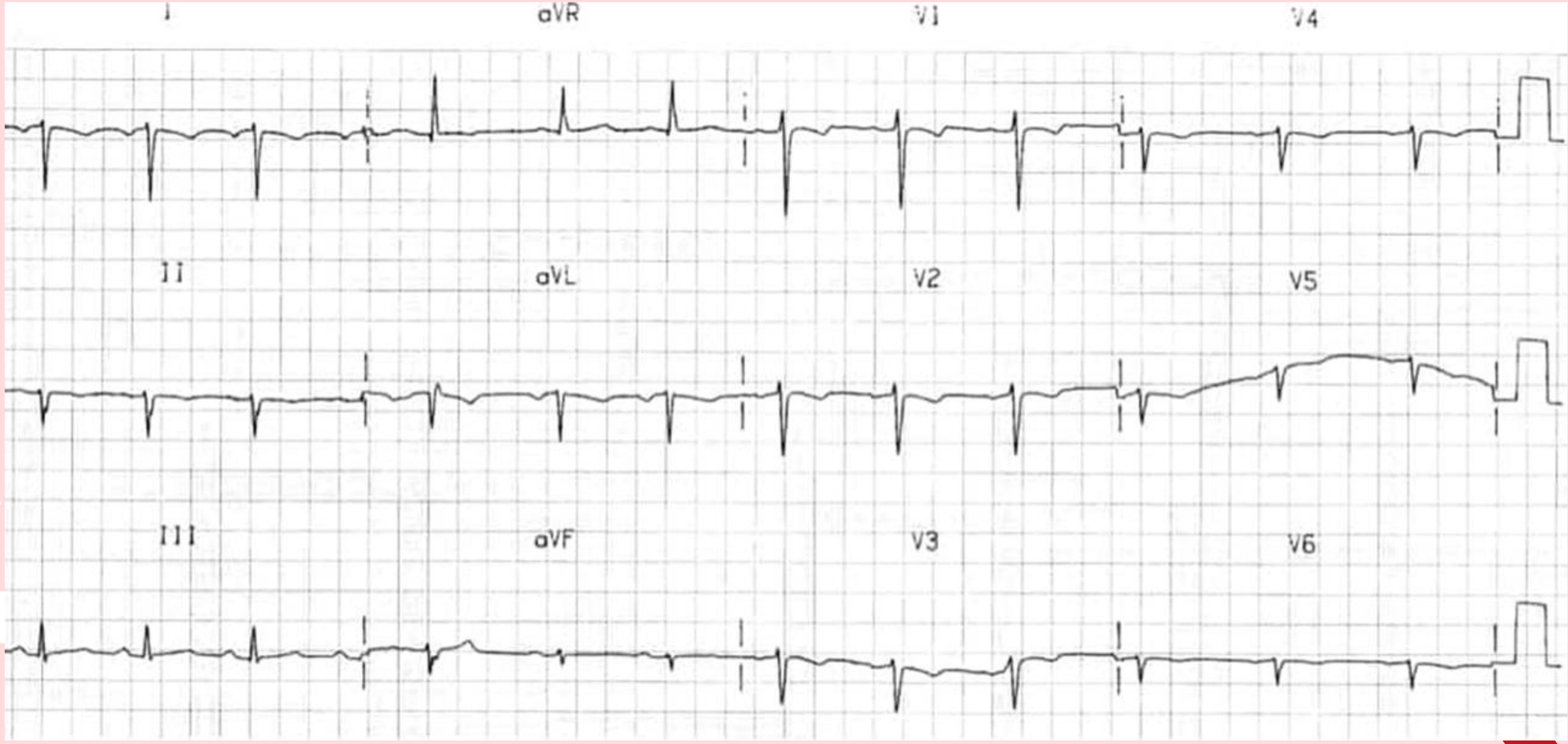

# Normal ECG

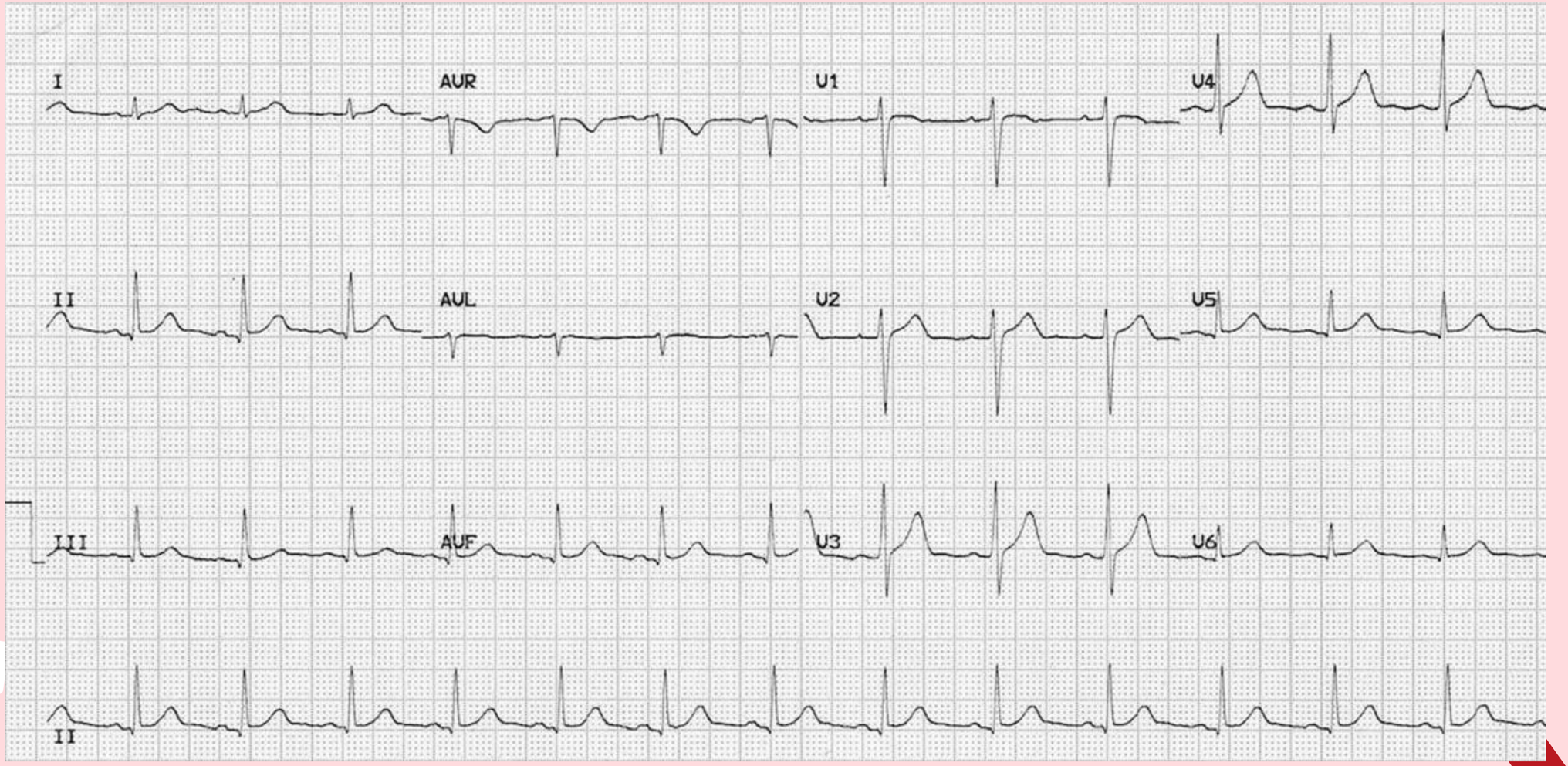

# Posterior ecg

- Posterior myocardial infarction (MI) accompanies 15-20% of STEMIs, usually occurring in the context of inferior or lateral infarction. Isolated posterior MI is less common (5-10% of infarcts), and the lack of ST elevation means that the diagnosis is often missed.

- Posterior extension of an inferior or lateral infarct implies a much larger area of myocardial damage, with an increased risk of left ventricular dysfunction and death. Always examine closely for evidence of posterior infarction in any patient with a lateral or inferior MI.

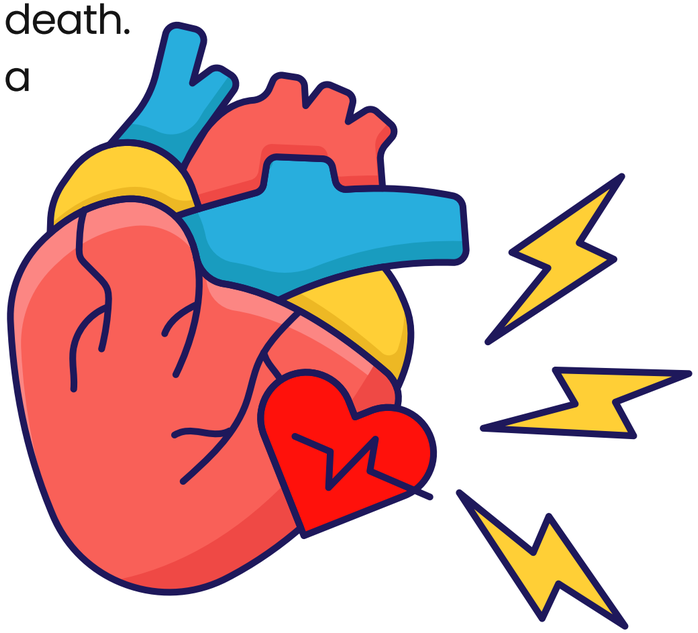

# Posterior ecg placement

- V7 – Left posterior axillary line, in the same horizontal plane as V6
- V8 – Tip of the left scapula, in the same horizontal plane as V6
- V9 – Left paraspinal region, in the same horizontal plane as V6

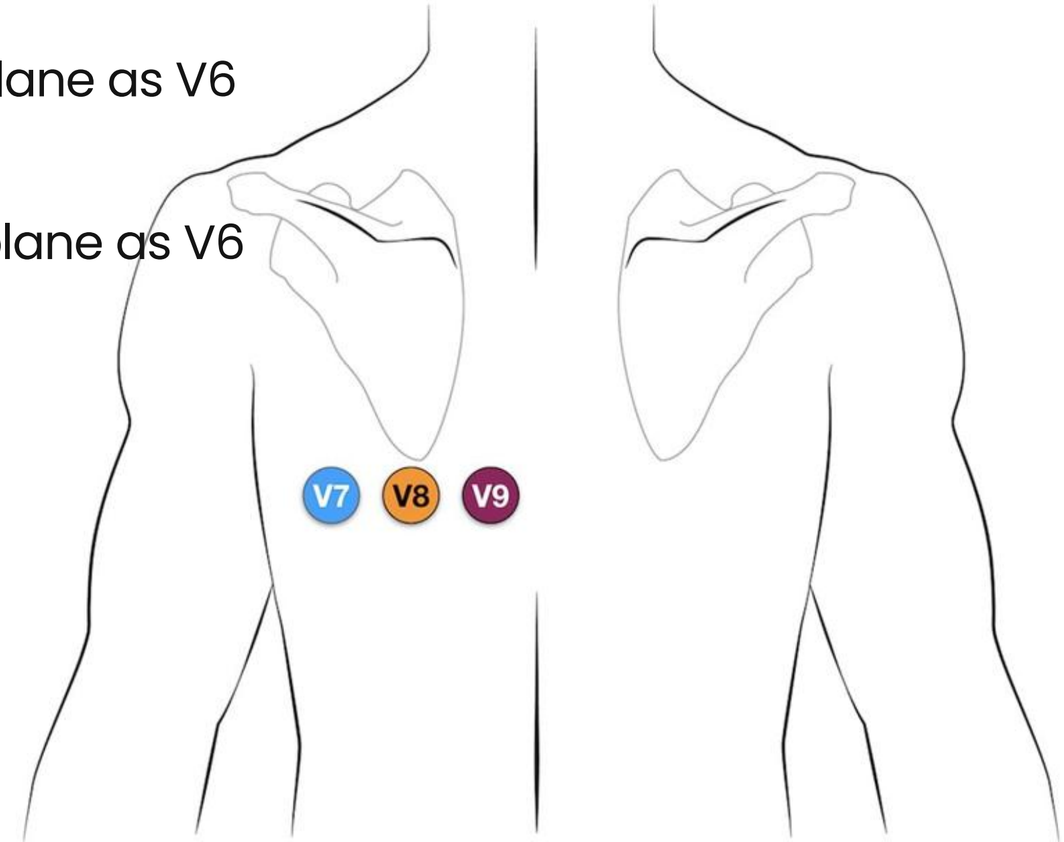

# Ecg diagnostic and criteria



**Posterior MI is suggested by the following changes in V1-V3**

**Tall, broad R waves (> 30ms)**

**Dominant R wave (R/S ratio > 1) in V2**

**Horizontal ST depression**

**Upright T waves**

# Example 1a

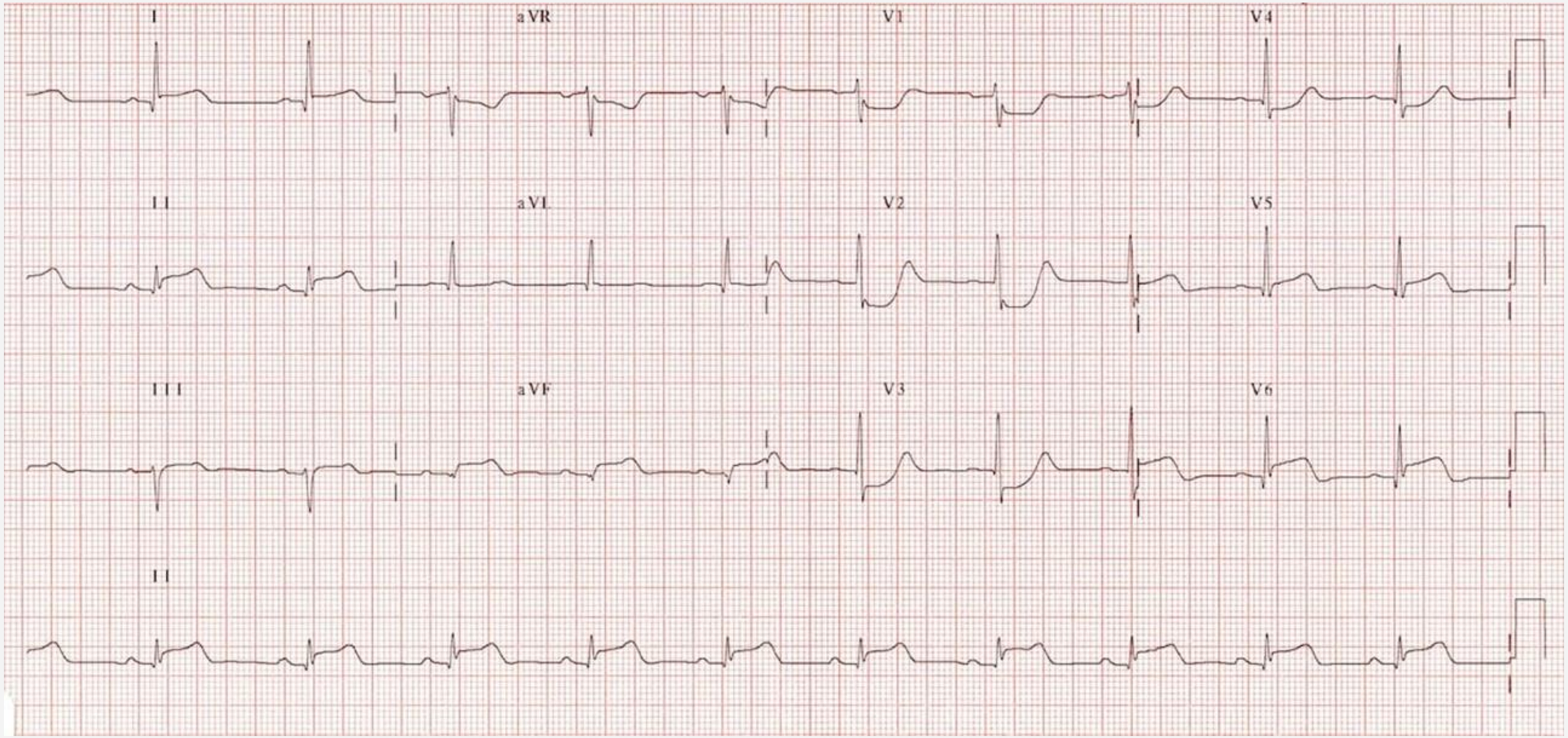

# Example 1b

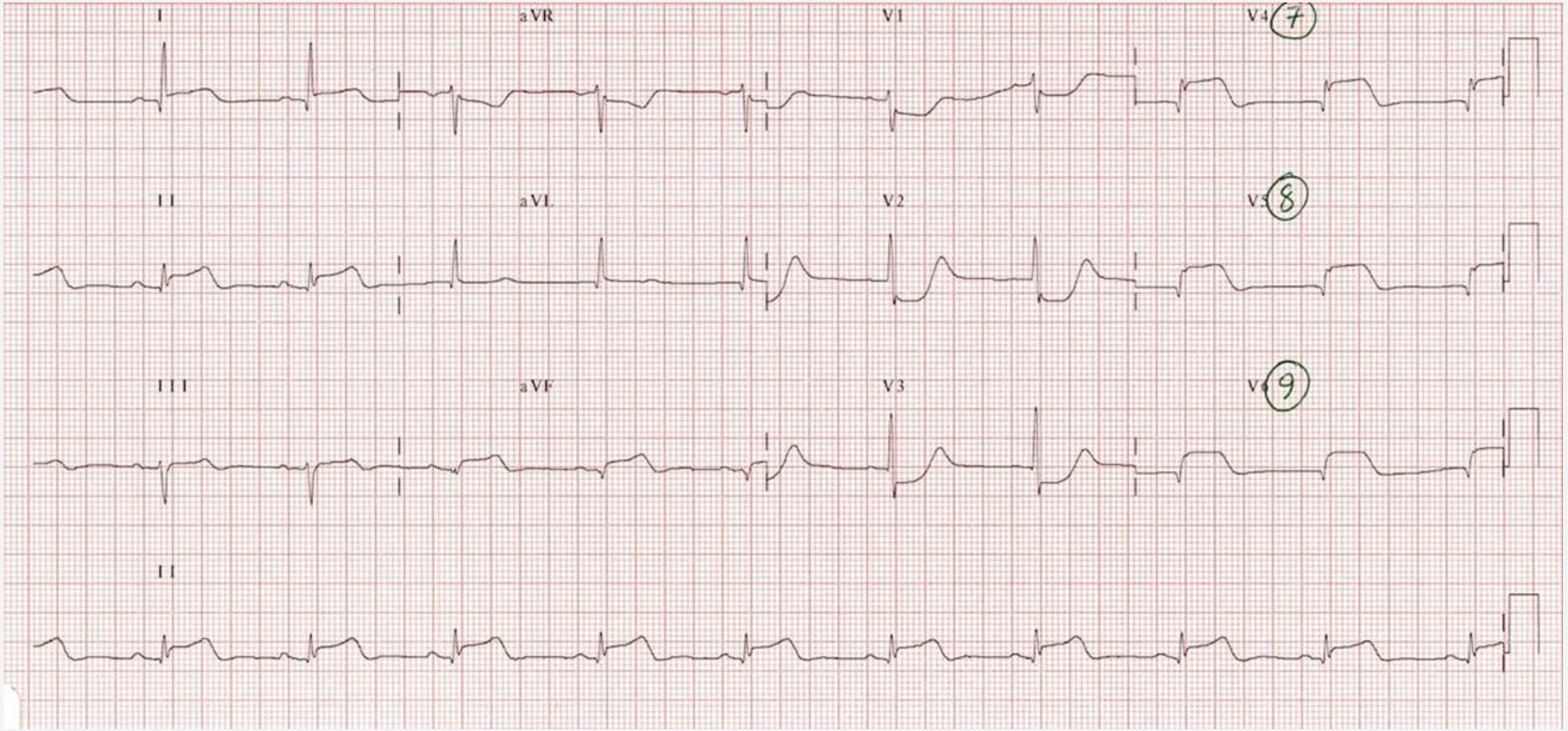

# Brugada syndrome

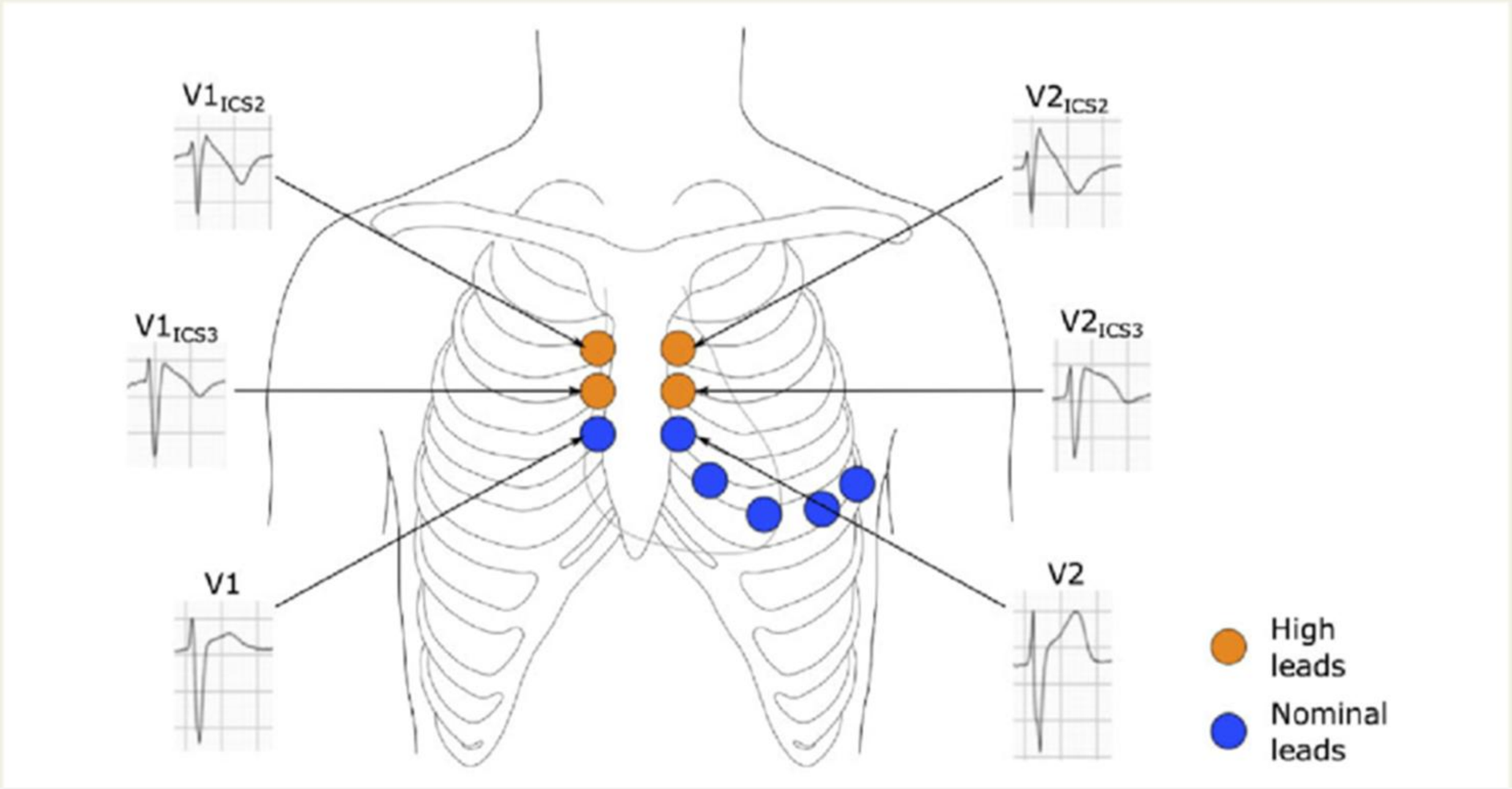

# Troubleshooting ECG

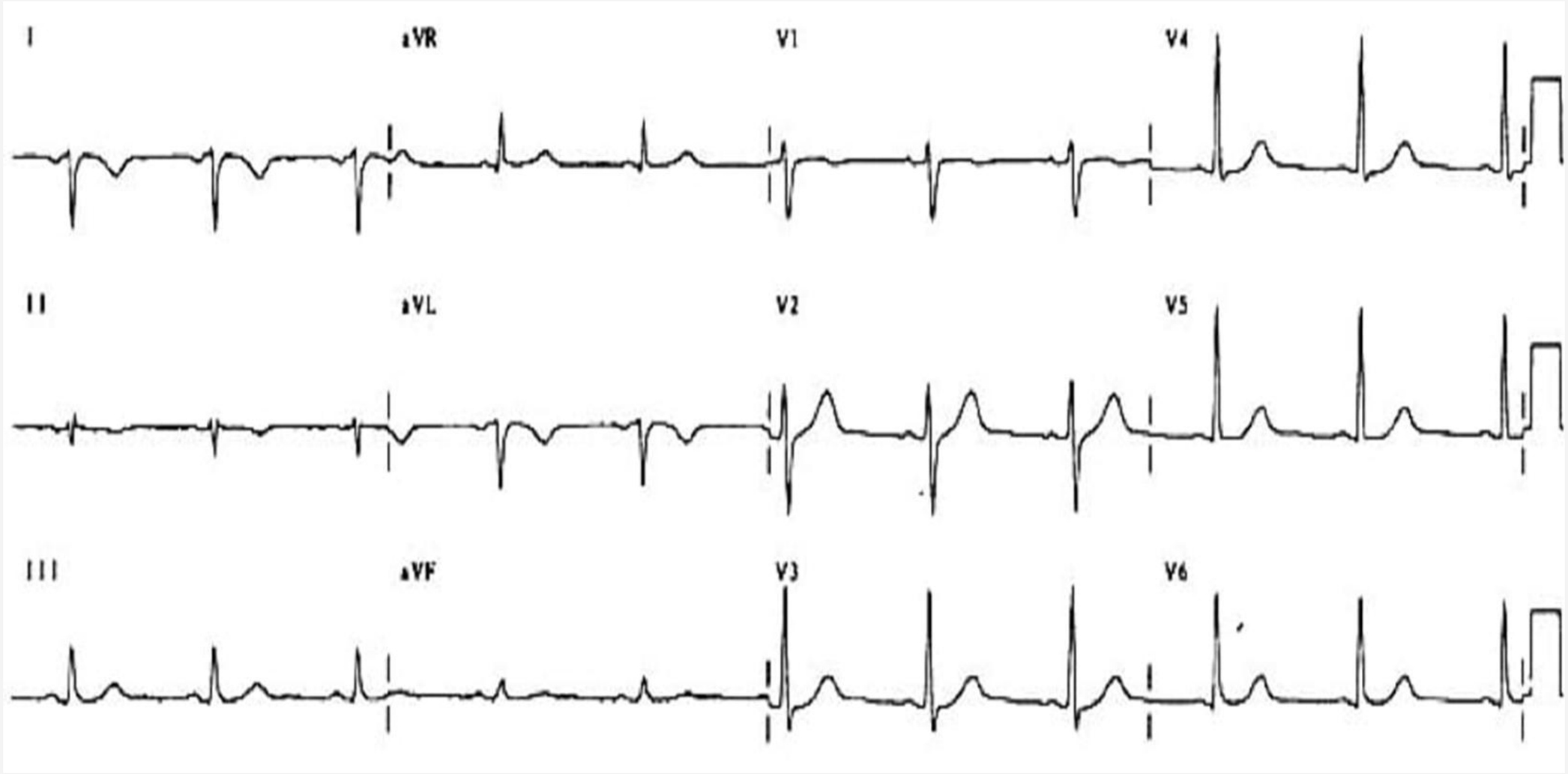

# NORMAL ECG

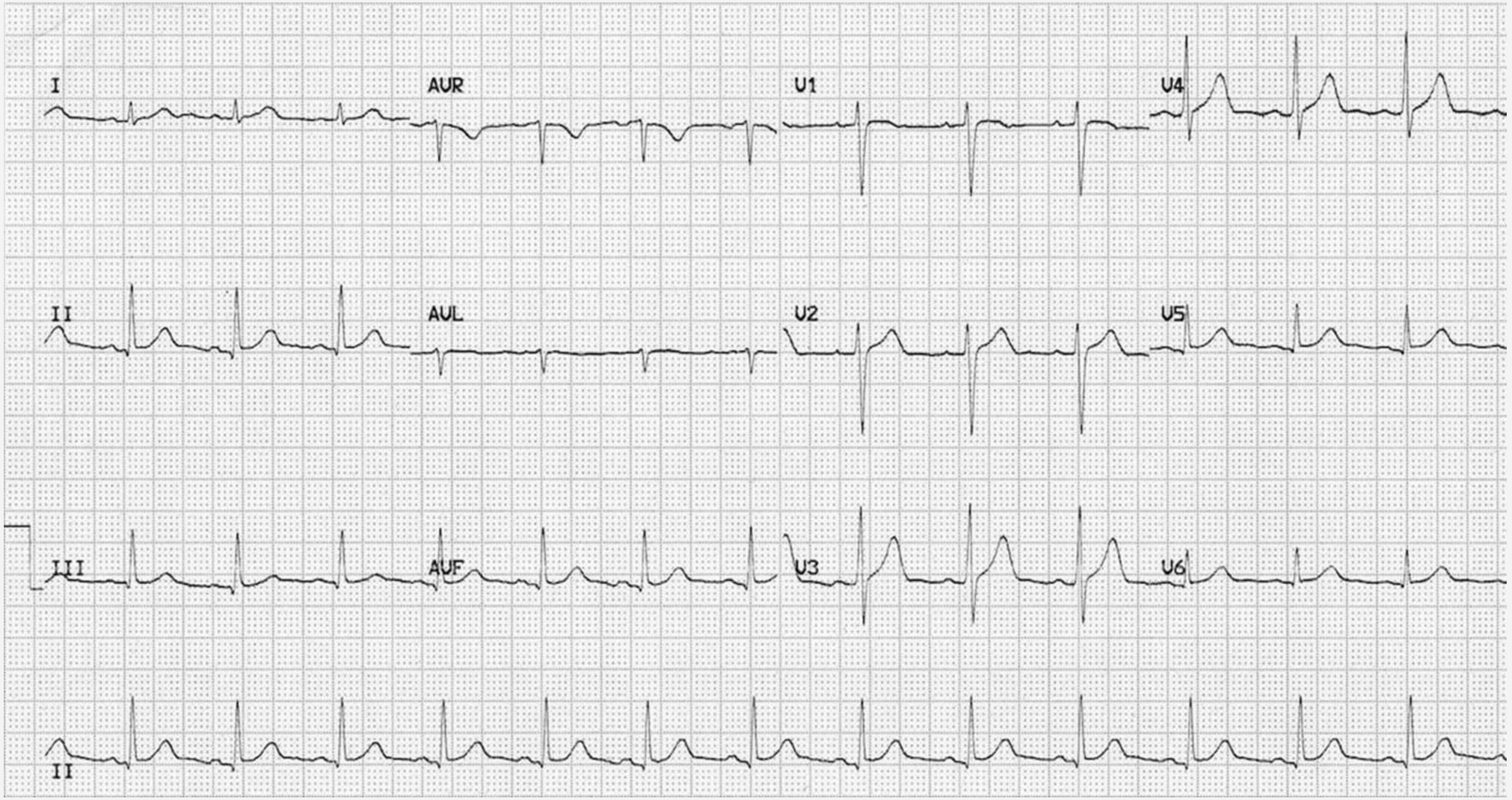

# Take Home Message

- ***Skin preparation***
- ***ECG machine calibration***
- ***ECG lead placement/lead connection***
- ***Condition of patient***
- ***Patient preparation***

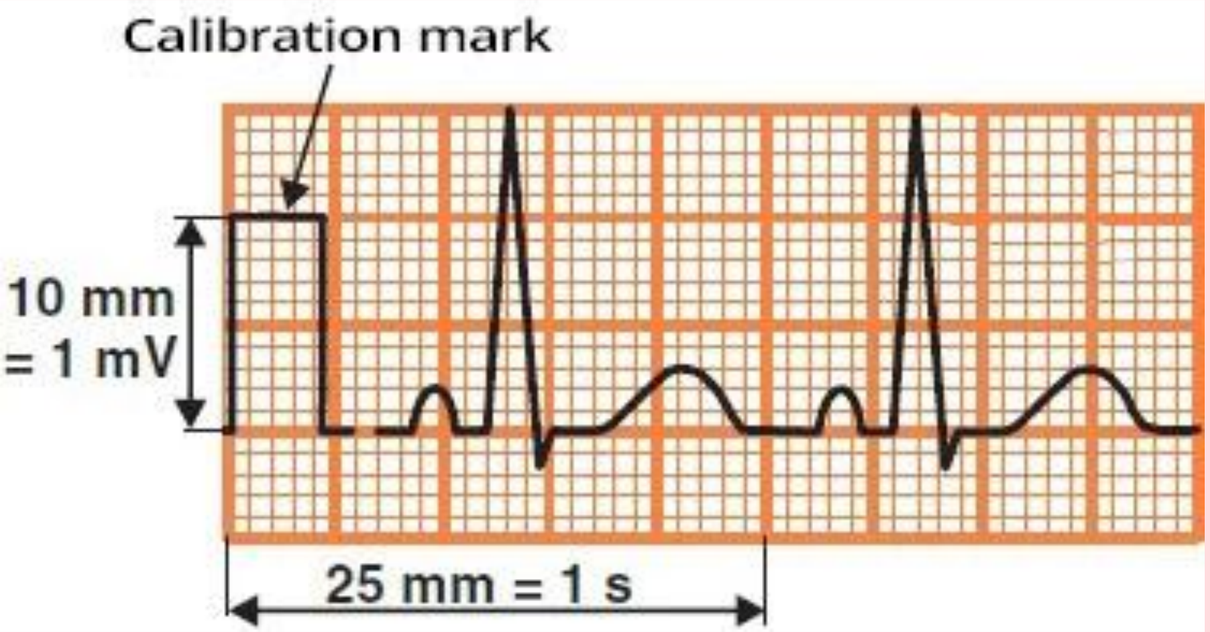


***

SALFORD & CO.

# THANK YOU



Basic ECG COURSE 2026

Presented by:
PPP MUHAMMAD AMIRUL NASRALLAH BIN NASRUN