Introduction to ECG

DR. MIRHANSYAH PERDANA



Learning Objective

- Understand the heart’s electrical signals
- Understand how ECG records these signals on paper
- Understand what ECG leads and ECG paper mean

Background

- ECG is a recording of the heart’s electrical activity
- Giving information about arrhythmias, ischemia, infarction, chamber dilatation, and electrolyte abnormalities.
- ECG: A Simple Test That Saves Lives
  - Acute myocardial infarction
  - Severe bradycardia or tachycardia
- ECG is quick, cheap, and widely available

Background







Willem Einthoven, was born in Semarang, a professor in Leyden. He was rewarded by a Nobel prize in medicine in 1924 for his work on ECG.

The Heart Is an Electrical Organ

- Pacemaker cell automaticity
- SA node 60 – 100 bpm, AV node 40 – 60 bpm, ventricle 20 – 40 bpm

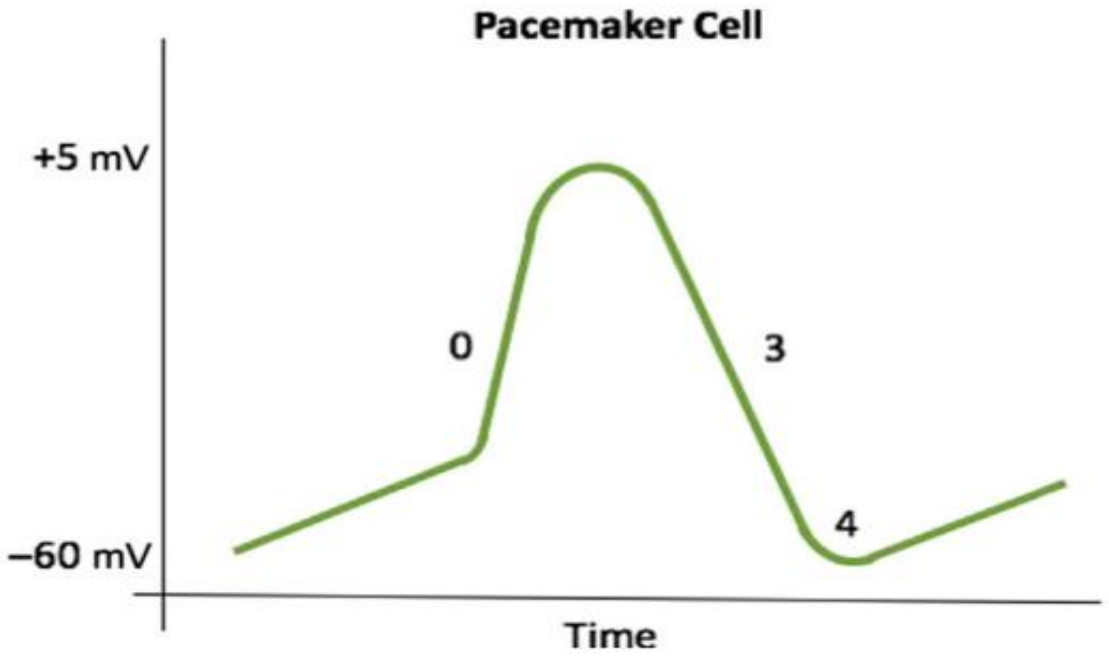

Heart Electrical Conduction

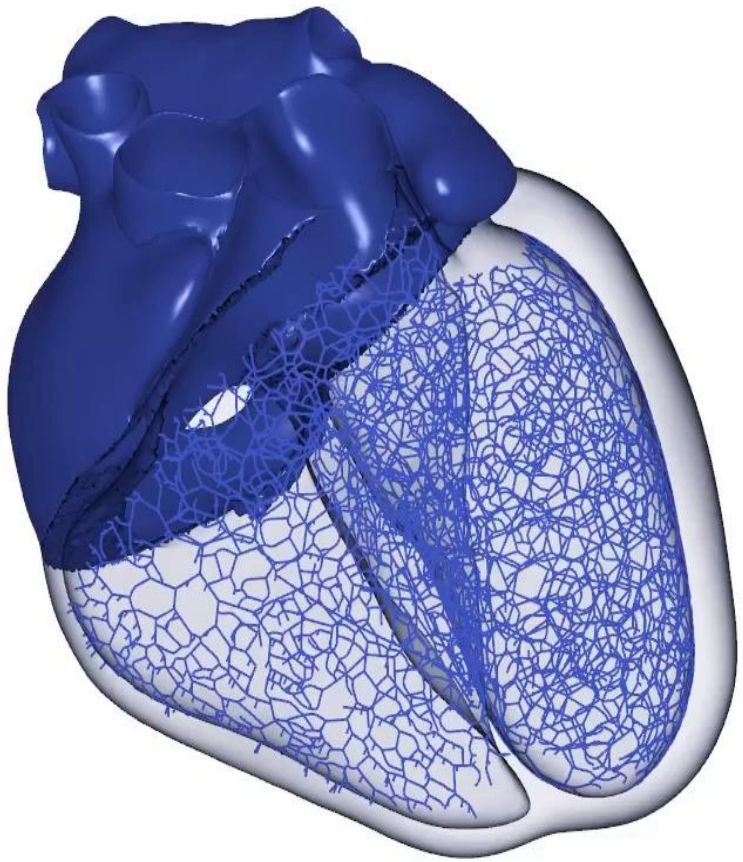

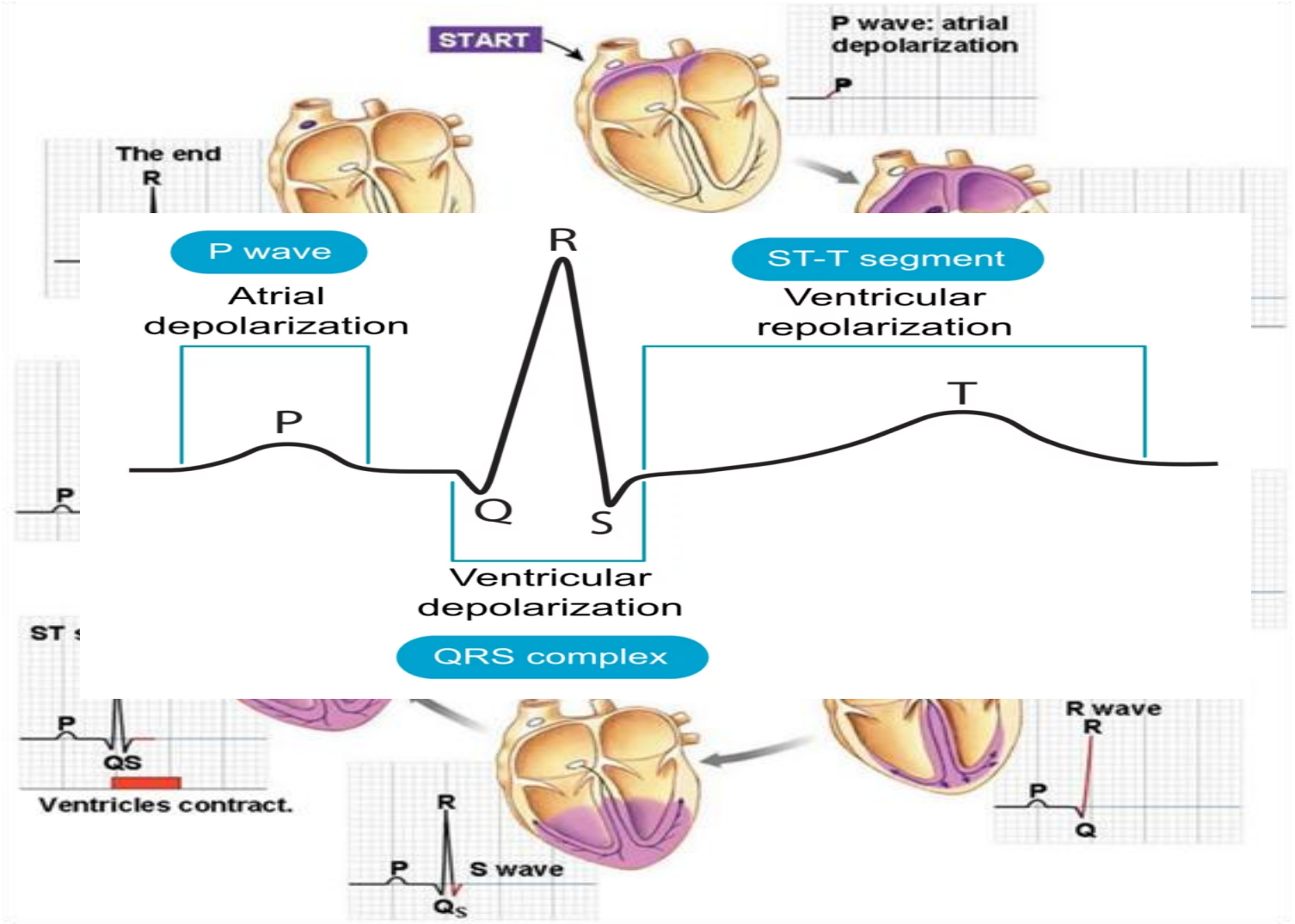

Is it Sinus Rhythm?

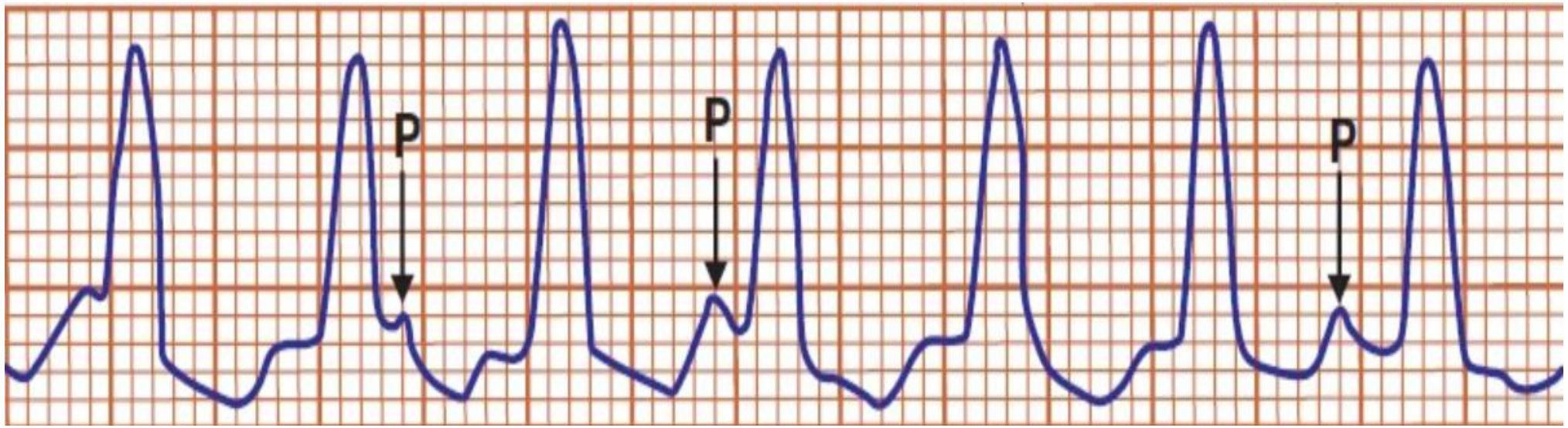

Electrical Activity Is a Vector

- It has **amplitude** and **direction.**

Amplitude (How big?)

- Reflects **amount of myocardium depolarizing**
- Influenced by:
  - Muscle mass
  - Distance from electrode
- Shown as:
  - **Height of the deflection** on ECG

ECG Amplitude

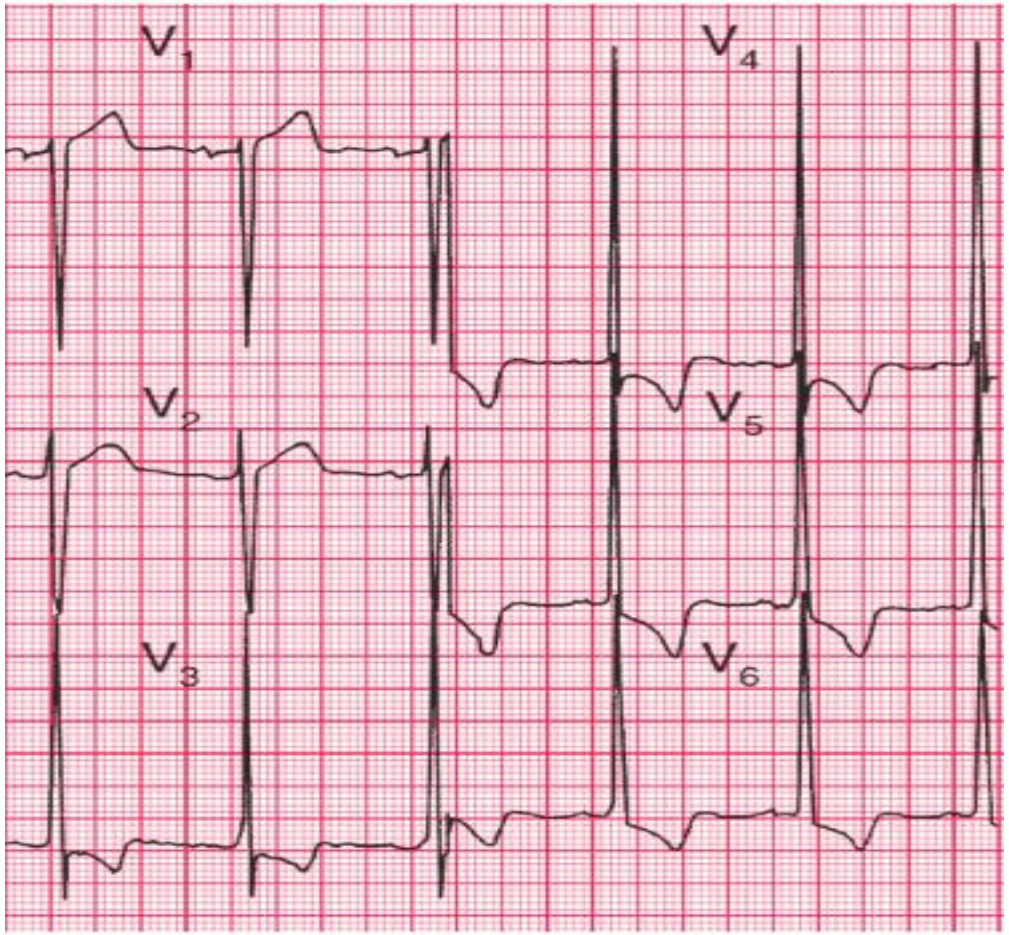

LVH

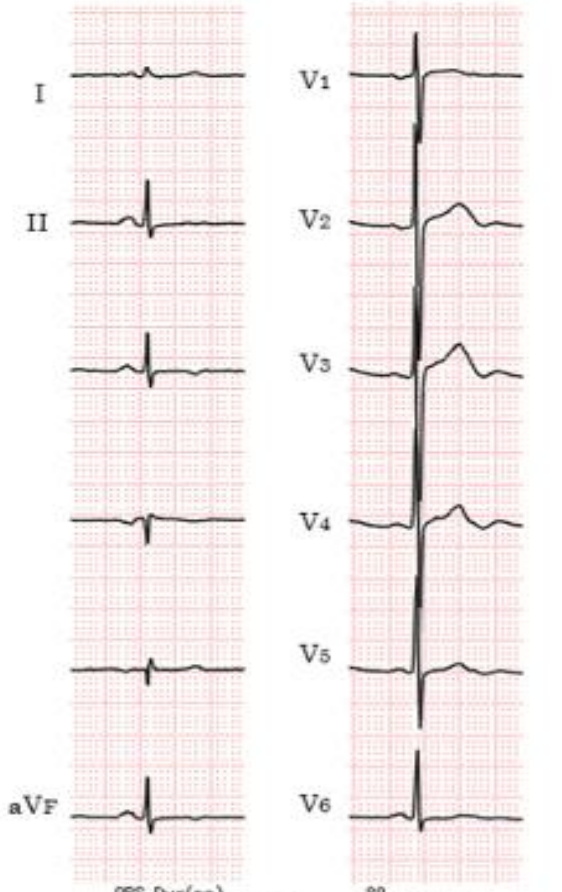

Underweight (BMI = 15.7 kg/m^2)

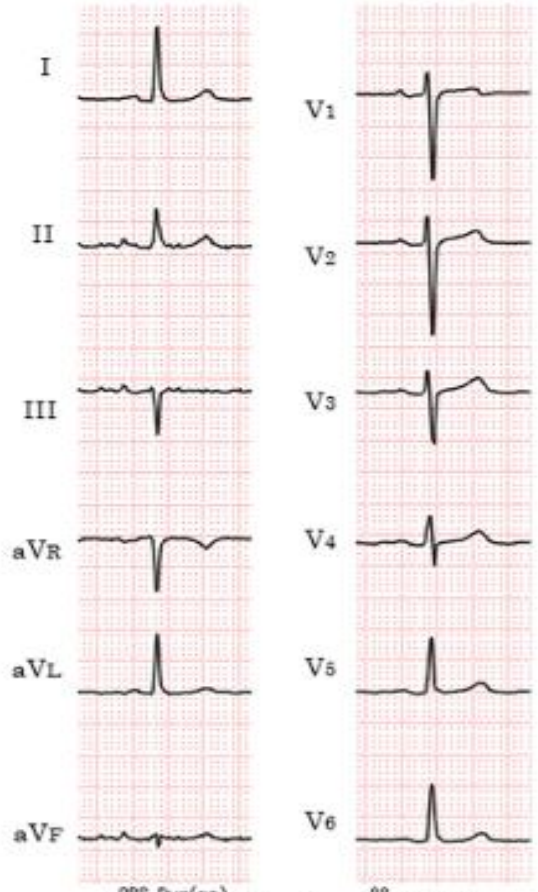

Obese (BMI = 40.9 kg/m^2)

What is the diagnosis?



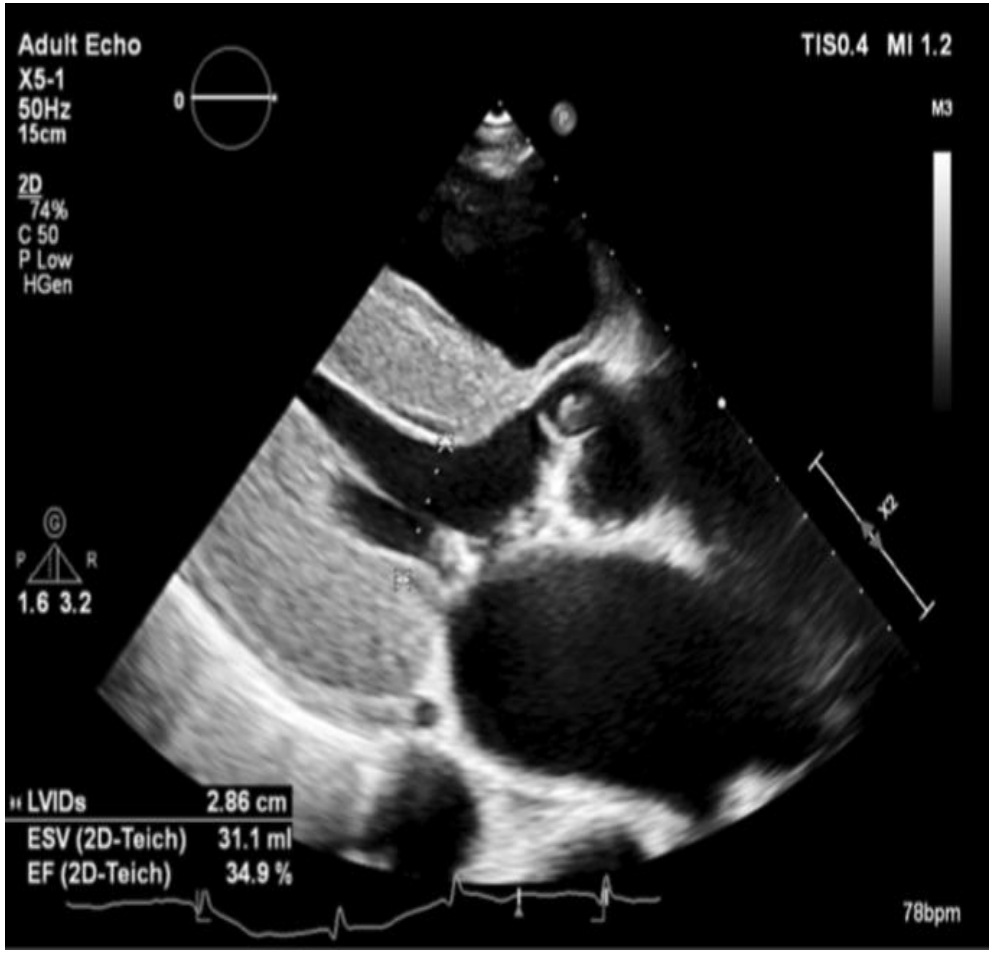

What is the diagnosis?

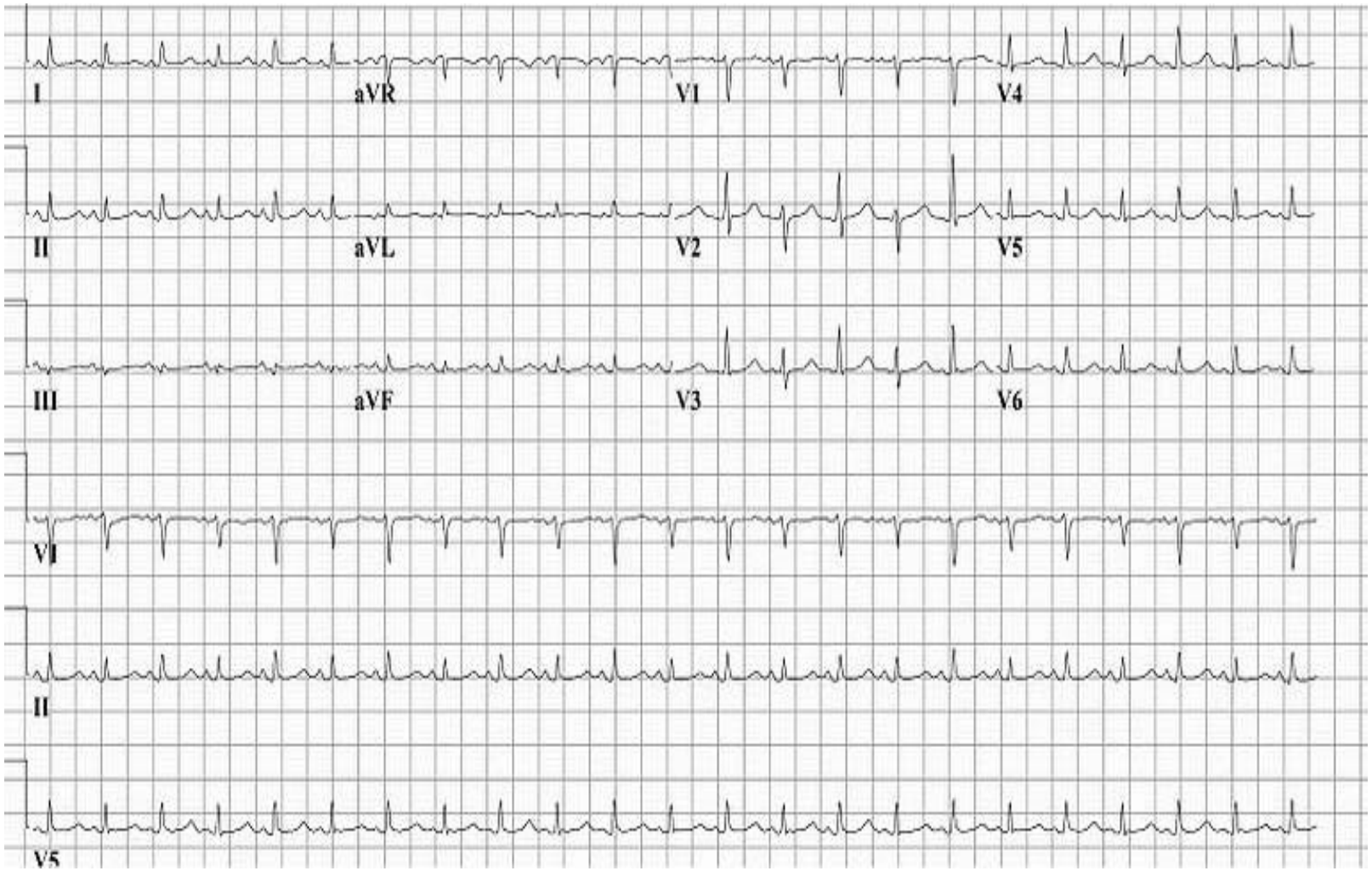

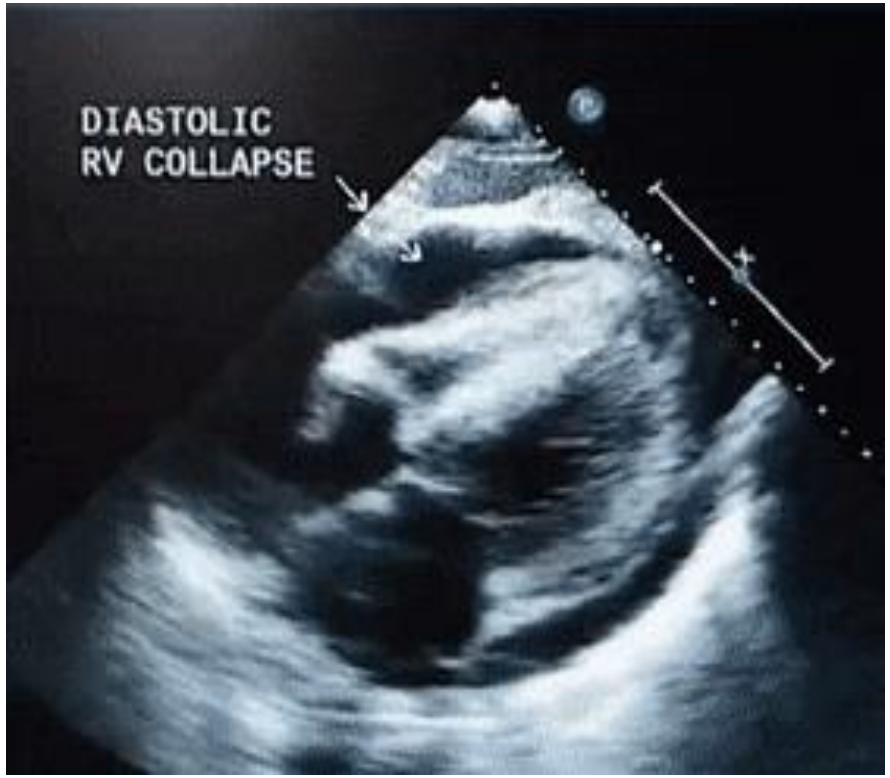

Electrical Wavefront Direction

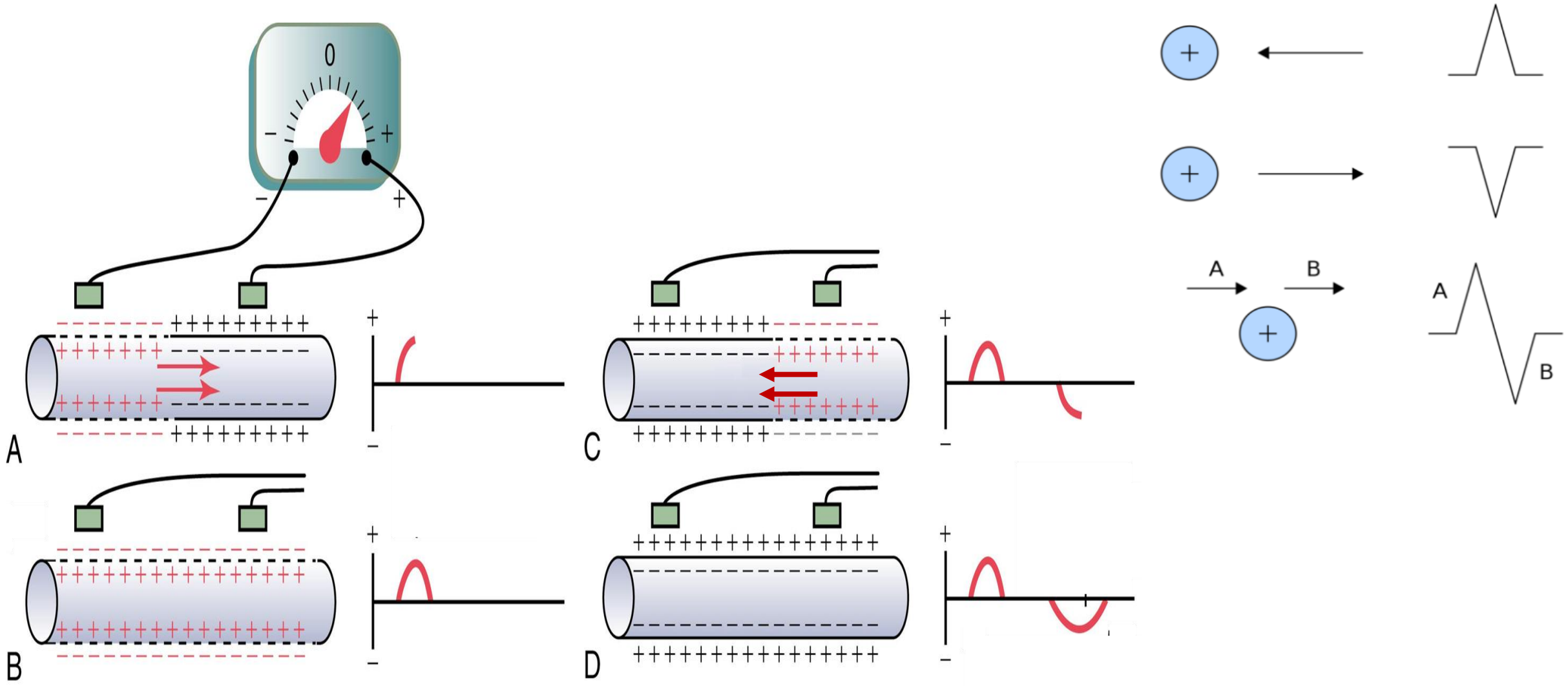

ECG Waveform

- Depends on Heart Electrical Vectors and Lead Orientation

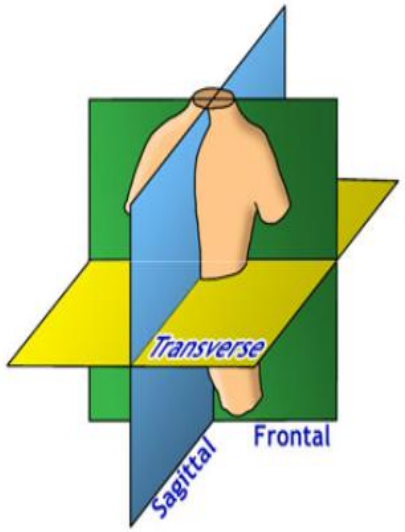

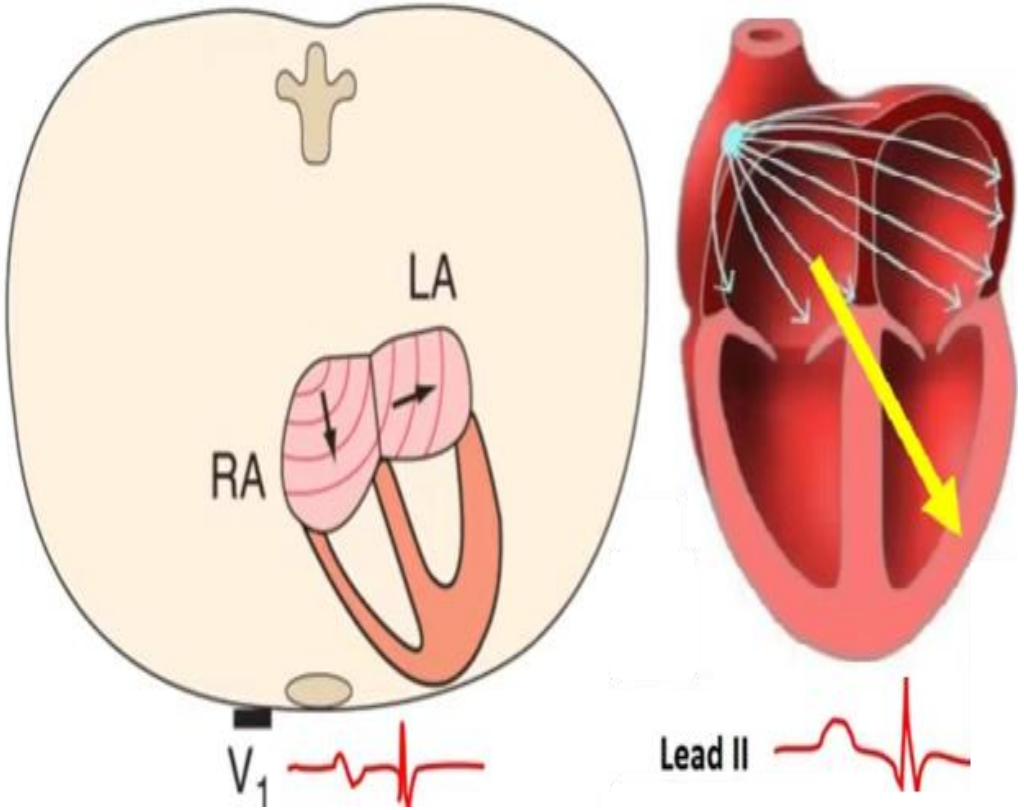

Atrial depolarization :
Right → Left, Superior → Inferior, anterior → posterior

Ventricle depolarization :
Right → left, → Left, Superior → Inferior, anterior → posterior

Lead Orientation

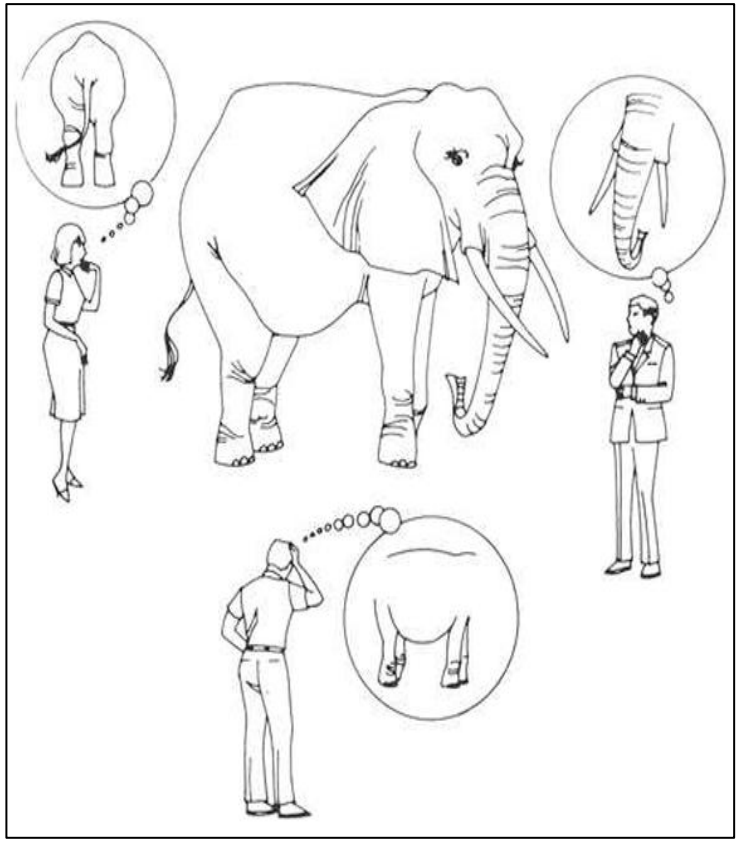

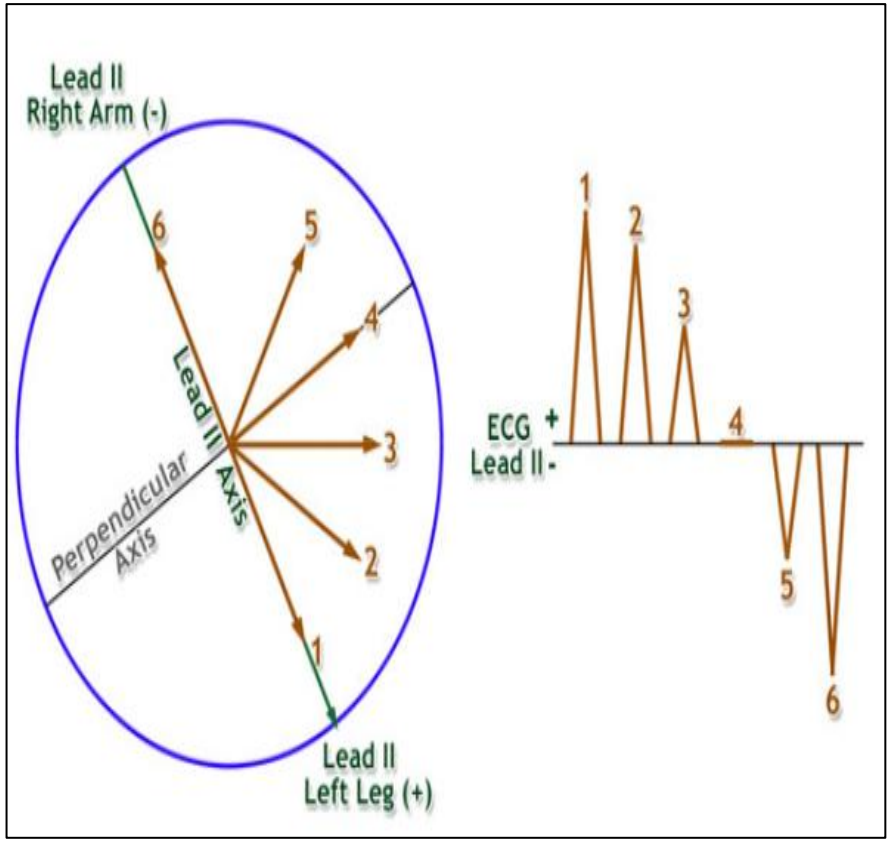

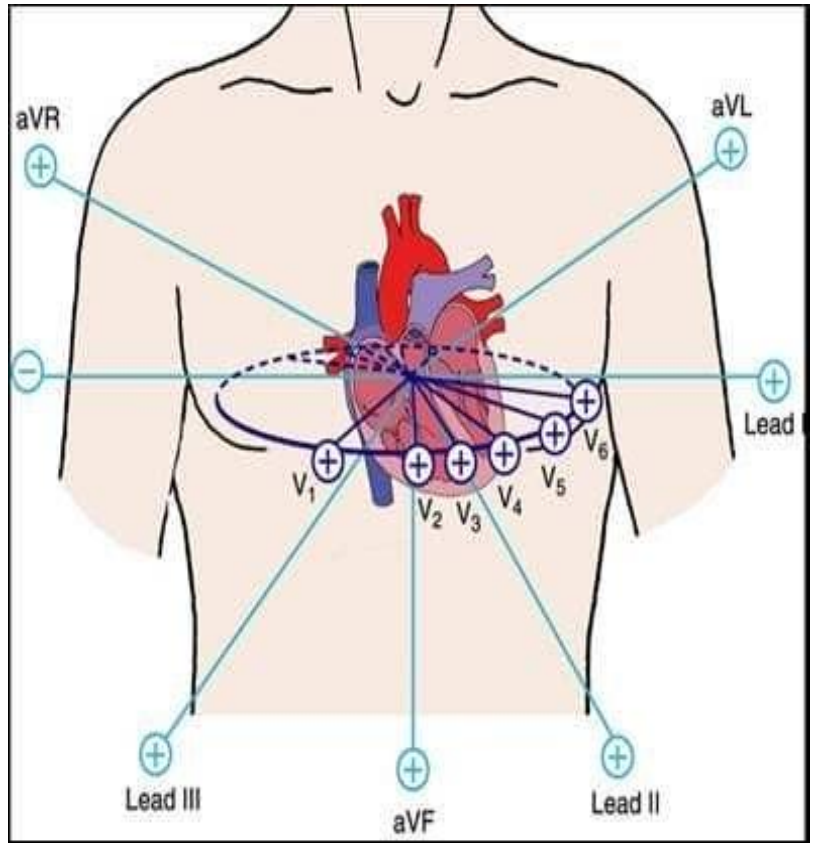

Frontal Axis

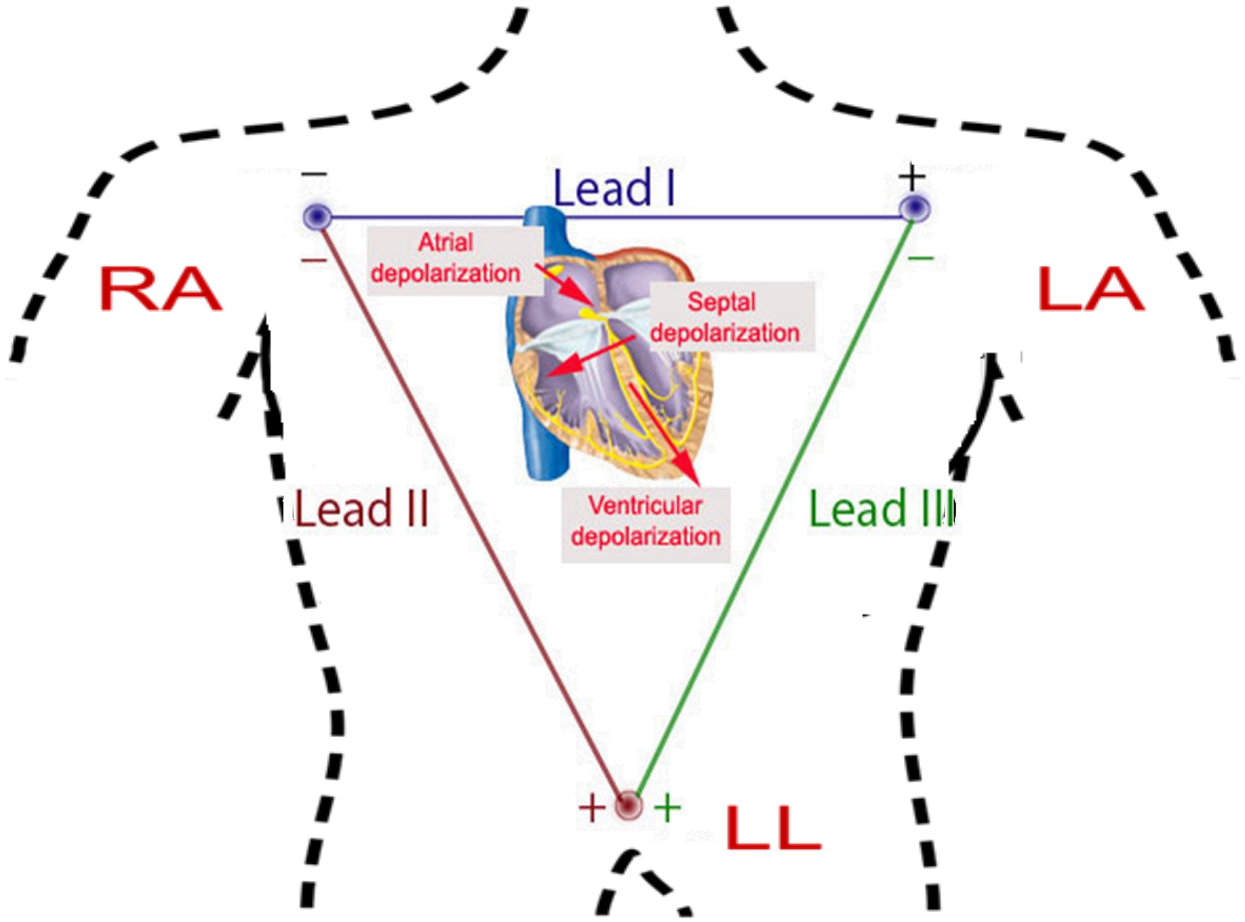

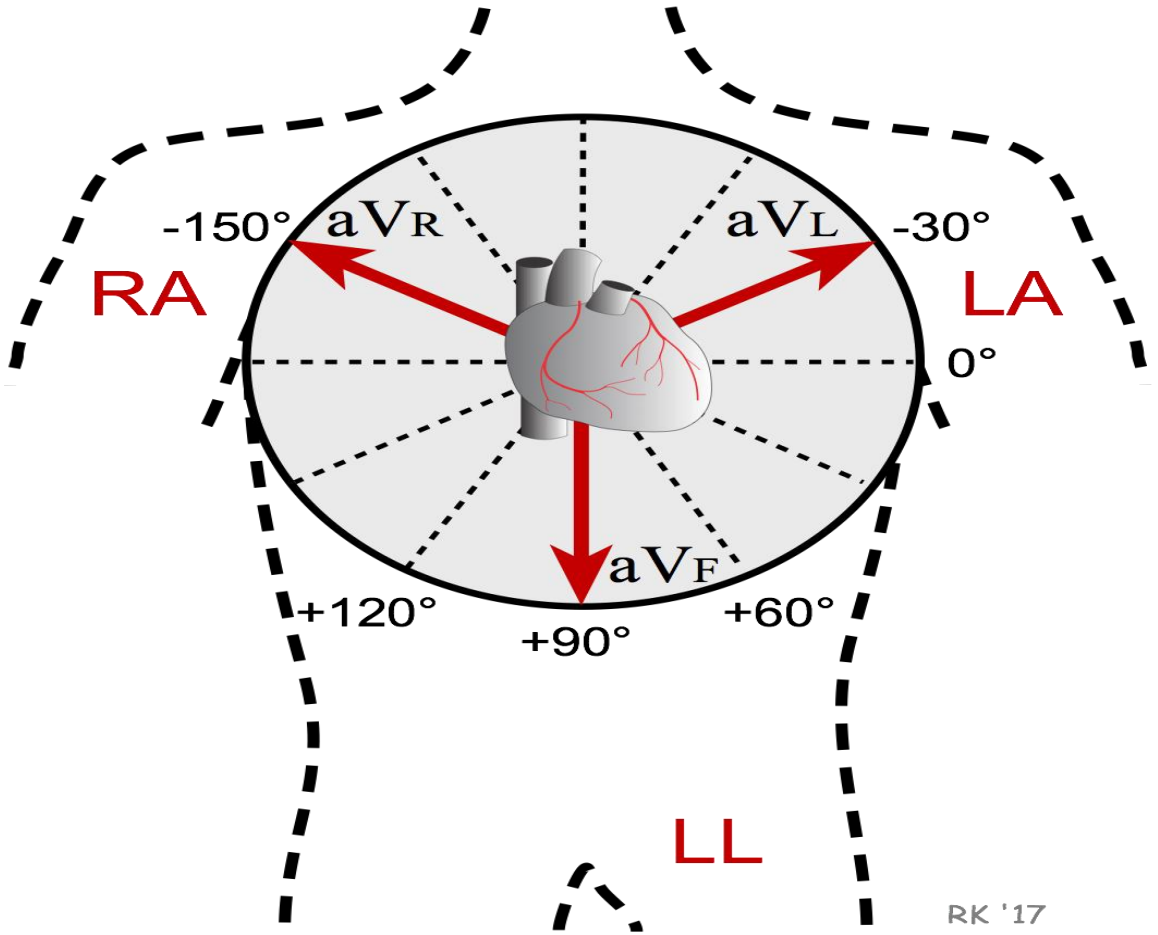

RK '17

Transverse Axis Plane

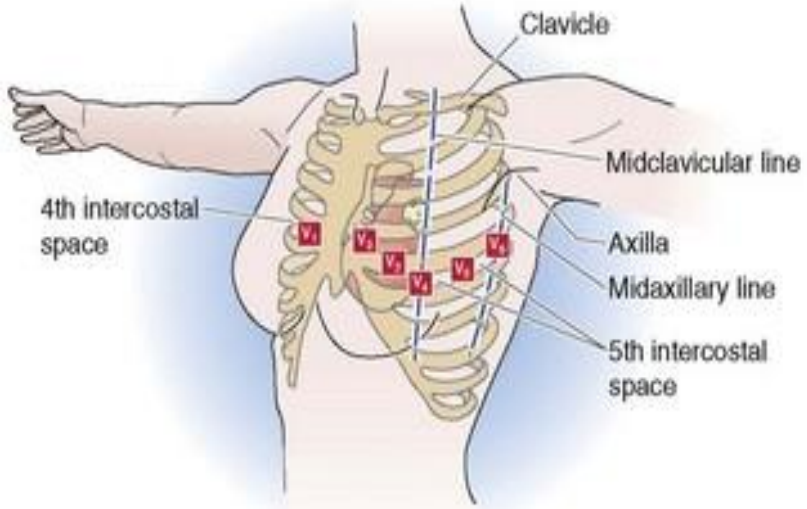

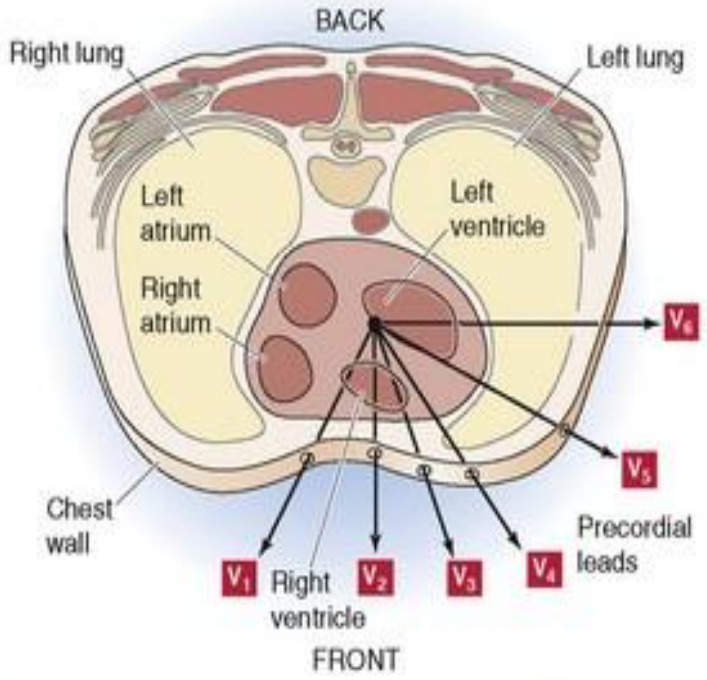

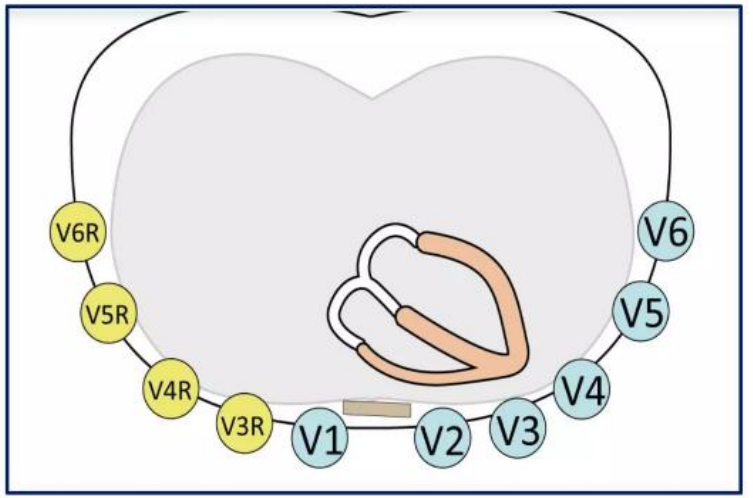

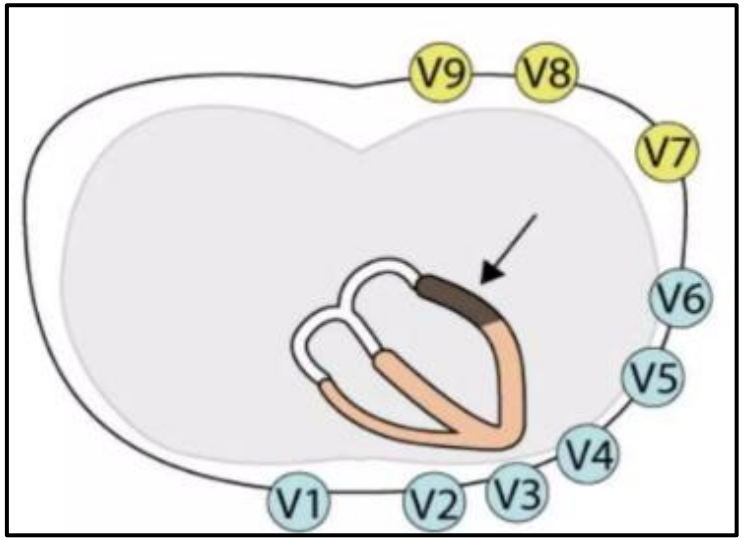

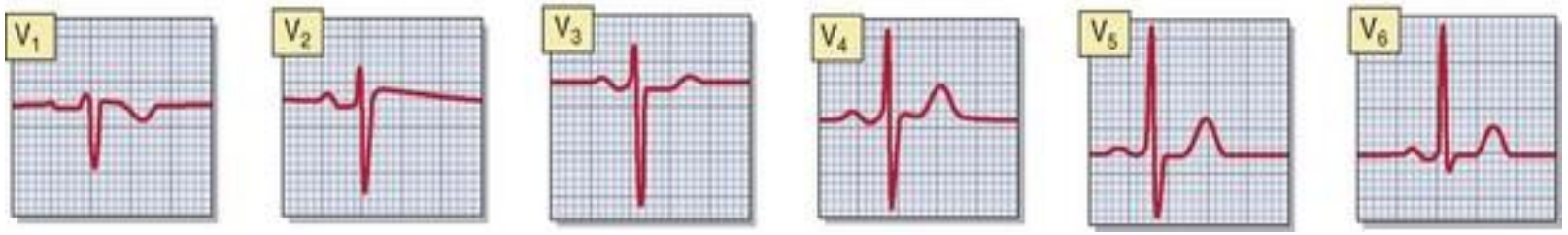

ECG Territories

INFERIOR	ANTEROSEPTAL	ANTEROAPICAL	ANTEROLATERAL	LATERAL
II, III, aVF	V1 – V2	V3 – V4	V5 – V6	I, aVL
RCA	LAD	LAD	Cx	Cx

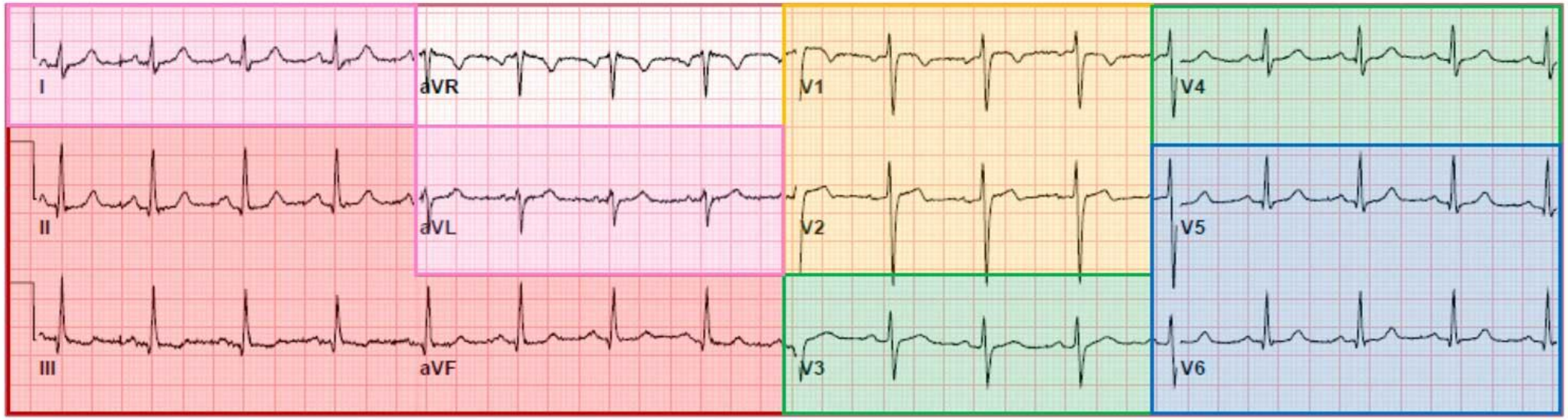

Is the ECG Reversed?

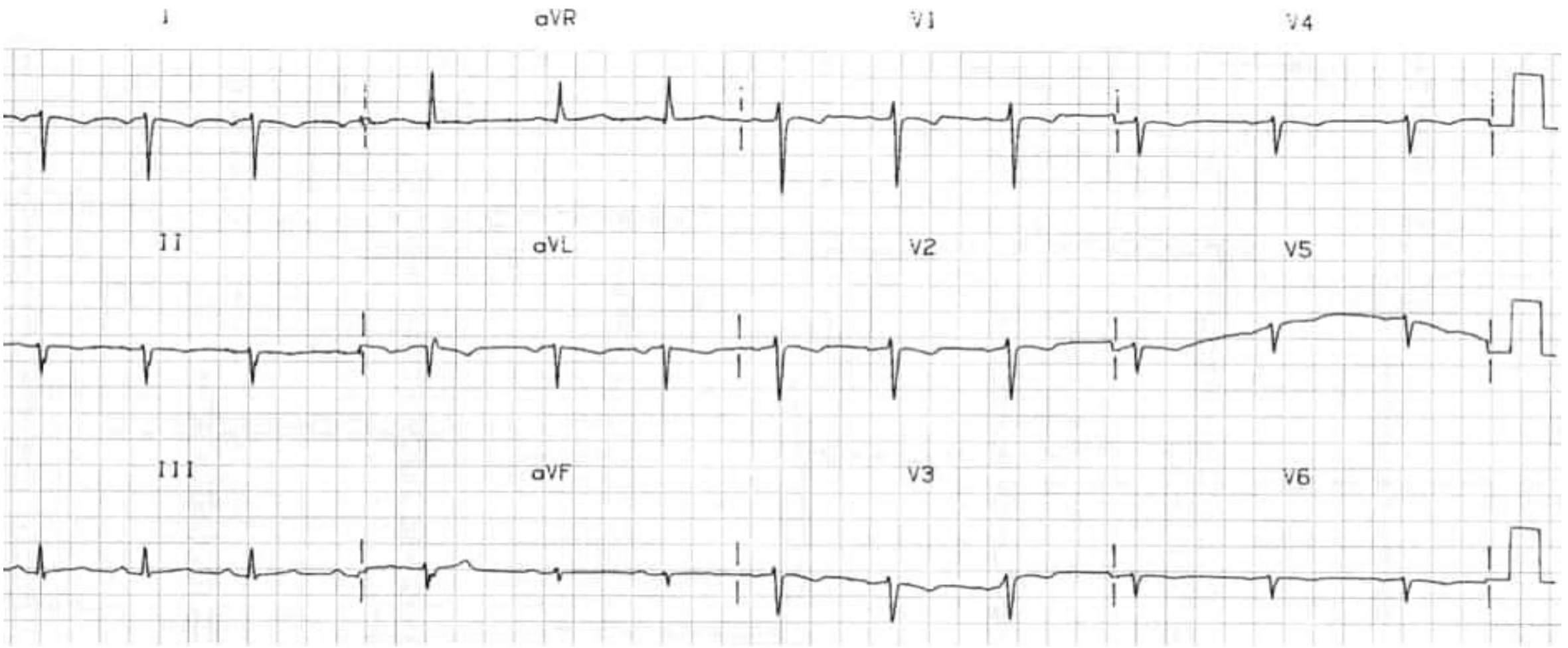

ECG Paper

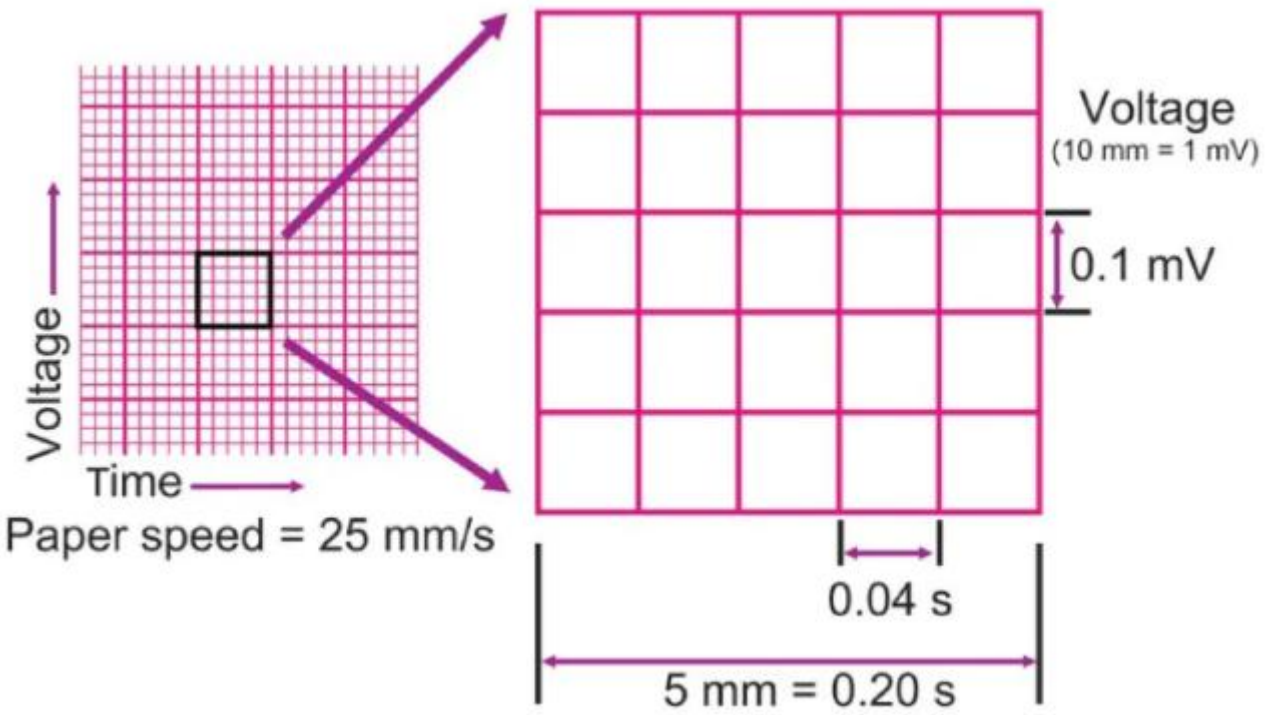

- 25 mm/s = 1500 mm/min
- 1 mm = 1 small box
- 5 small box = 1 big box
- 25 mm/s = 300 big box/min

HR = 1500/small boxes RR

HR = 300/big boxes RR

What is the ventricle rate?



Normal ECG

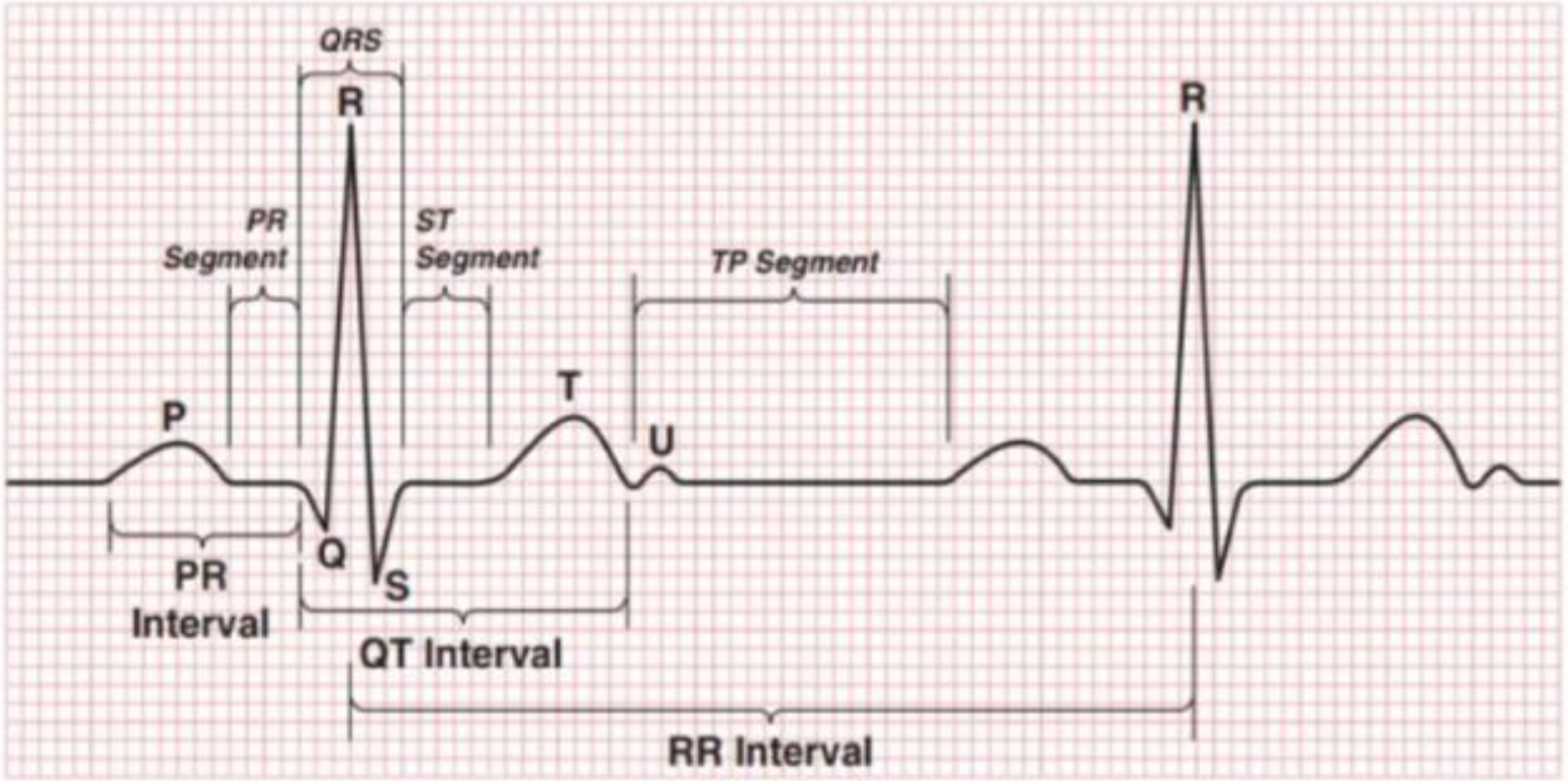
QRS
R
PR
Segment
ST
Segment
TP Segment
R
T
P
U
Q
S
PR
Interval
QT Interval
RR Interval

P Wave


Lead aVR

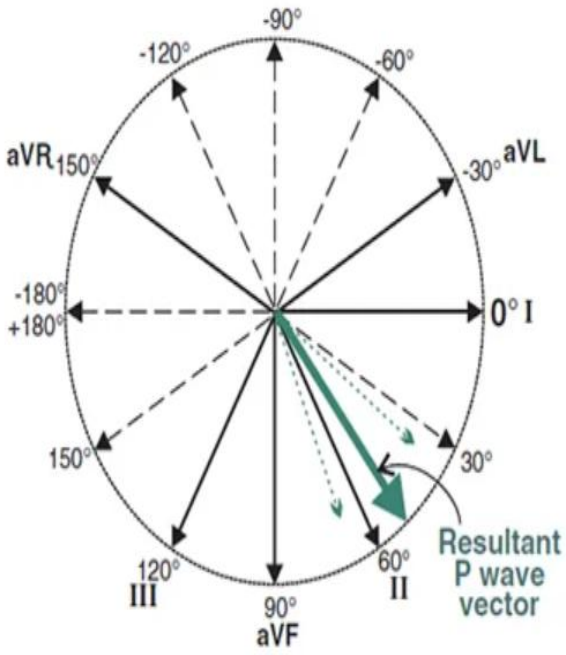
-90°
-120°
-60°
aVR
150°
-30°
aVL
-180°
+180°
0° I
150°
30°
120°
III
90°
aVF
60°
II
Resultant
P wave
vector


Lead II

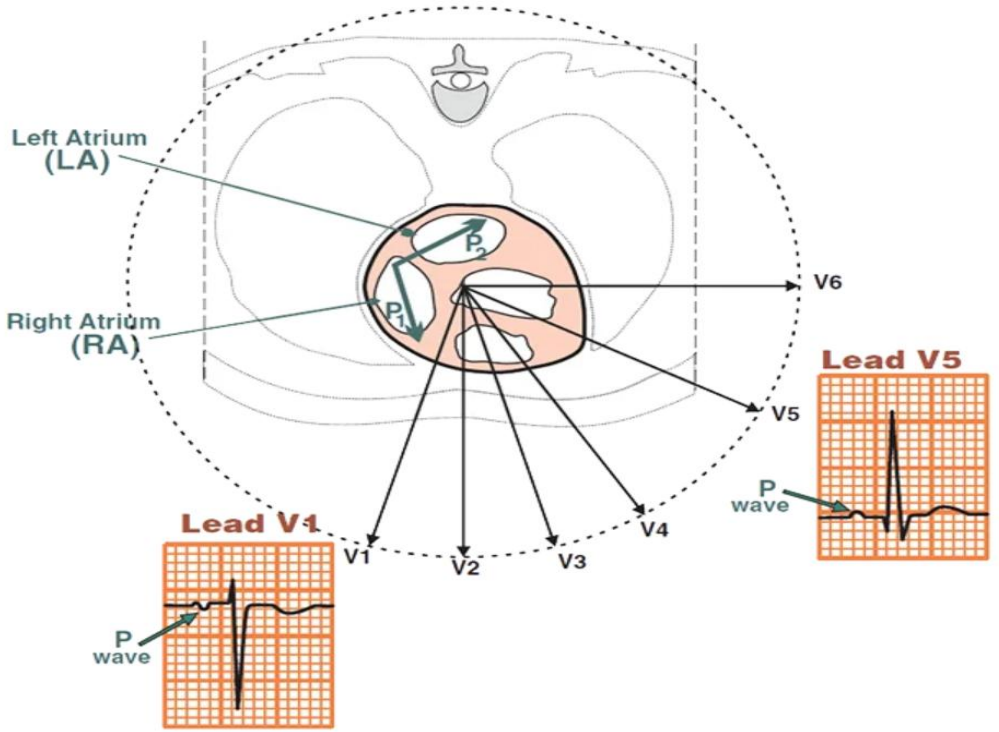
Left Atrium
(LA)
Right Atrium
(RA)
P2
P1
V6
V5
V4
V3
V2
V1
Lead V5
P
wave
Lead V1
P
wave

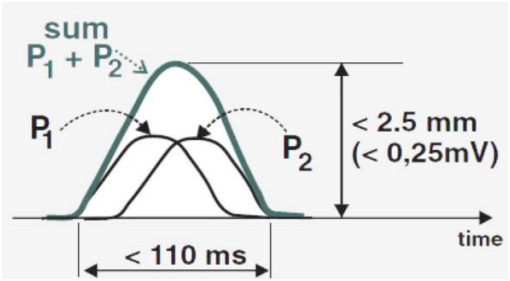
sum
P1 + P2
P1
P2
< 2.5 mm
(< 0,25mV)
< 110 ms
time

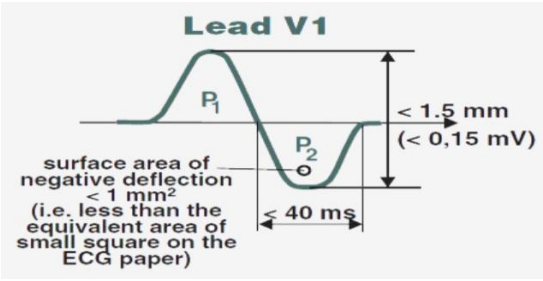
Lead V1
P1
P2
< 1.5 mm
(< 0,15 mV)
surface area of
negative deflection
< 1 mm²
(i.e. less than the
equivalent area of
small square on the
ECG paper)
< 40 ms

21 years old, always felt fast HR, dpysnea over the past 6 months when walking to work. Told by dr that was ‘normal’ for her.
What is the likely ECG diagnosis?

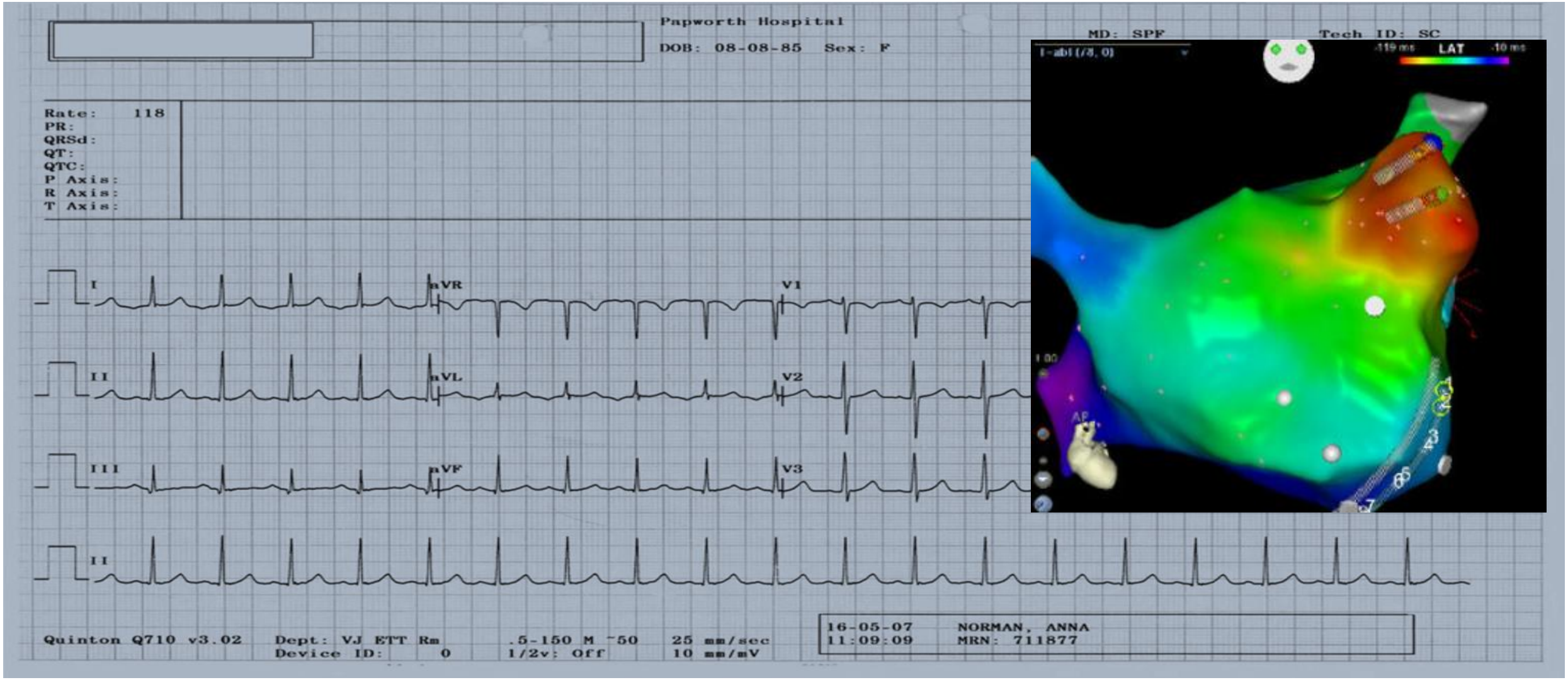

PR Interval

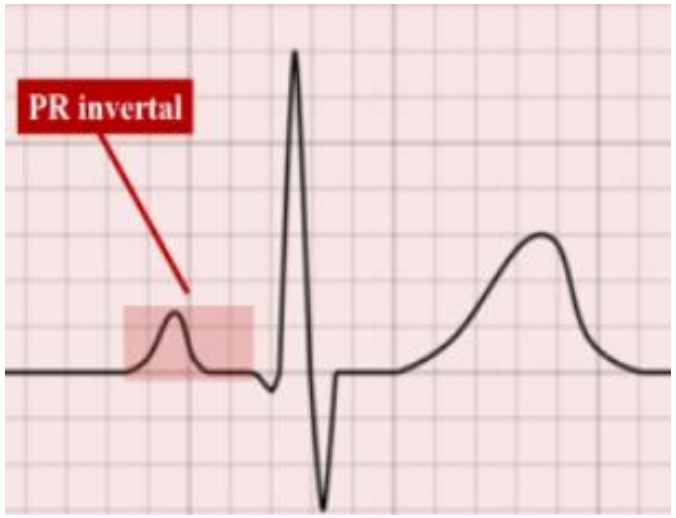
PR invertal

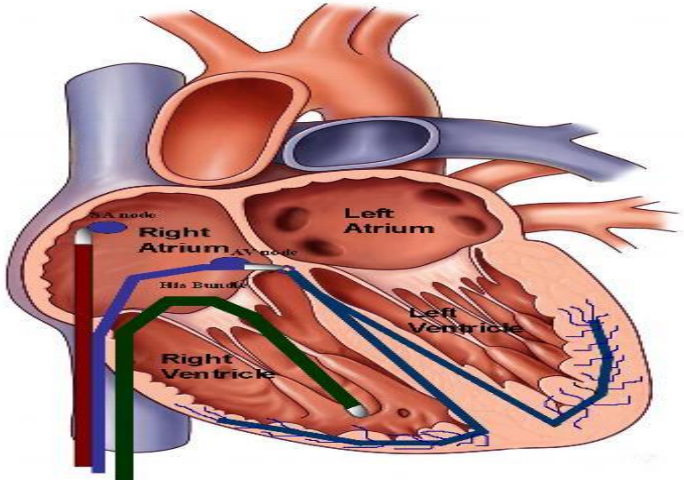
Right Atrium
Left Atrium
Right Ventricle
Left Ventricle

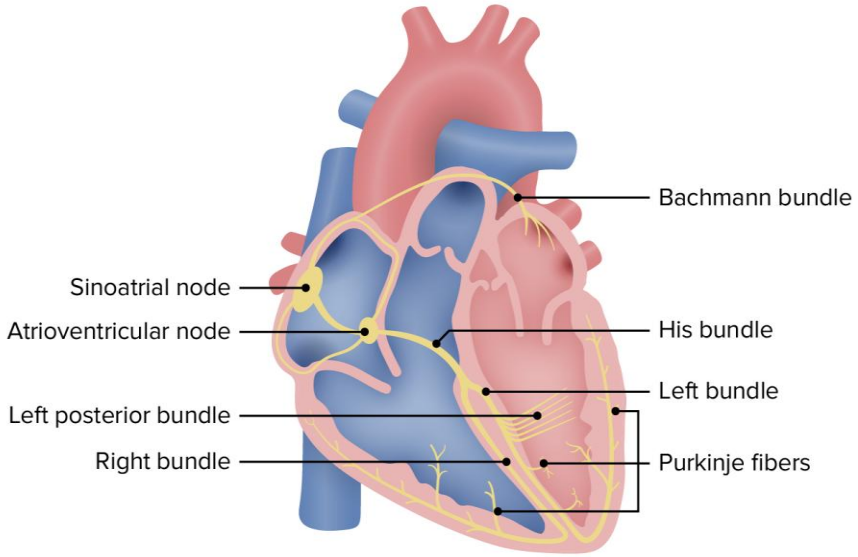
Bachmann bundle
Sinoatrial node
Atrioventricular node
His bundle
Left bundle
Left posterior bundle
Right bundle
Purkinje fibers

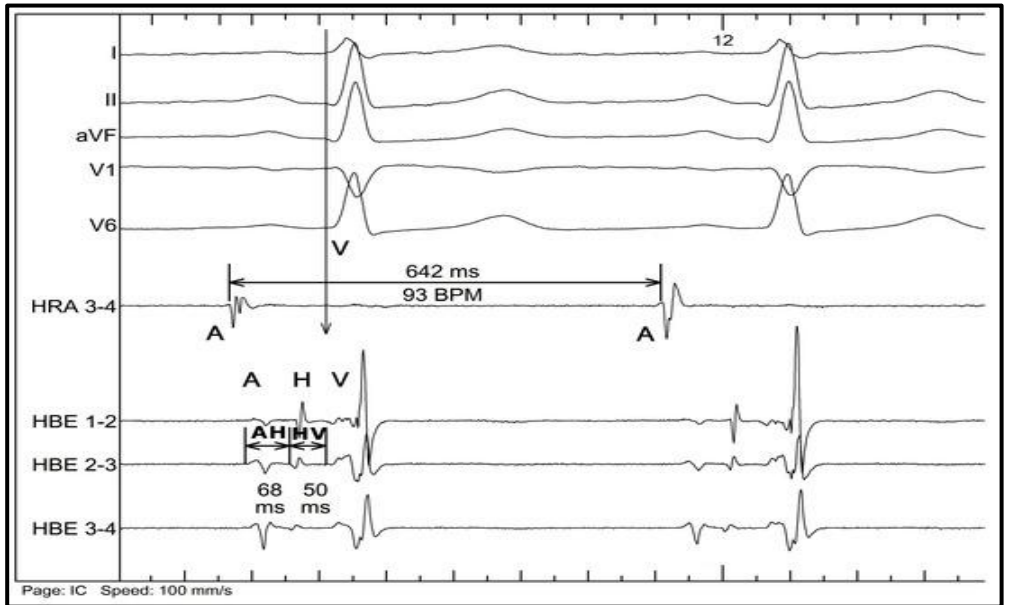
I
II
aVF
V1
V6
12
V
642 ms
93 BPM
HRA 3-4
A
A
A H V
HBE 1-2
AH HV
HBE 2-3
68 ms
50 ms
HBE 3-4
Page: IC Speed: 100 mm/s

Pacemaker ????

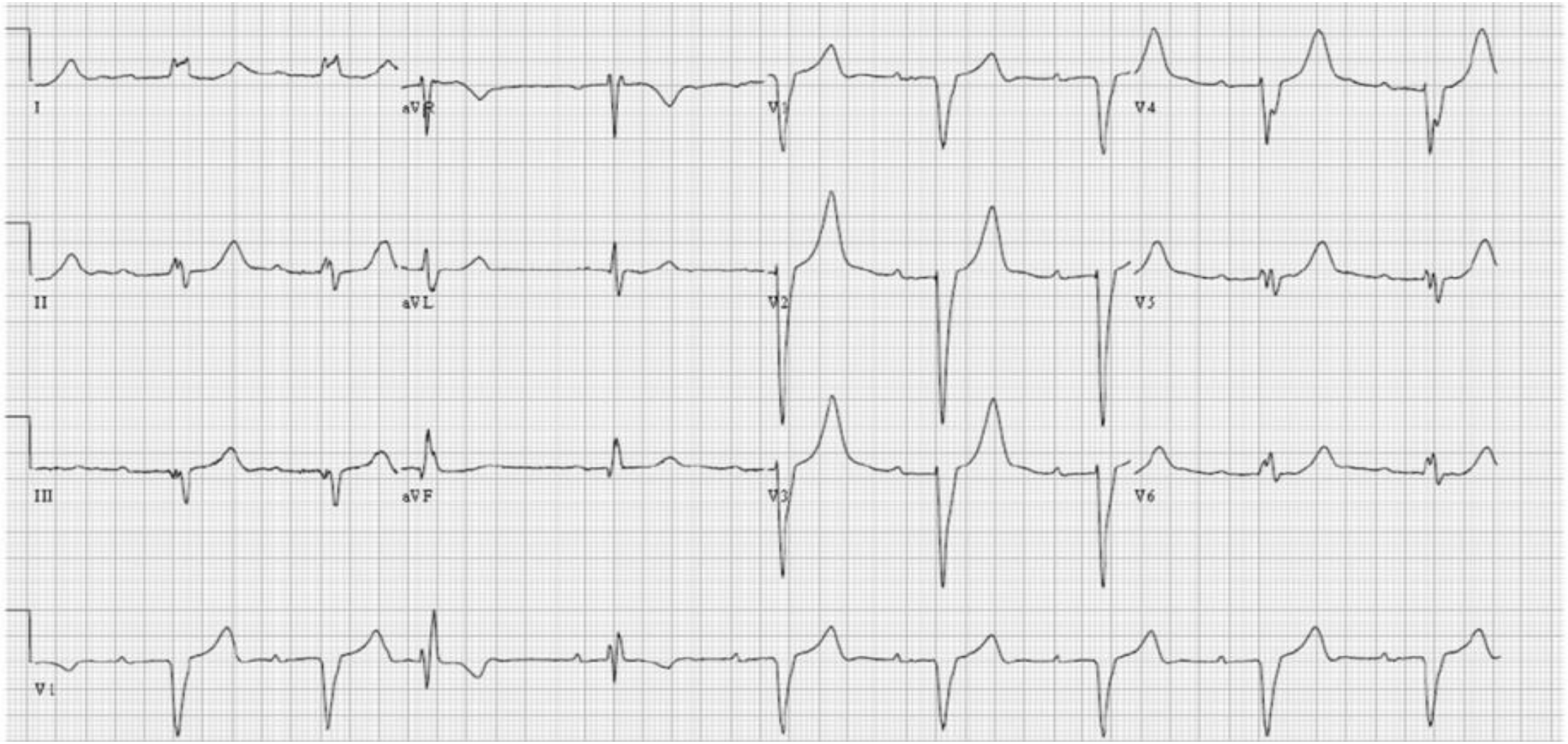

What is the diagnosis?

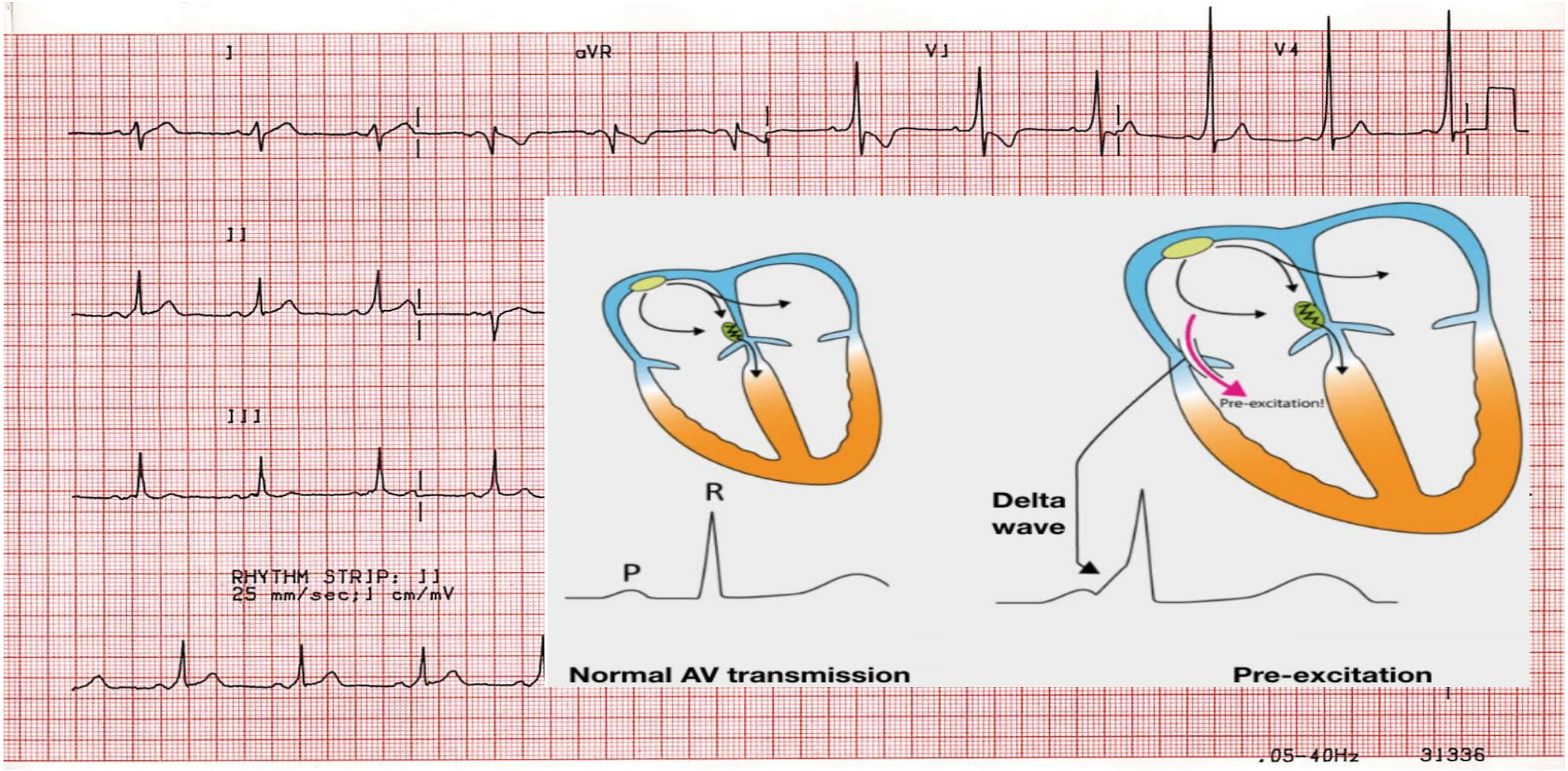

QRS Complex

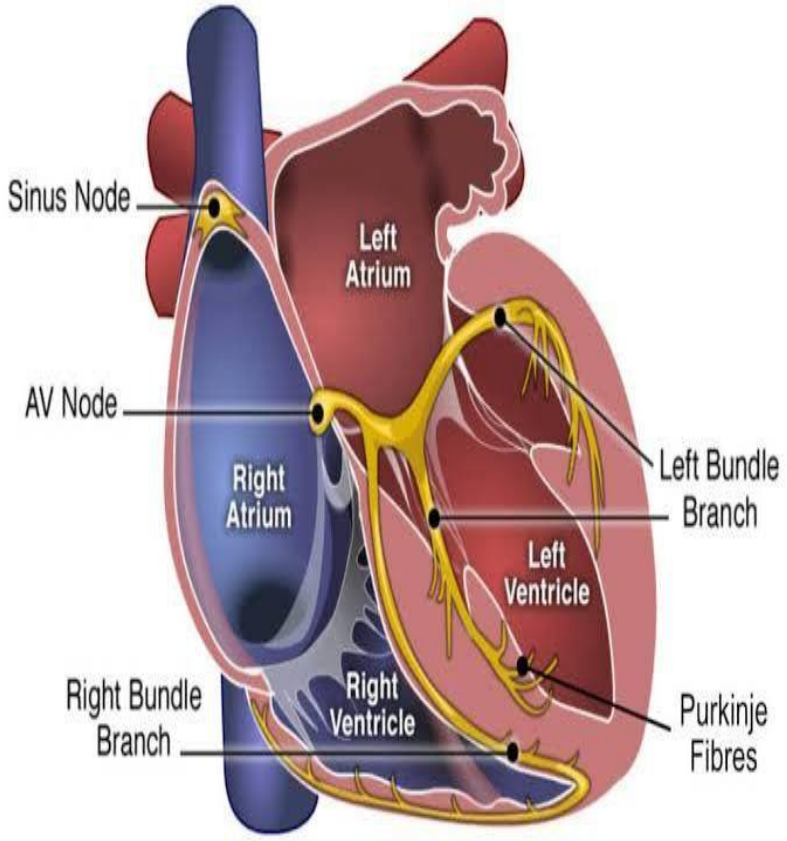

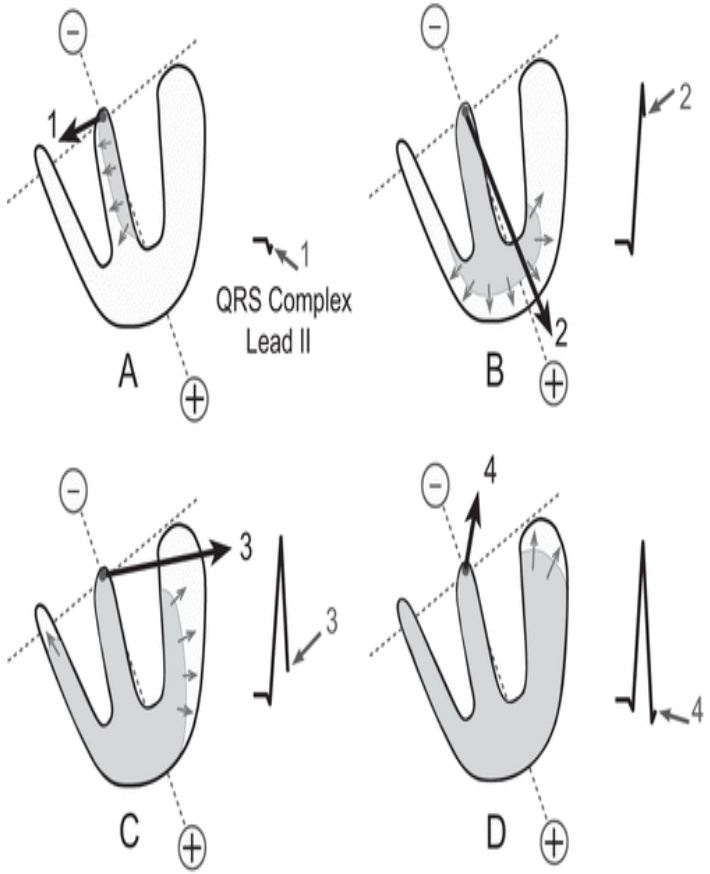

- Normal QRS < 0.12 ms (3 small boxes)
- Conduction system exit is in middle of the Heart

QRS Complex Nomenclature

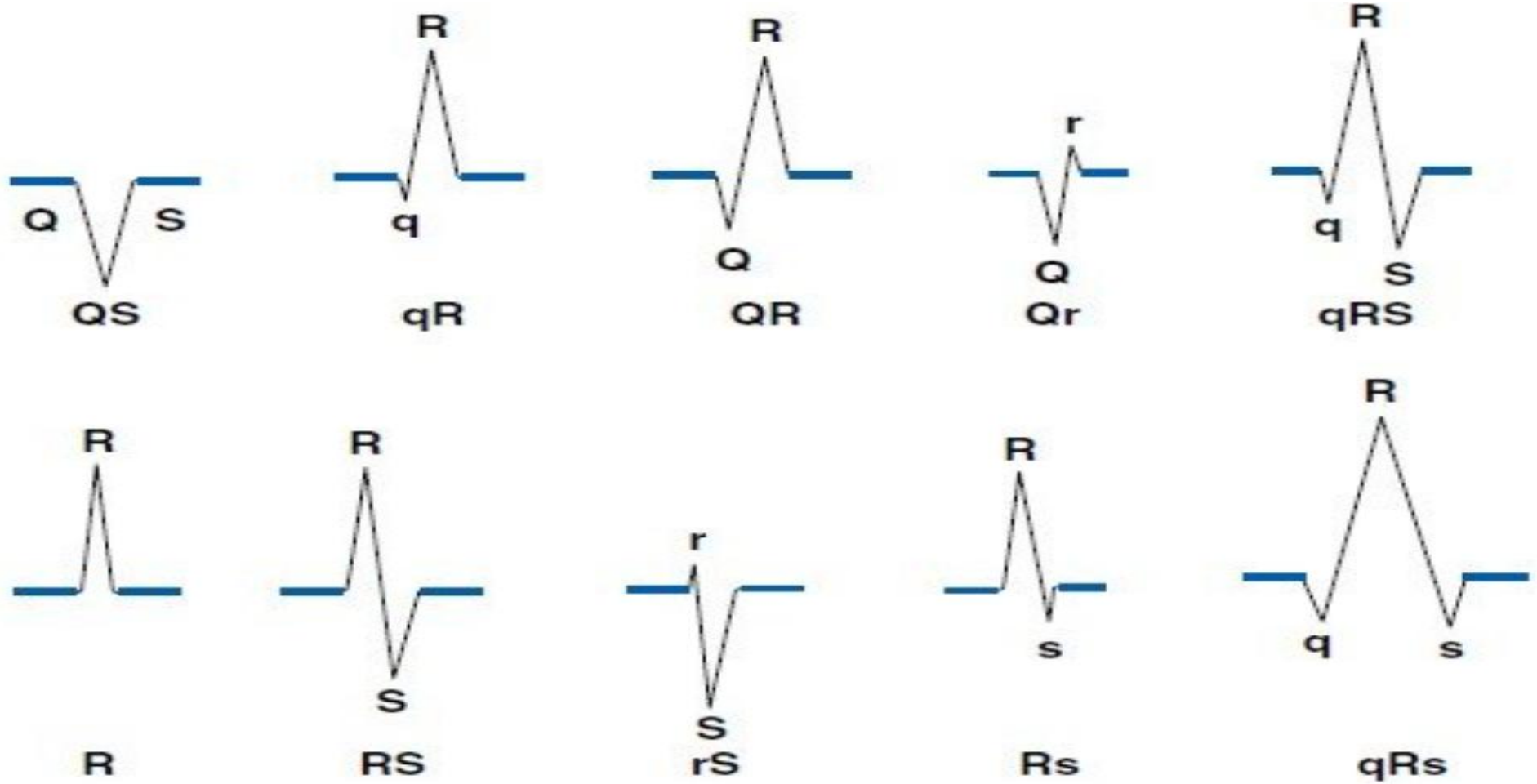

Mechanisms of Ventricular Activation

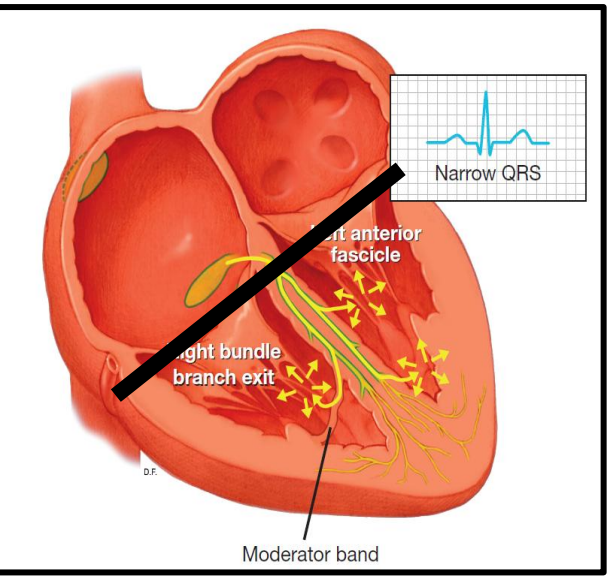

His-Purkinje

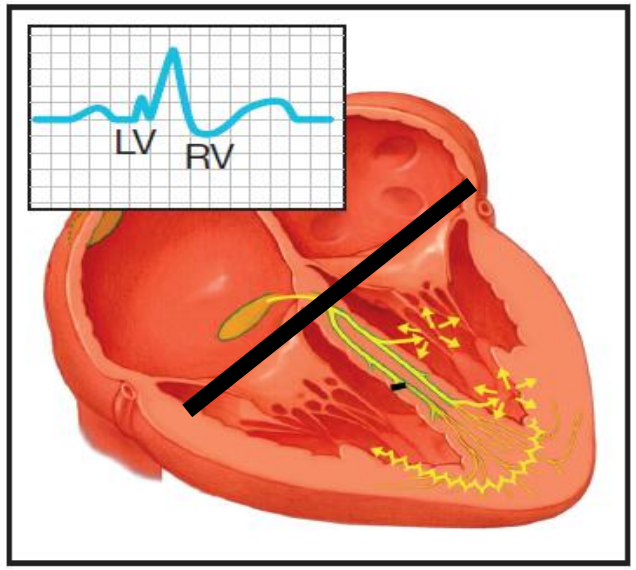

Aberancy

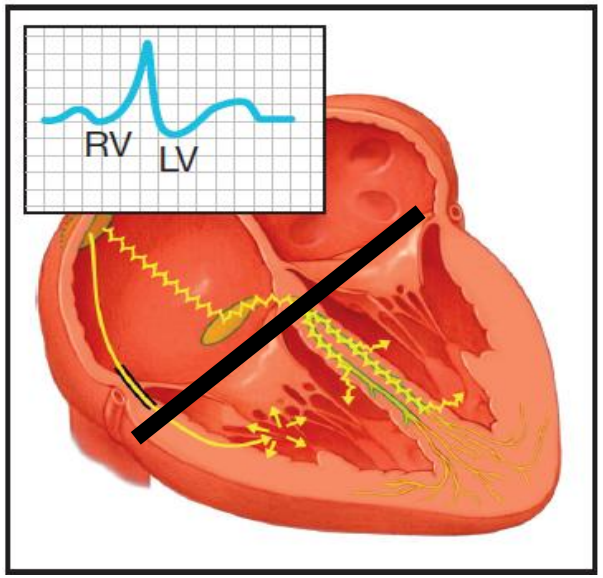

Preexcitation

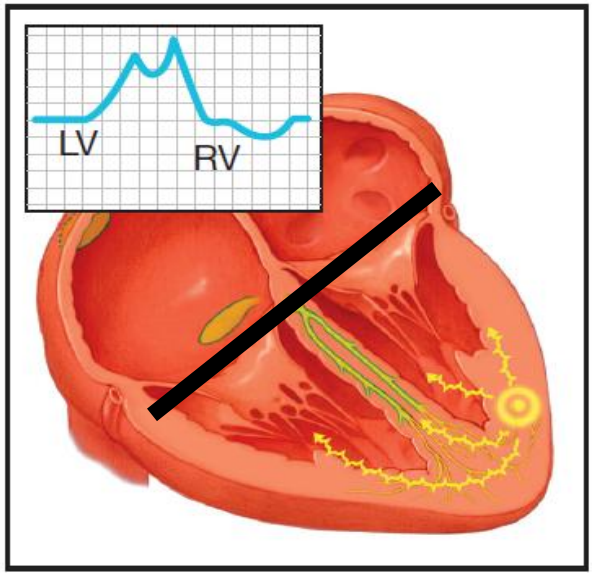

Myocardial Conduction

What is the diagnosis?

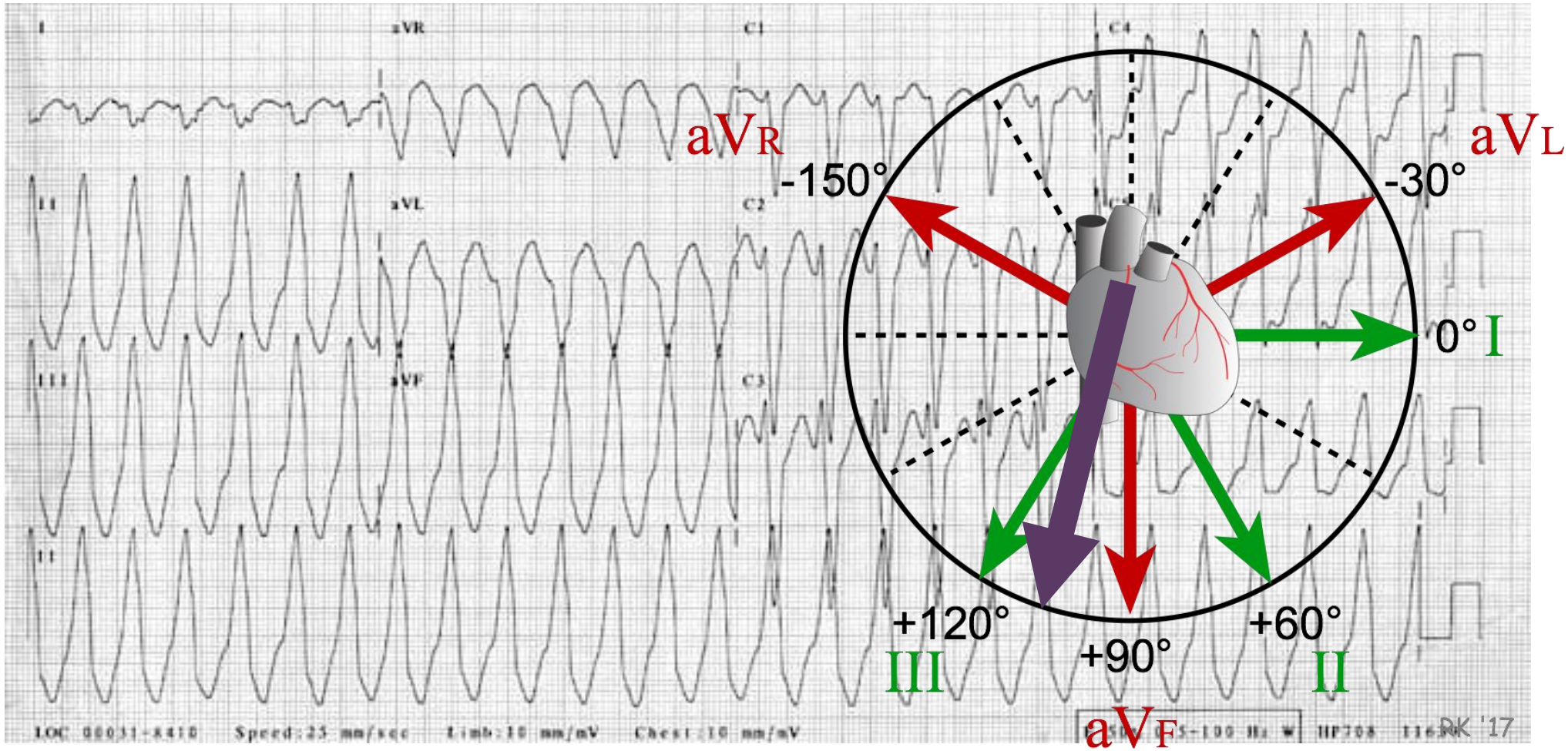

What is the diagnosis?

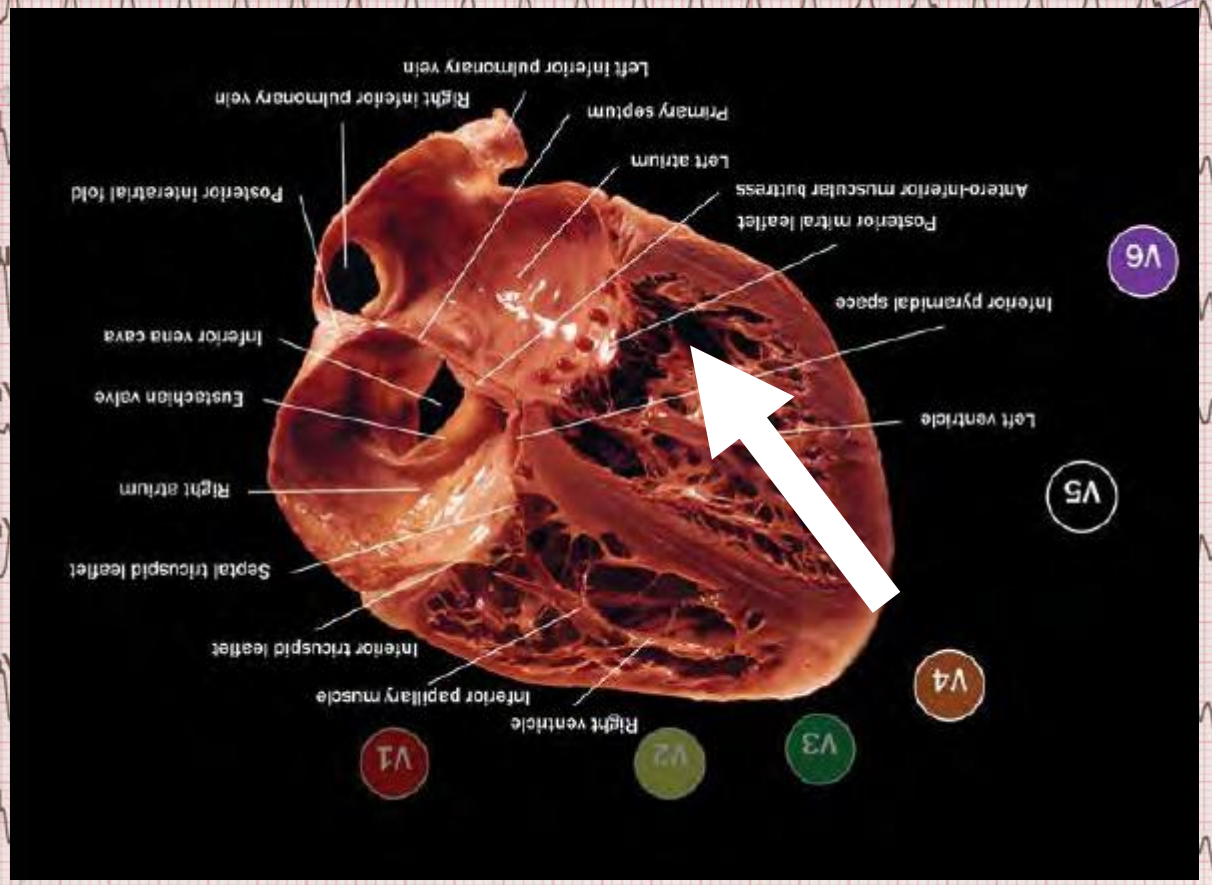

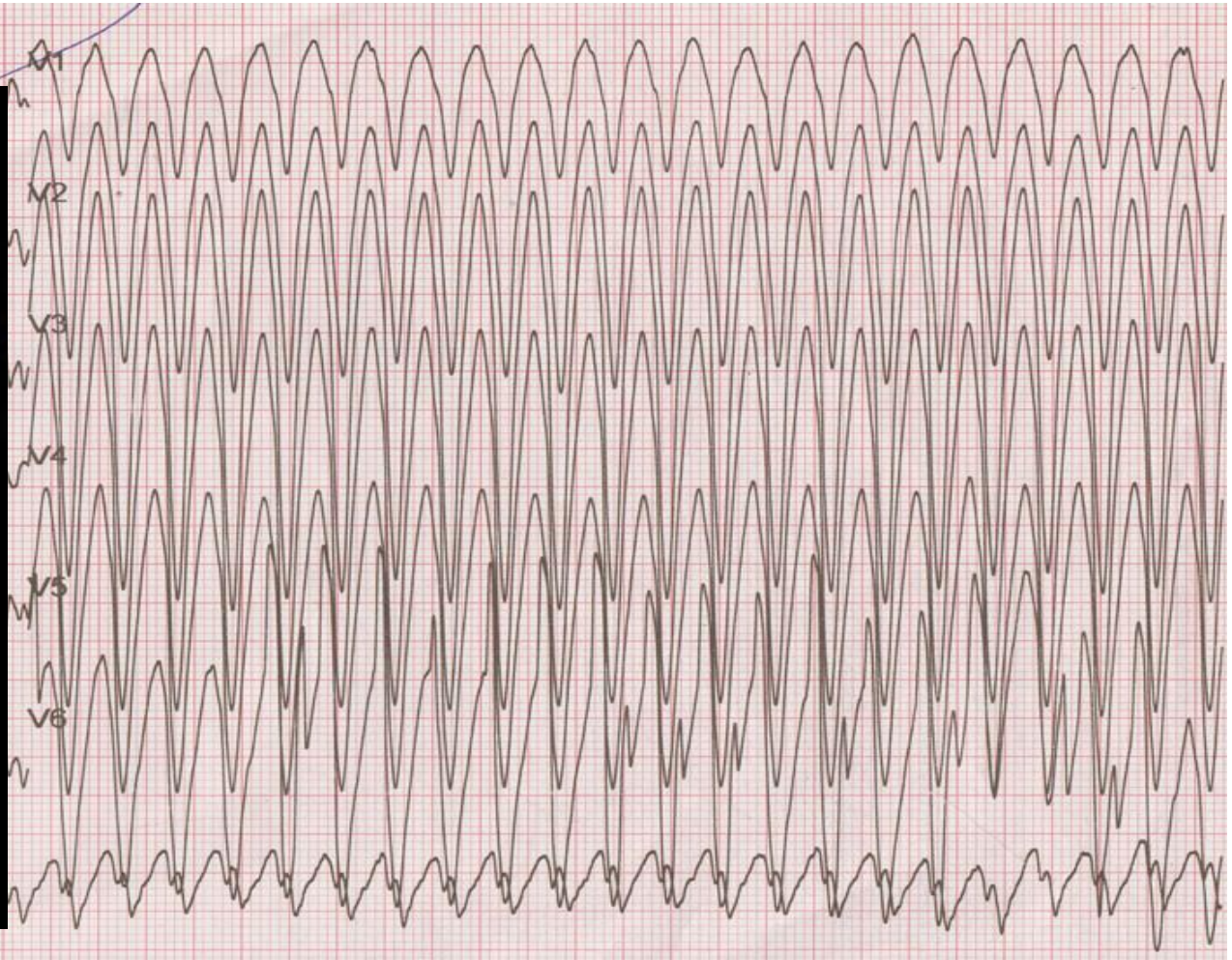

Unconfirmed

GE MAC2000 1.1 12SL™ v241 25 mm/s 10 mm/mV ADS 0.56-40 Hz 50 Hz 2x5x6_25_R1

ST Segment

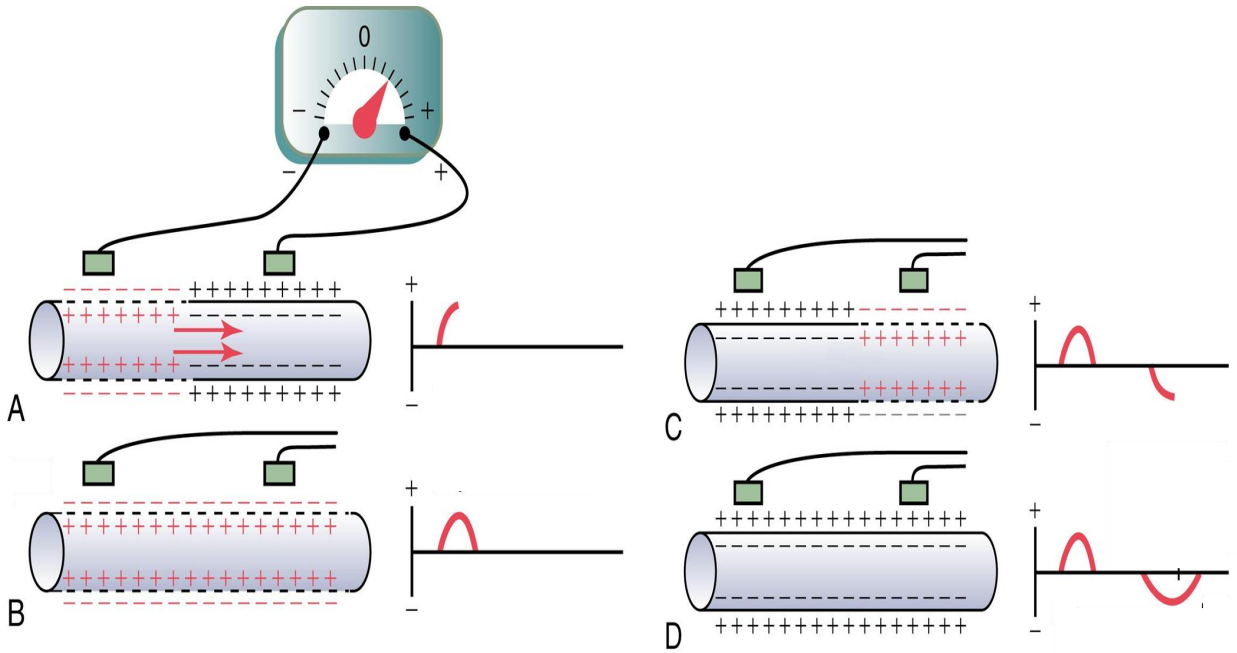
0
A
B
C
D

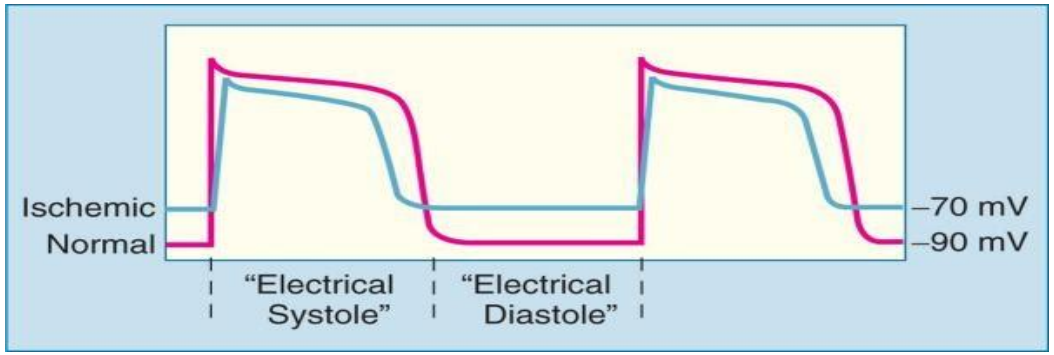
Ischemic
Normal
–70 mV
–90 mV
"Electrical Systole"
"Electrical Diastole"


QRS
P
T
QT interval "electrical systole"
TQ segment "electrical diastole"

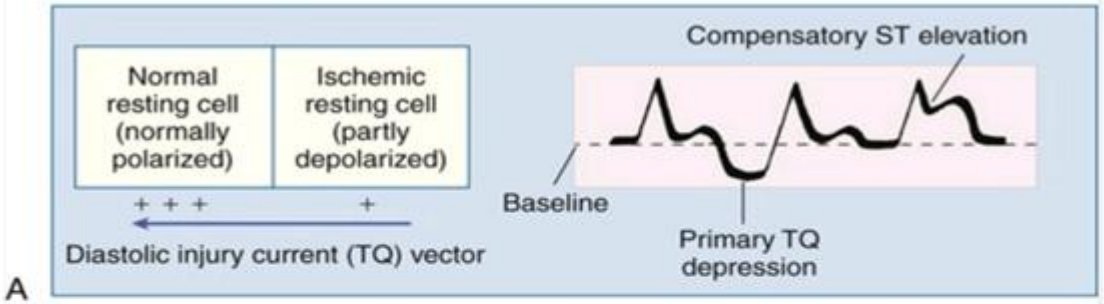
A
Normal resting cell (normally polarized)
Ischemic resting cell (partly depolarized)
Diastolic injury current (TQ) vector
Compensatory ST elevation
Baseline
Primary TQ depression

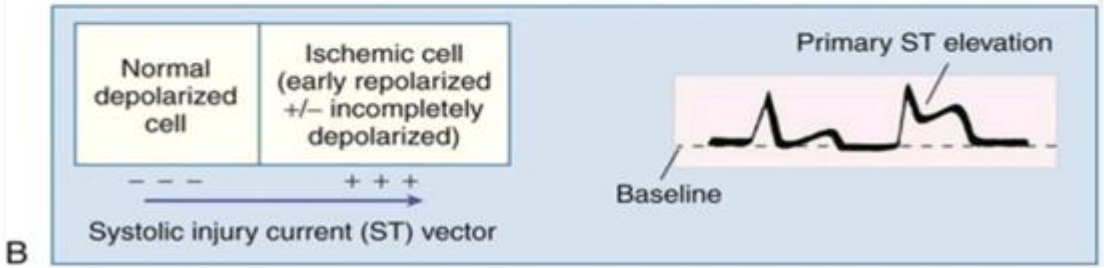
B
Normal depolarized cell
Ischemic cell (early repolarized +/– incompletely depolarized)
Systolic injury current (ST) vector
Primary ST elevation
Baseline

What is the diagnosis?

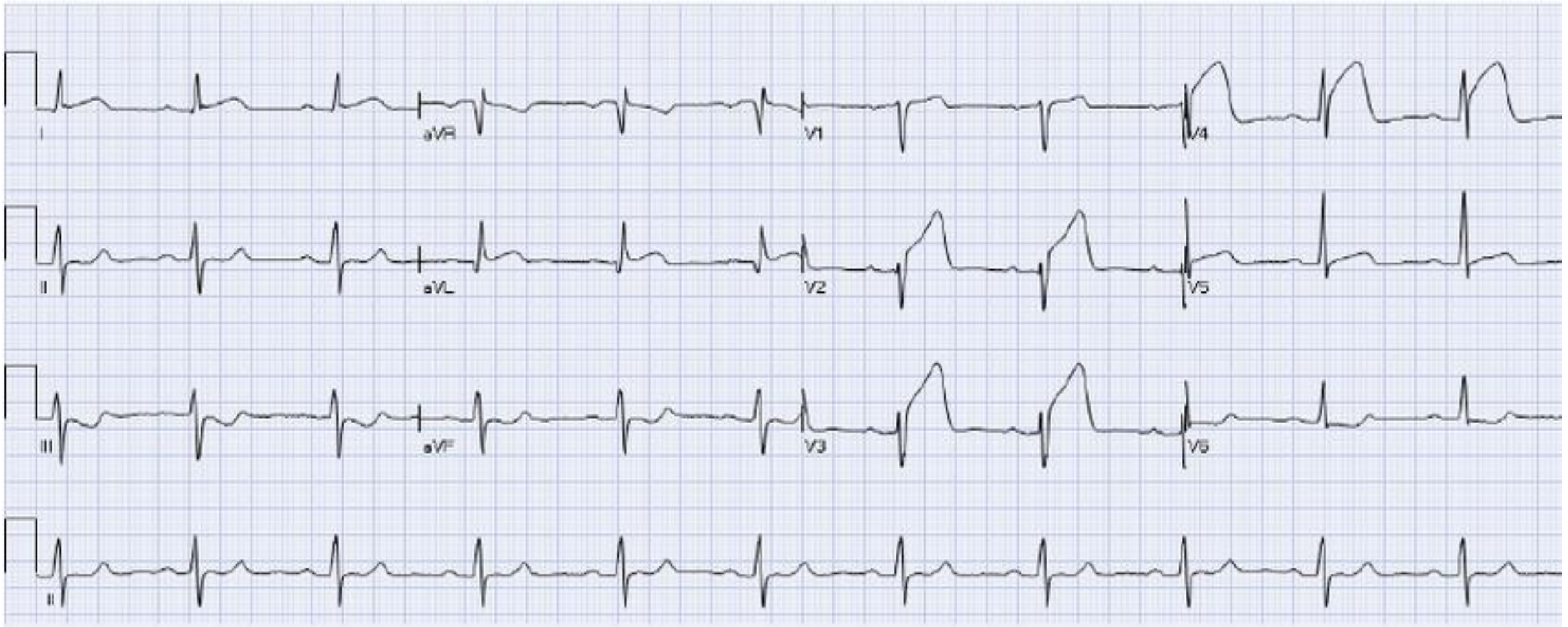

QT Interval

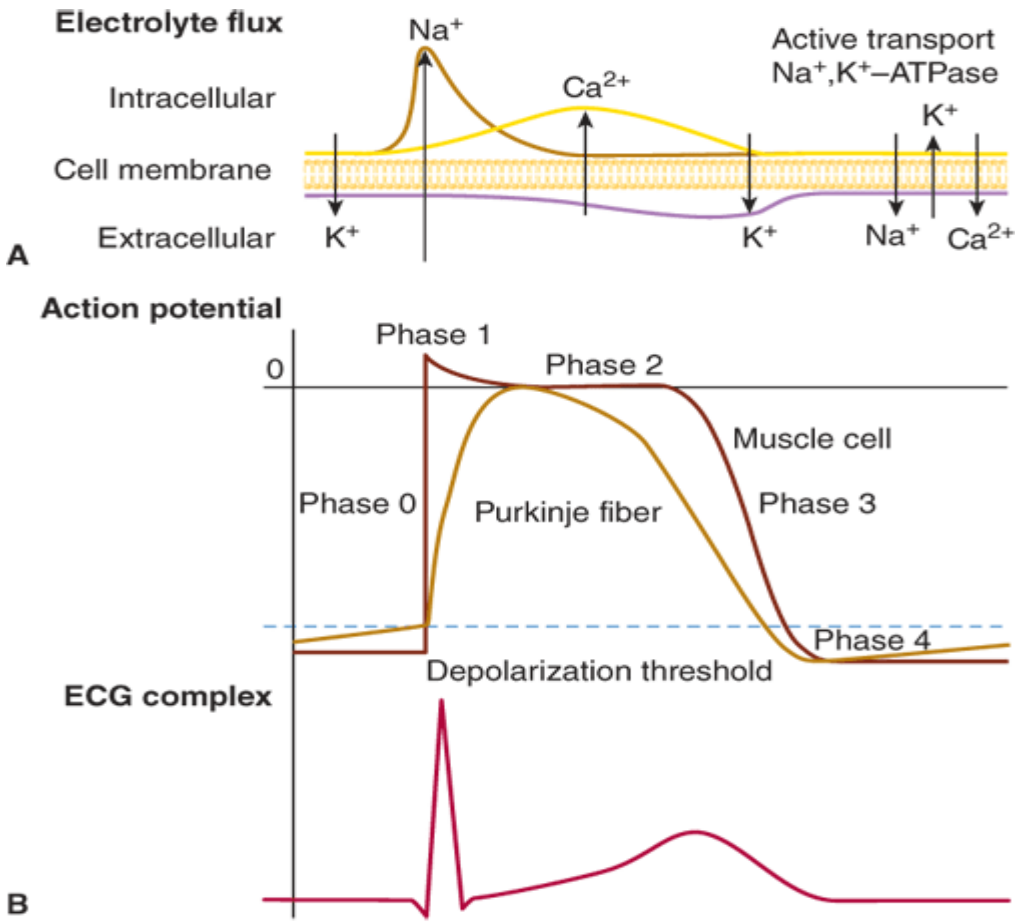

Source: L.S. Nelson, M.A. Howland, N.A. Lewin, S.W. Smith, L.R. Goldfrank, R.S. Hoffman: Goldfrank's Toxicologic Emergencies, Eleventh Edition
Copyright © McGraw-Hill Education. All rights reserved.

- Action potential duration
- Too long or too short increases the risk for arrythmia

T wave

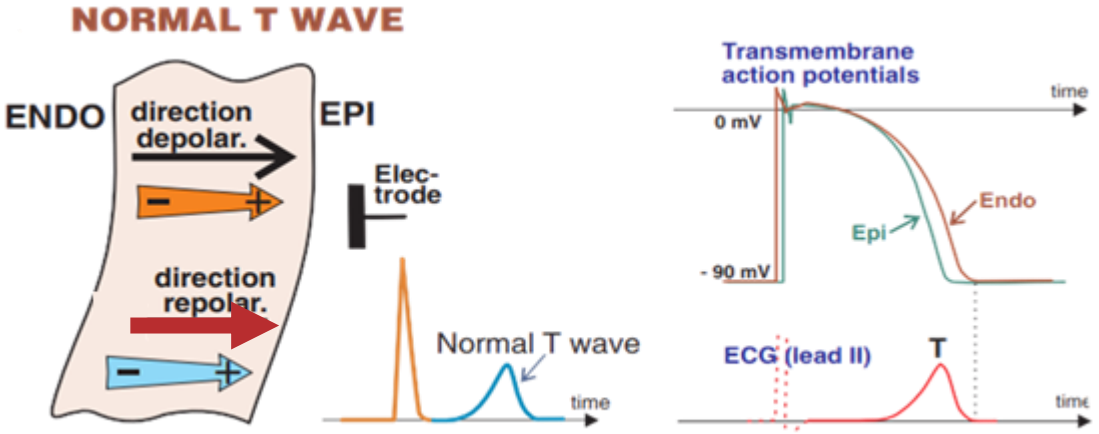

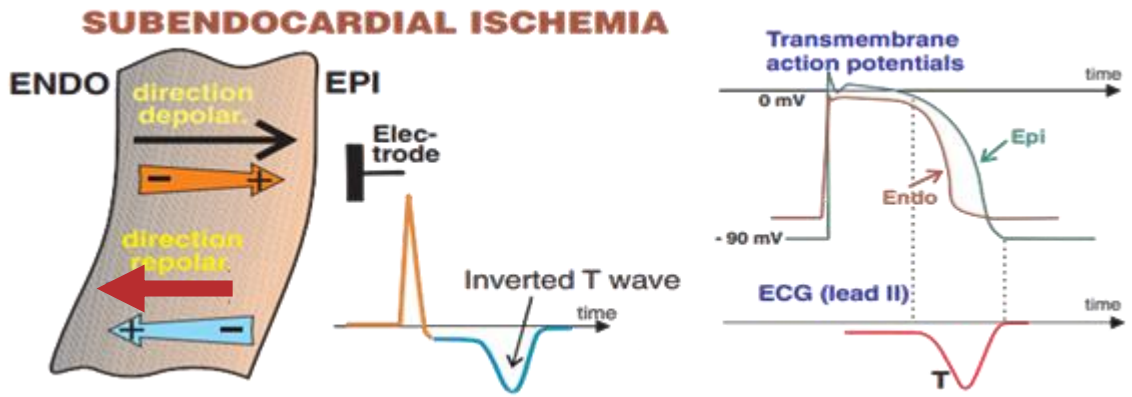

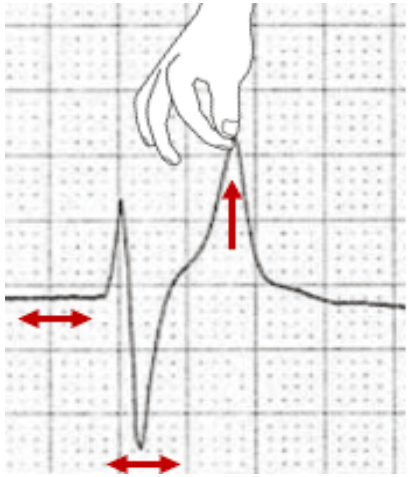

Hyperkalaemia

Peaked T waves
P wave flattening
PR prolongation
Wide QRS complex

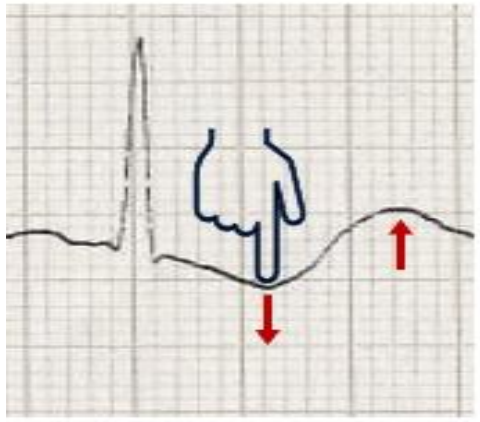

Hypokalaemia

T wave inversion
ST depression
Prominent U wave

Conclusion

- ECG records electrical activity as vectors
- Although ECG records electricity, many heart diseases alter electrical signals. Structural and functional problems - such as myocardial infarction, ischemia, chamber hypertrophy, electrolite imbalance - produce characteristic electrical changes that can be detected on ECG.



Thank you for staying tachycardic with excitement until the end !!!