Miscellaneous ECG

The ECG in the Broader Picture

Lim Ai Ni
Cardiovascular Technician, HSIS

MVA → Unconcious

Pupil unequal





ECG - Intracranial Pressure Raised

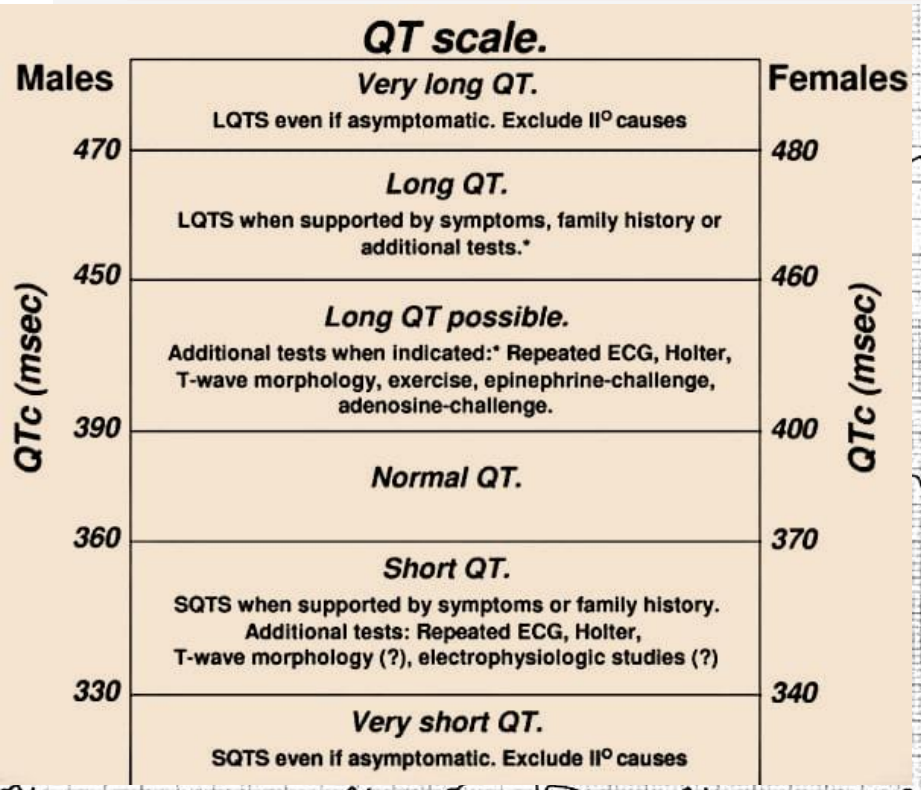

Giant T-wave inversions (“cerebral T waves)

QT interval is grossly prolonged

(600ms)



Other characteristics of ICP ↑

Bradycardia
♣The Cushing reflex – indicates imminent brainstem herniation)

ST segment elevation/ depression
♣This may mimic myocardial ischaemia or pericarditis

Increased U-wave amplitude

Other rhythm disturbances:
♣Sinus Tachycardia
♣Junctional rhythms
♣Premature ventricular contractions
♣Atrial fibrillation



Causes

Subarachnoid haemorrahge

Intraparenchymal haemorrhage (Haemorrhagic stroke)

Massive ischaemic stroke causing cerebral oedema

Traumatic brain injury

Cerebral metastases (rarely)

Cerebral T-waves with prolonged QT interval	
SAH	72%
Intraparenchymal haemorrhage	57%

Intracranial Pressure Raised

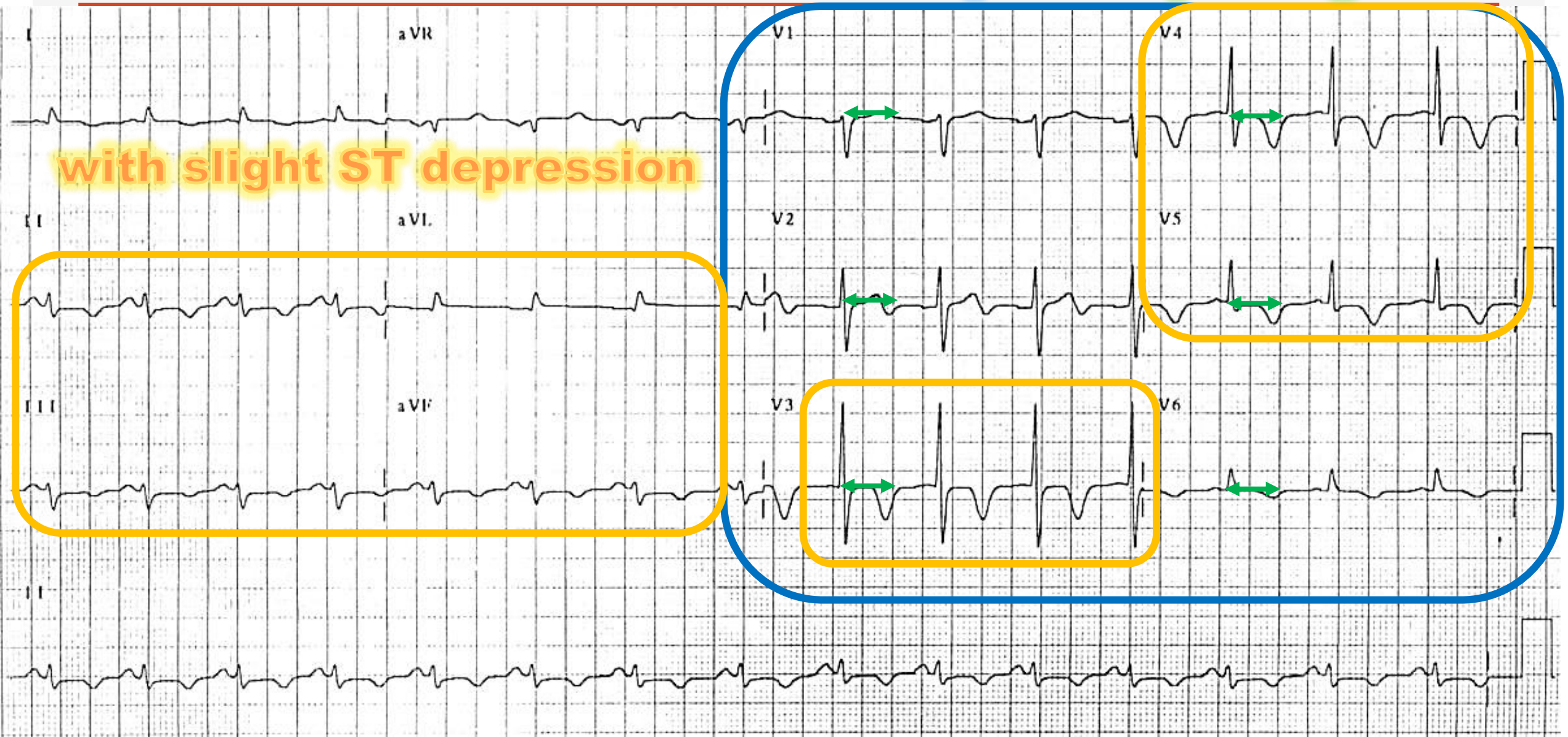

Intracranial Pressure Raised

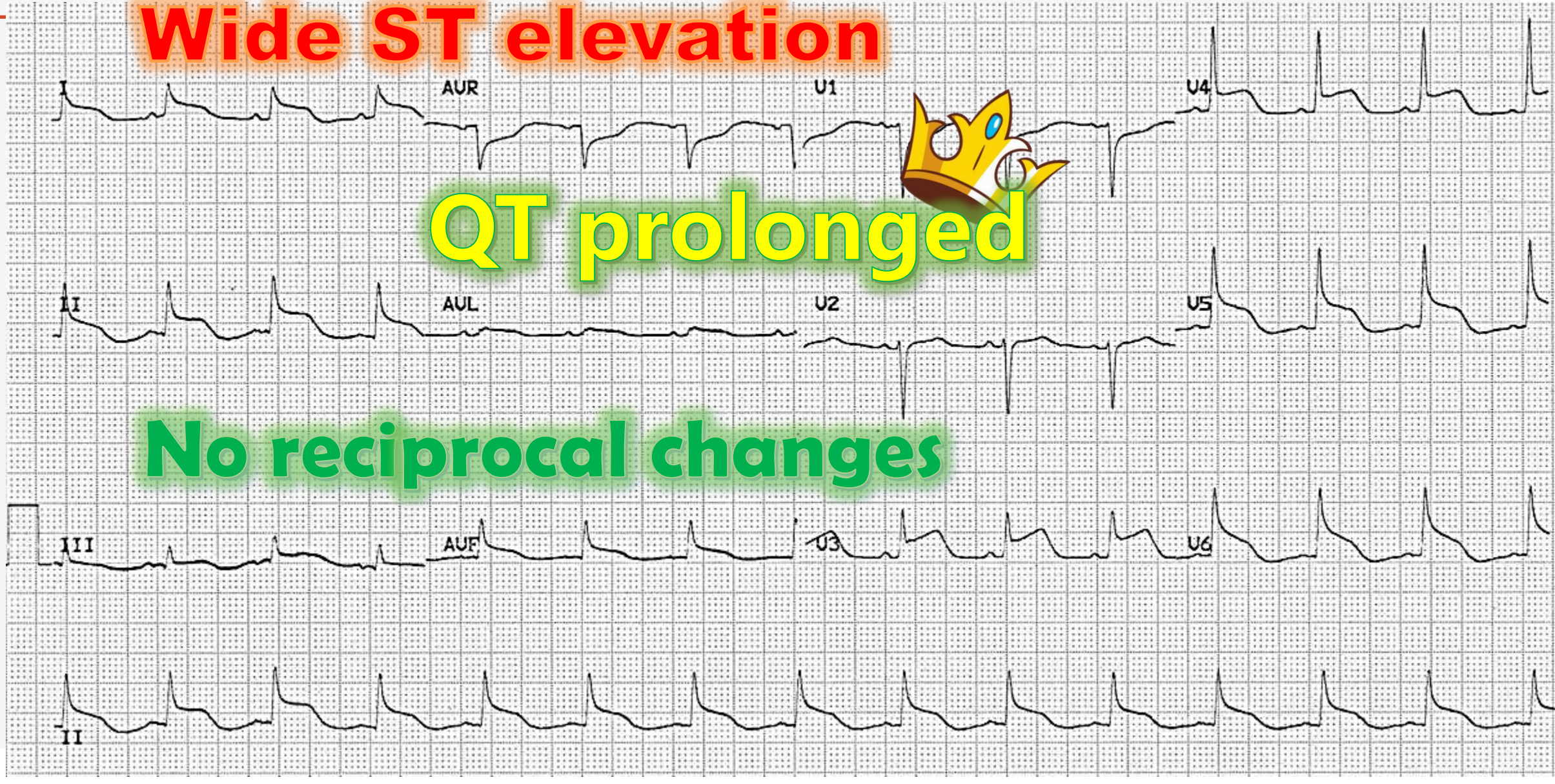

PARKINSON'S DISEASE





Deep Brain Stimulator

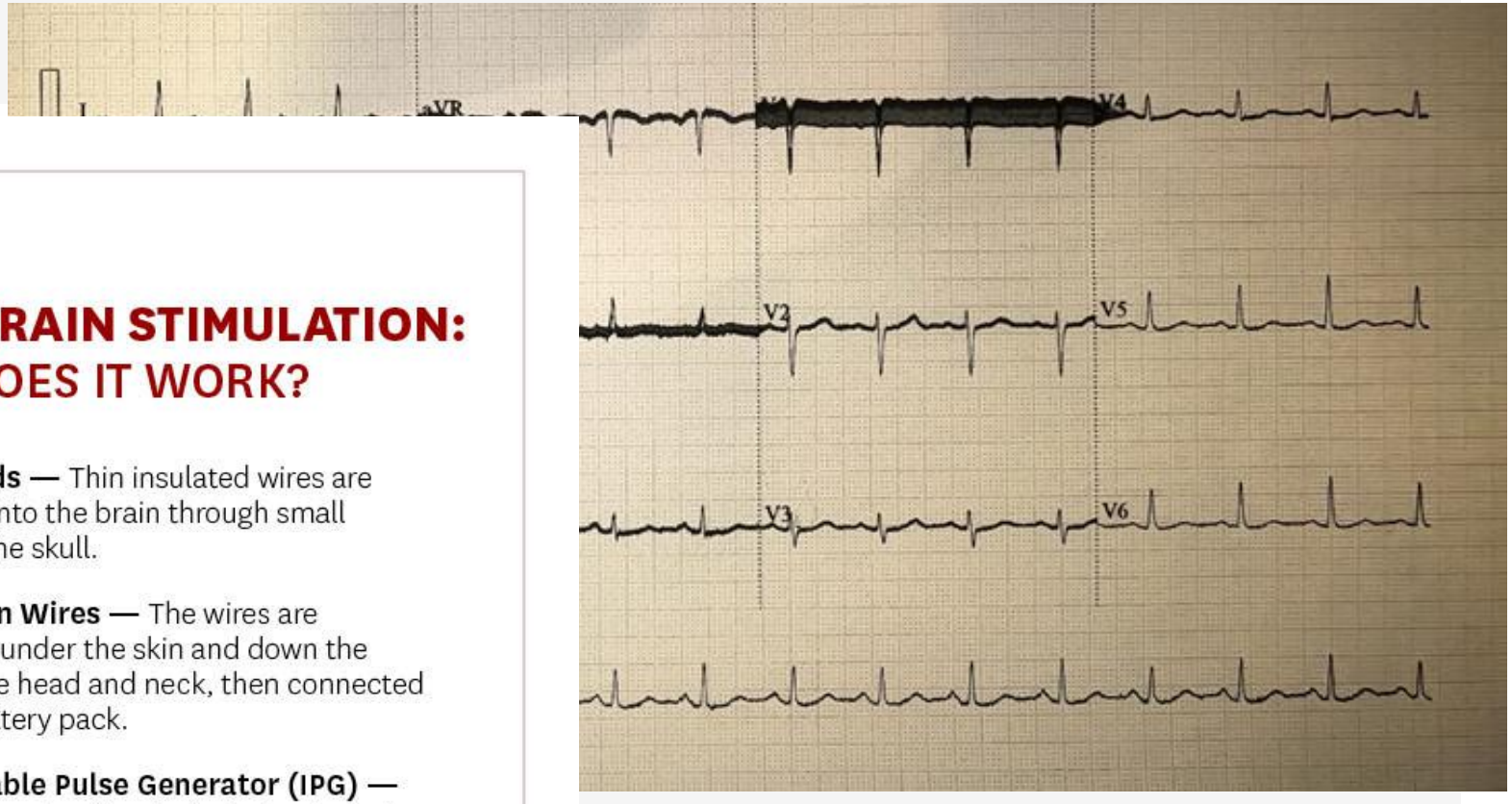

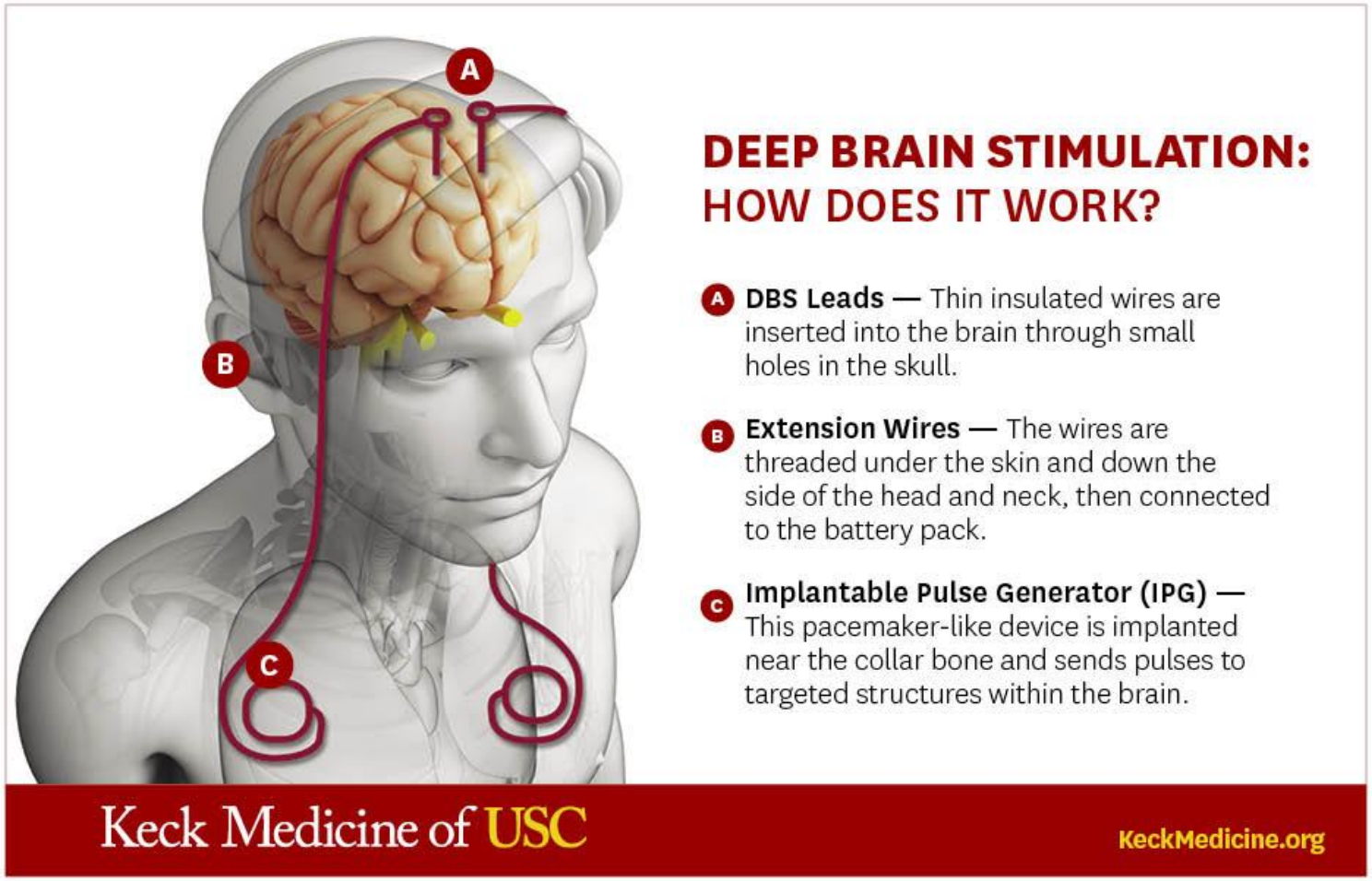

Deep Brain Stimulator

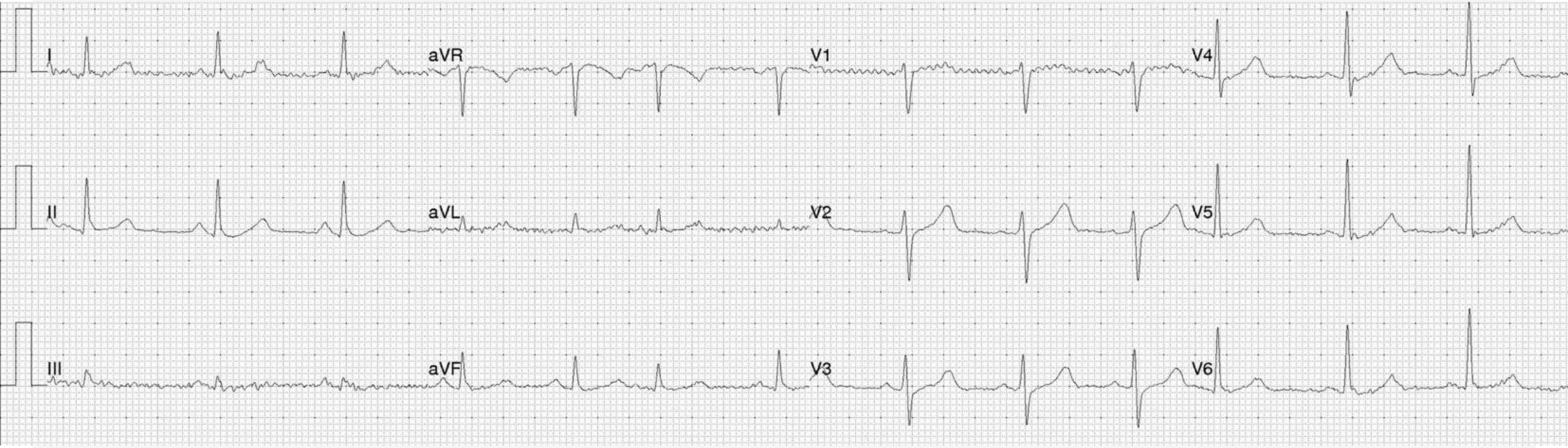

A 12-lead ECG exhibiting sinus rhythm and high-frequency artifact (**most notable in lead V_1**) typically seen with deep brain stimulator in situ.

Deep Brain Stimulator



A: Low-frequency "flutter" artifact is visualized while deep brain stimulator (DBS) is on. **B:** Loss of "flutter" artifact is exhibited when DBS is turned off. **C:** For this tracing, the artifact is superimposed on an unrelated patient with actual typical atrial flutter to demonstrate the surprising similarity between the DBS-induced artifact and true clinical atrial flutter.

Deep Brain Stimulator

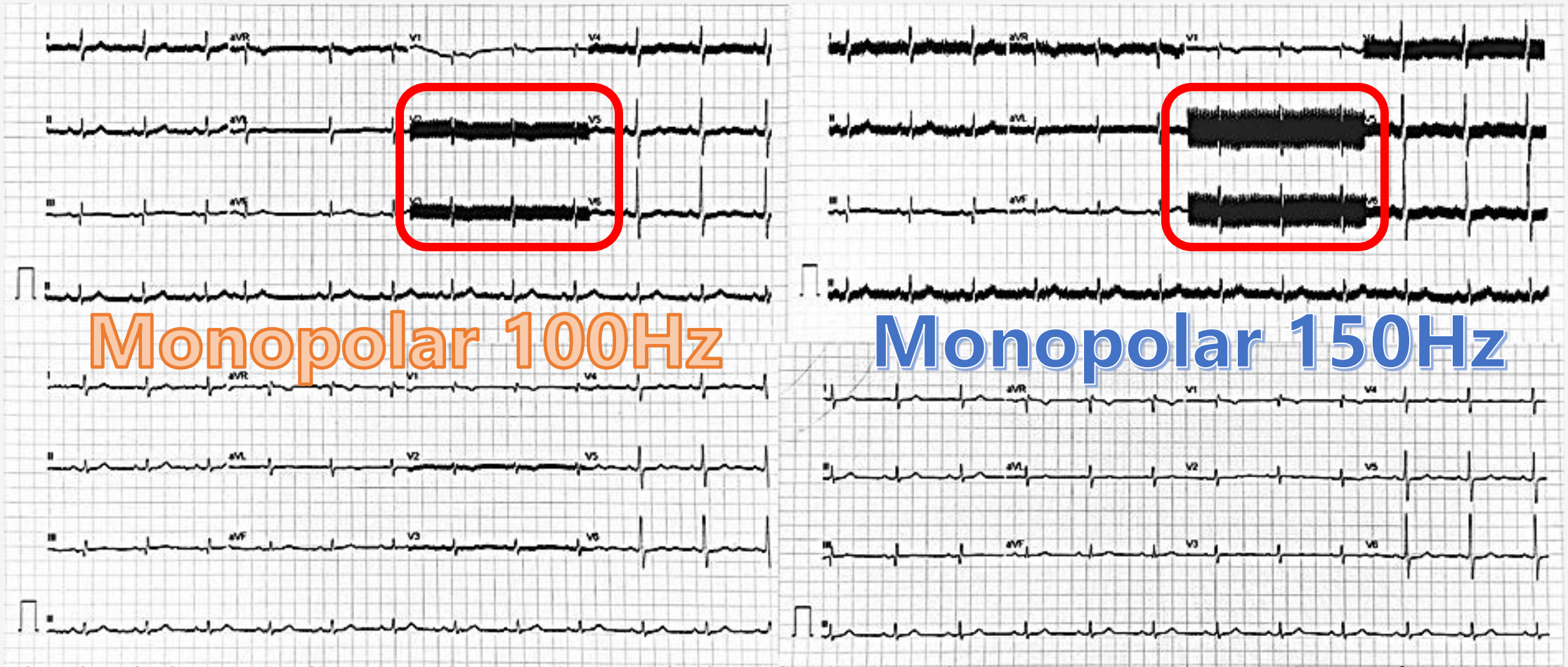

Twelve-lead electrocardiograms in a patient with deep brain stimulation (DBS) in monopolar configuration at 159 Hz: Left image: monopolar at 100 Hz, an artifact affecting all leads is observable, with V2-V4 showing more pronounced effects. Right image: monopolar with a 150 Hz filter, as the filter is close to the DBS stimulation frequency, the artifact becomes markedly more conspicuous.

Ventricular Tachycardia or Artifact?

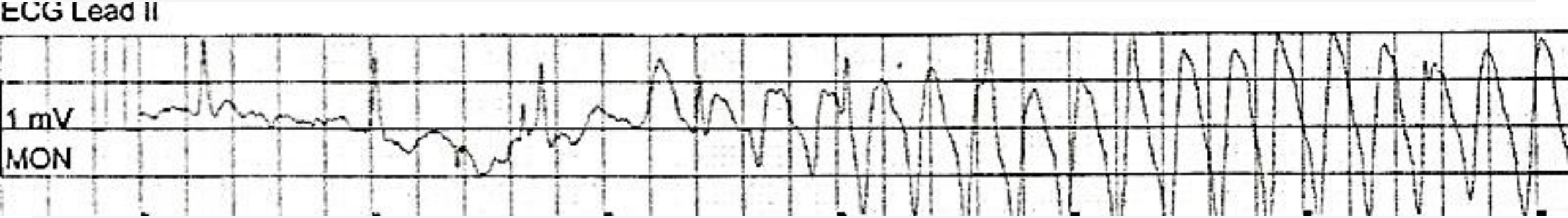



Shock or No Shock?

Ventricular Tachycardia?

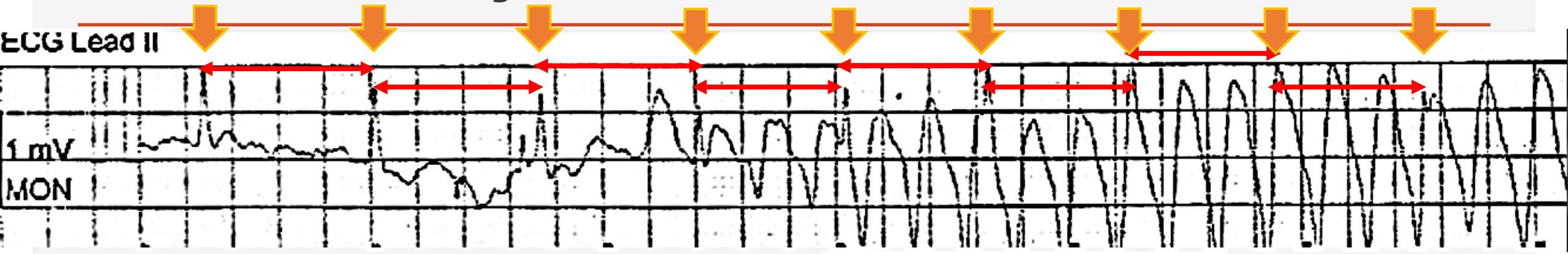

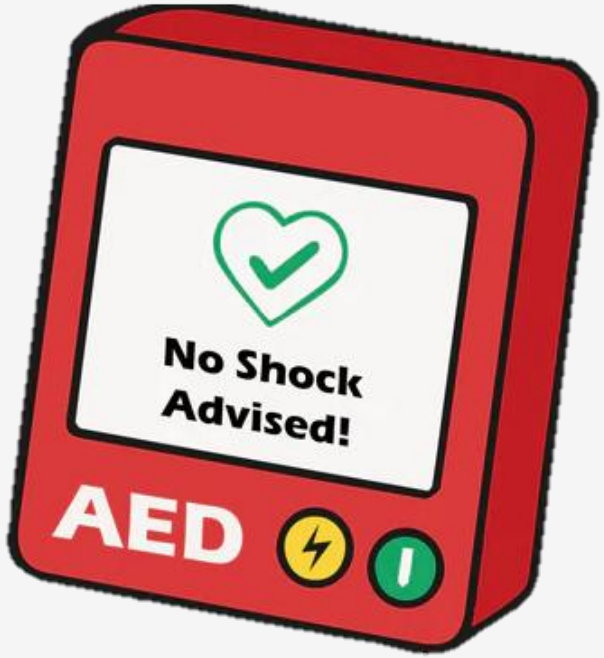



Criteria of Ventricular Tachycardia

1. Very broad complexes (>160ms)
2. Absence of typical RBBB or LBBB morphology
3. Extreme Axis deviation (“Northwest axis)



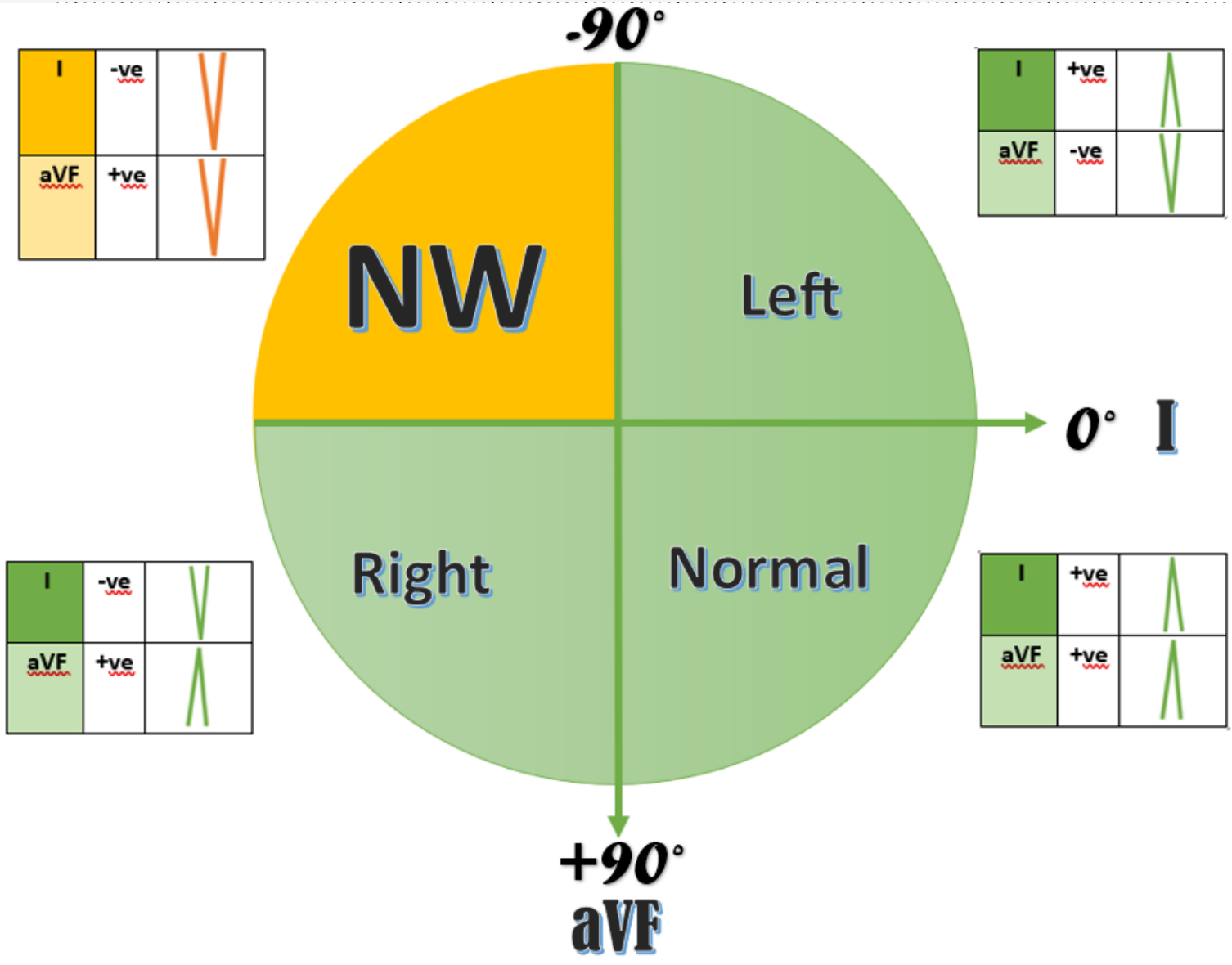

Criteria of Ventricular Tachycardia

4. AV dissociation (P and QRS complexes at different rates)

5. Capture beats – Occur when the SA node transiently "captures" the ventricles, in the midst of AV dissociation, to produce a QRS complex or normal duration

6. Fusion beats – Occur when a sinus and ventricular beat coincide to produce a hybrid complex of intermediate morphology

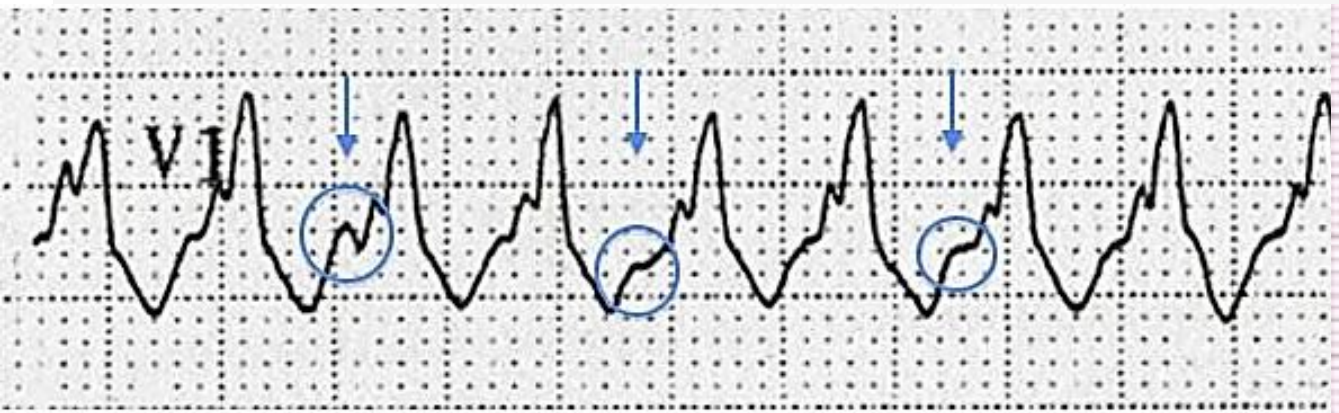

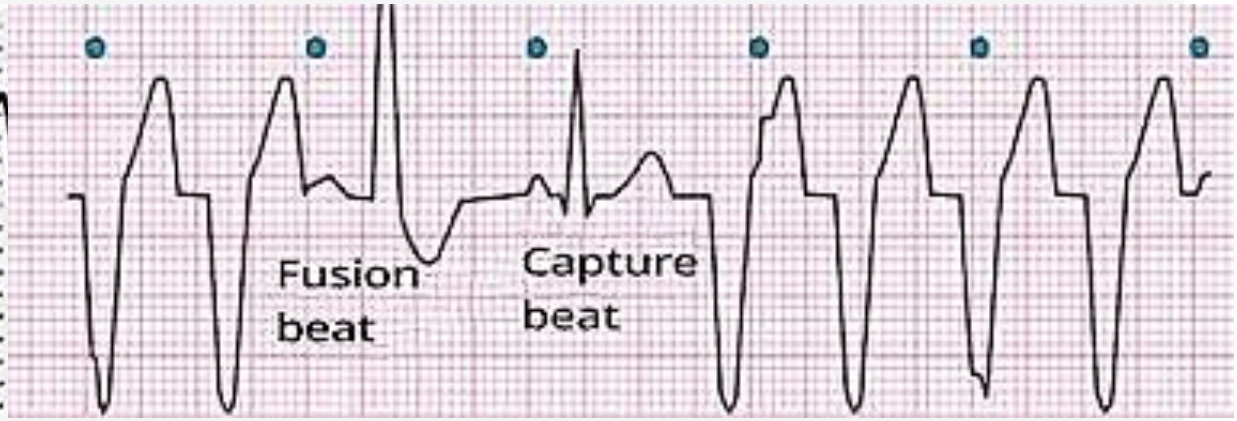

Fusion beat: The QRS complex is wide and appears as something between the ventricular beats and the normal beats
Capture beats: These beats are presumably supraventricular beats that managed to get through and depolarize the ventricles

Criteria of Ventricular Tachycardia

7. +ve or –ve concordance throughout the chest leads
8. Josephson's sign – Notching near the nadir of the S-wave
9. Brugada's sign –>100ms in any precordial leads



Criteria of Ventricular Tachycardia

10. RSR' complexes with taller "Left rabbit ear", is most specific finding in favor of VT. This is in contrast to RBBB, where the right rabbit ear is taller
11. Large, upright R-wave in lead aVR during a WCT rhythm is virtually diagnostic of VT



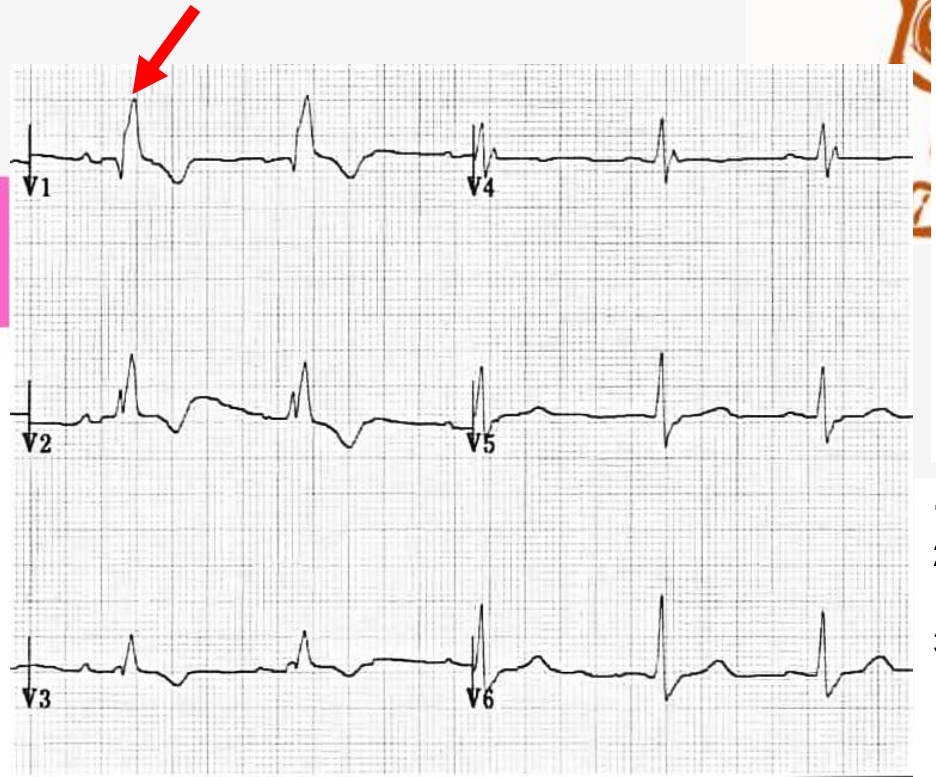

Taller ✅
Rabbit Ear



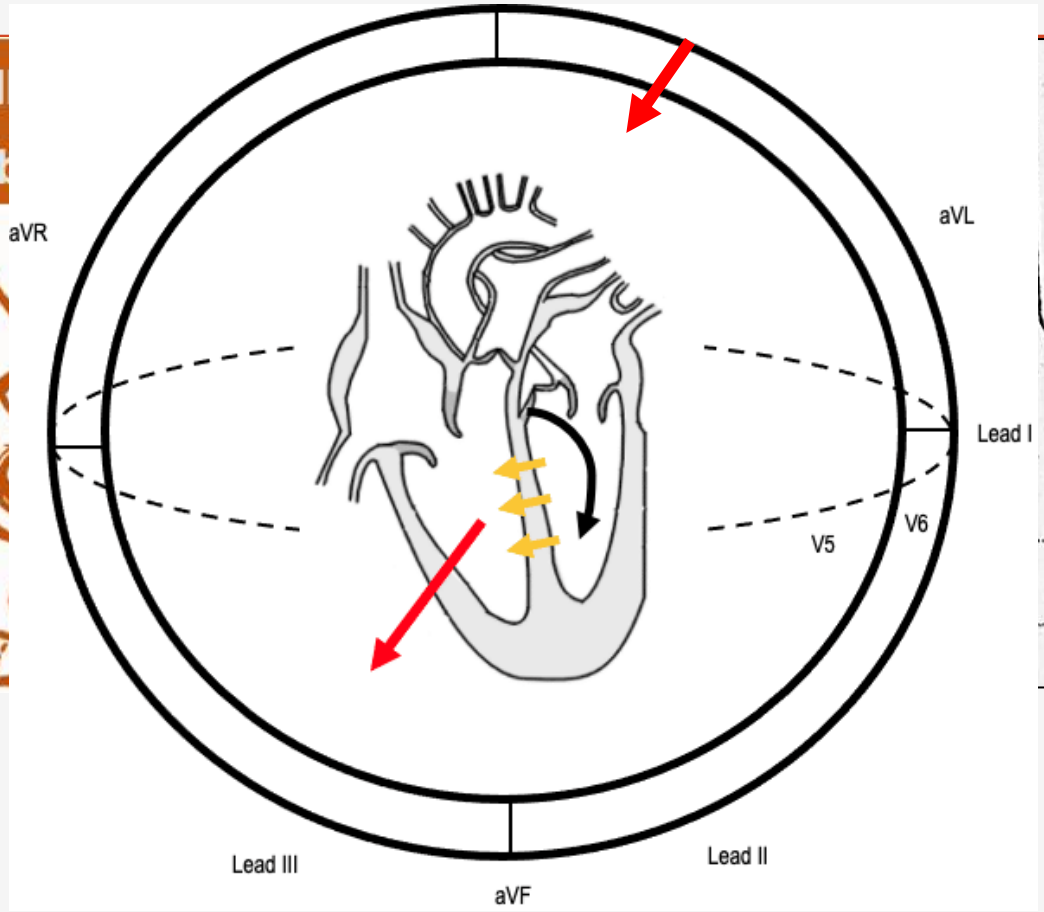



1. **LV activation via the left bundle occurs normally**
2. **Septal depolarization is thus unaffected, producing a normal early QRS complex**
3. **Activation of the RV originates across the septum. The resultant depolarization vector produces delayed R waves in lead V1-V3, and S-waves in lateral leads**

Summary of Ventricular Tachycardia

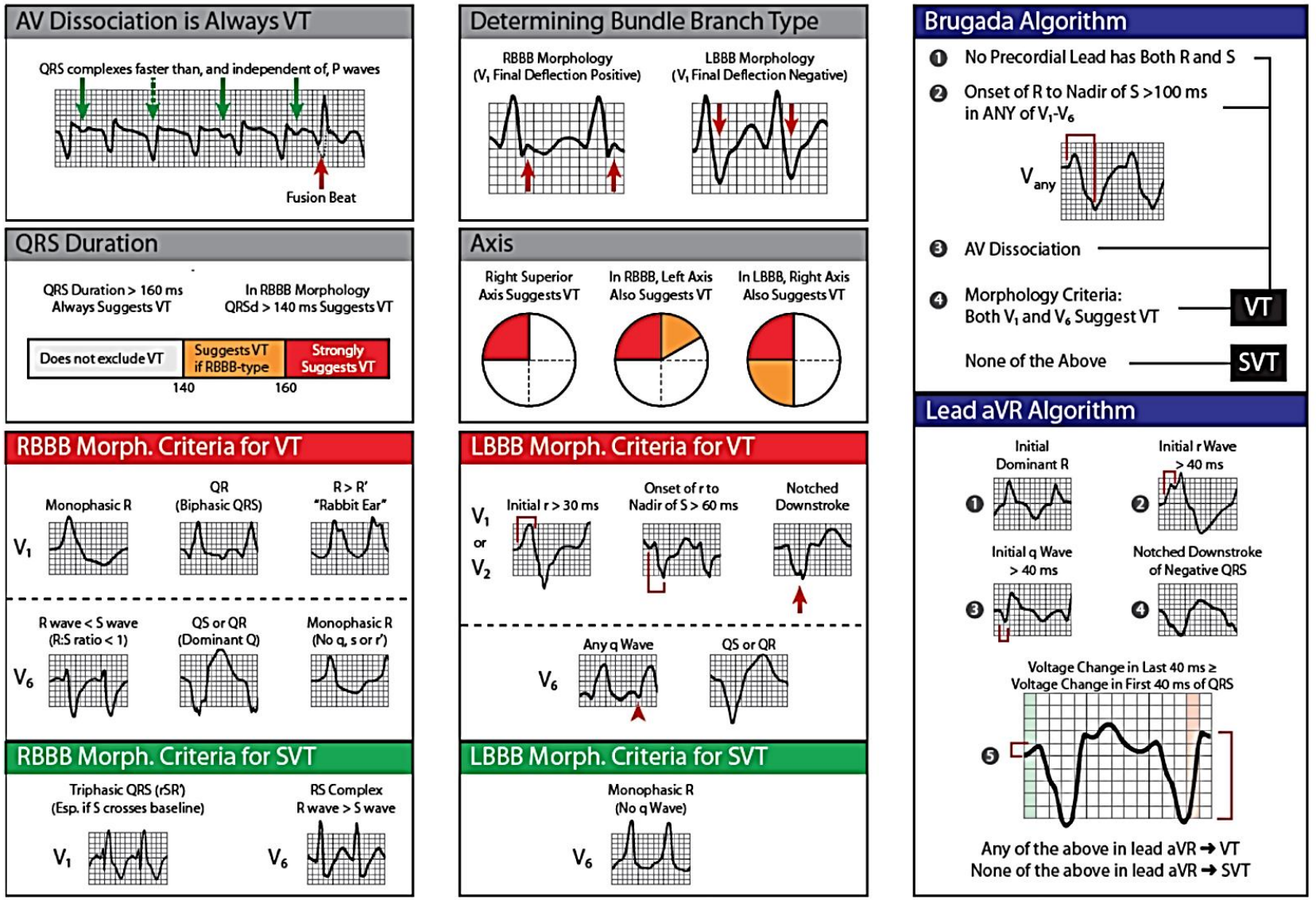

AV = atrioventricular; aVR = augmented vector right; LBBB = left bundle branch block; RBBB = right bundle branch block; SVT = supraventricular tachycardia; VT = ventricular tachycardia.

Arrhythmogenic Right Ventricular Dysplasia (ARVD)

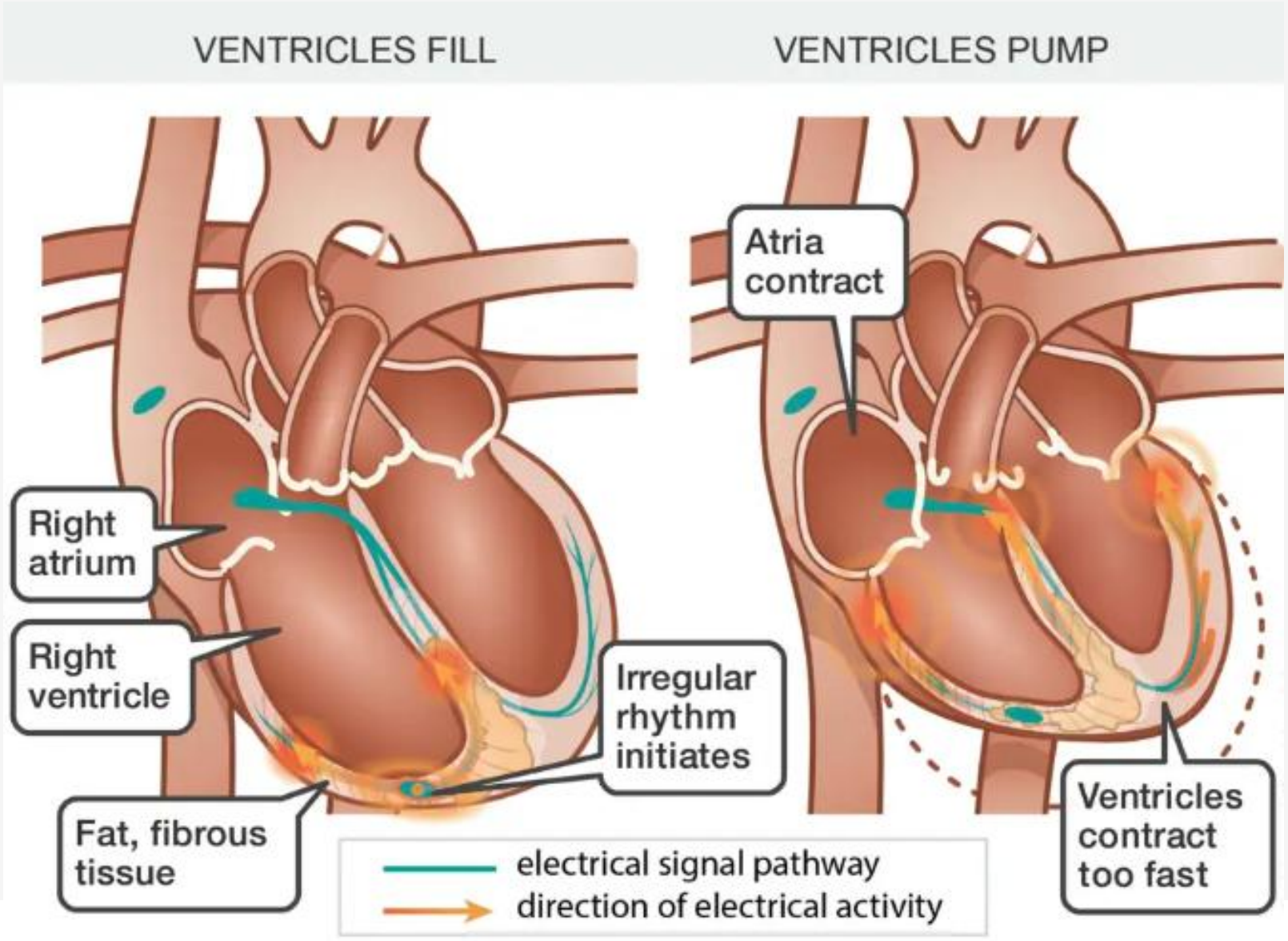

Arrhythmogenic Right Ventricular Dysplasia (ARVD)

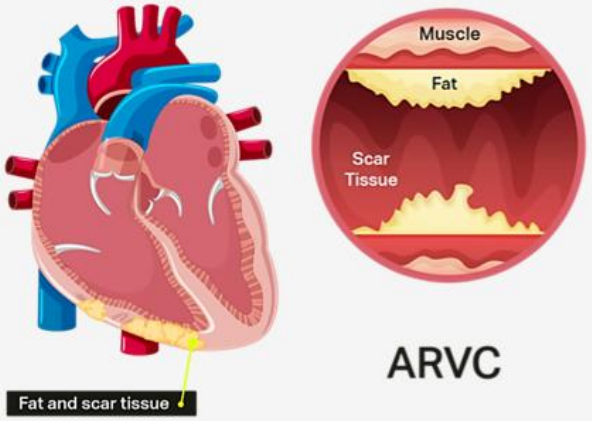

ARVC

Muscle of the RV is replaced by fat and fibrous tissue

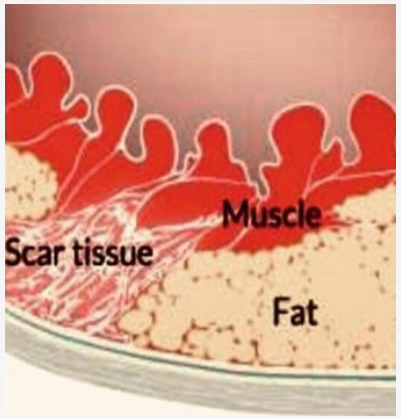

Scar tissue leads to electrical misfiring between cells

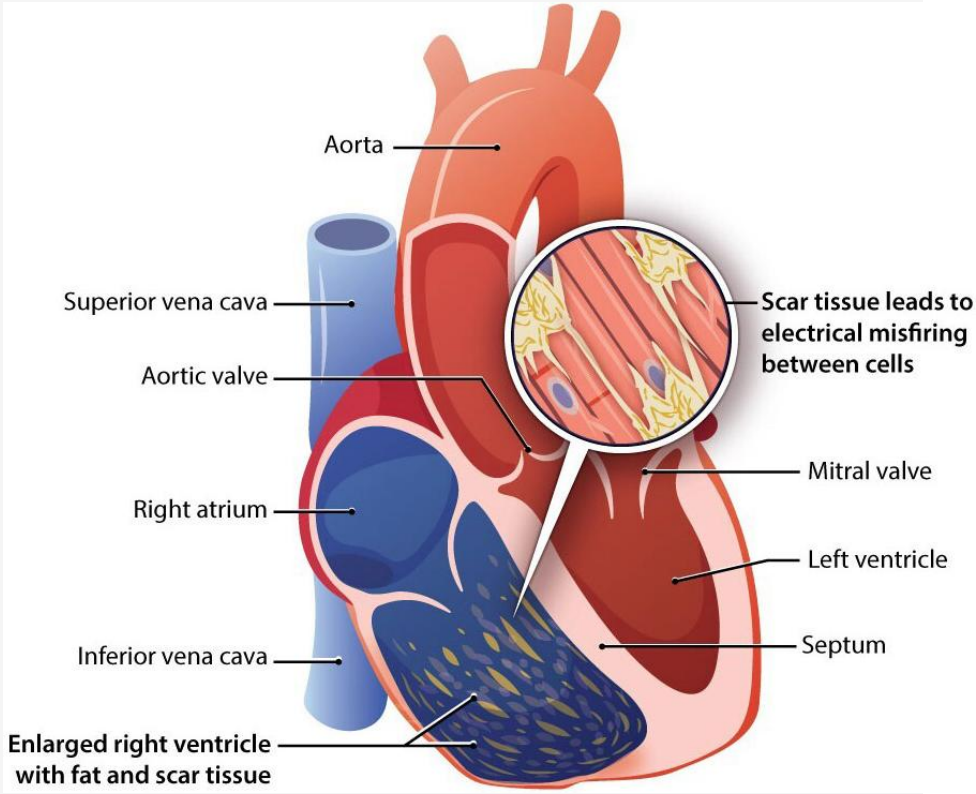

Desynchronized ventricular contraction

Failed to fill and pump normally



Criteria of ARVD

T-wave inversion in right precordial leads

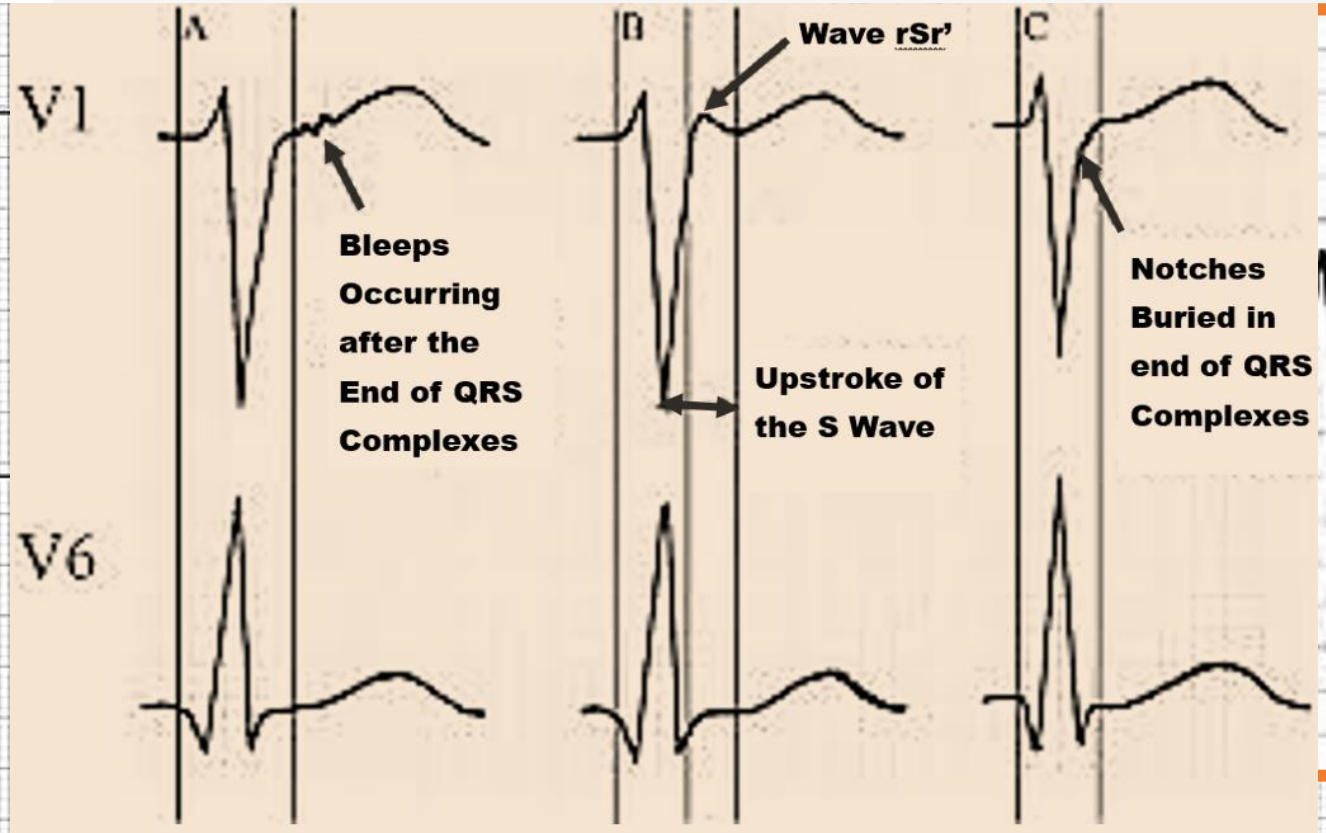

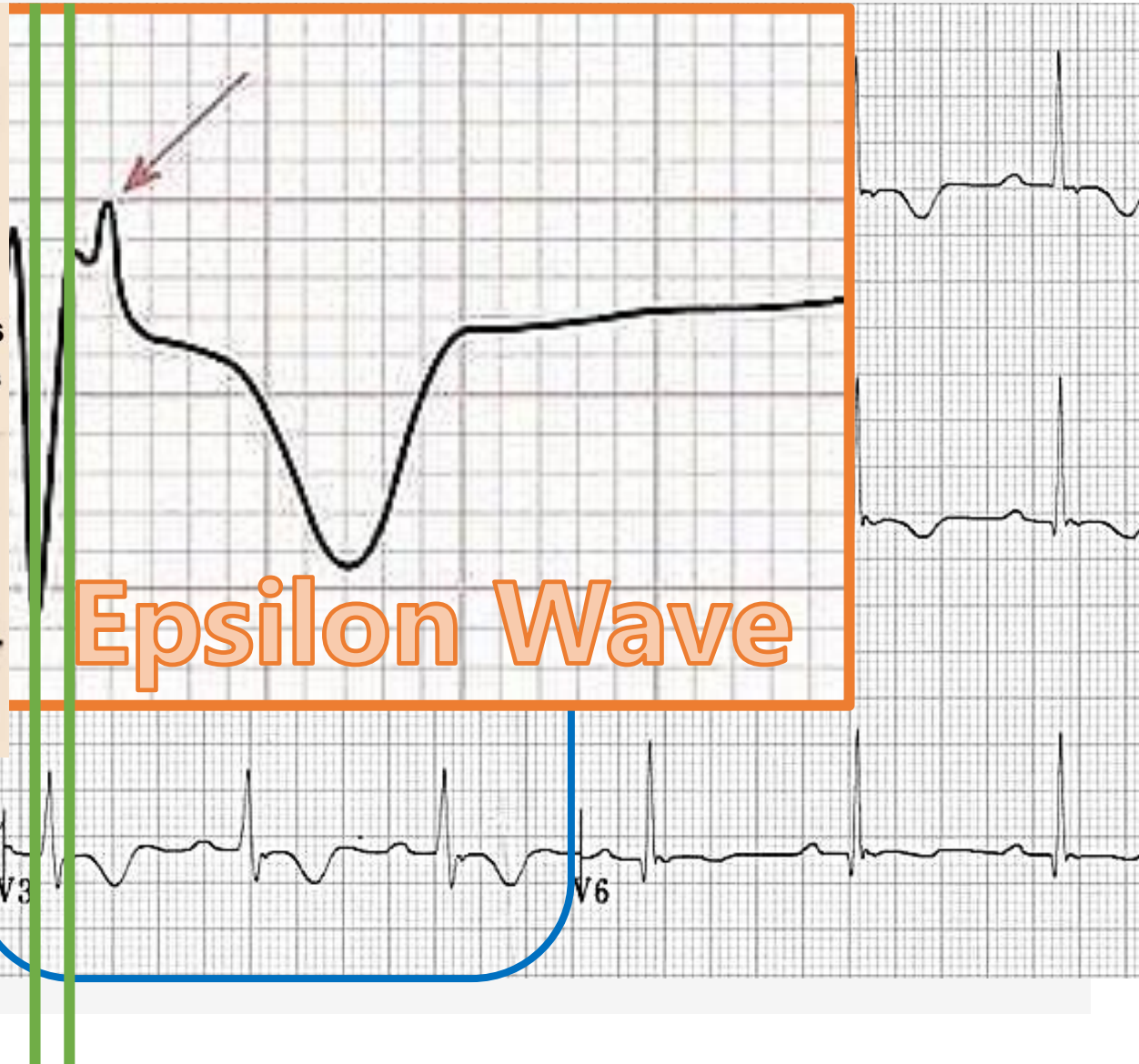

Prolonged S-wave upstroke of 55ms in V1-V3

Epsilon Wave: ARVC's Warning

The finding reflects electrical signal disruption caused by fibro fatty tissue in the RV, which can lead to dangerous ventricular arrhythmias and sudden cardiac death

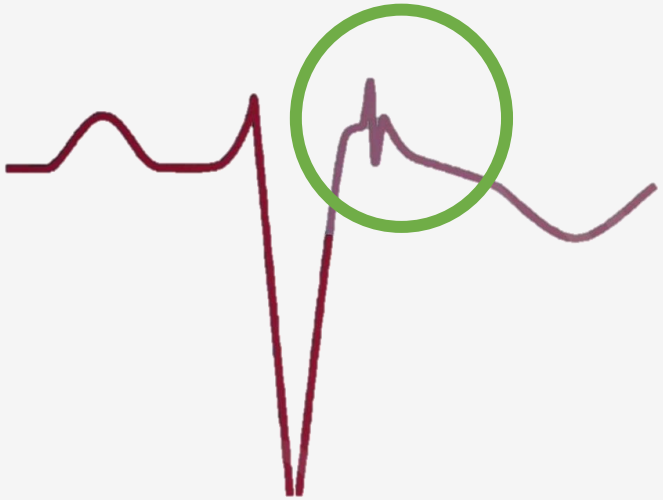

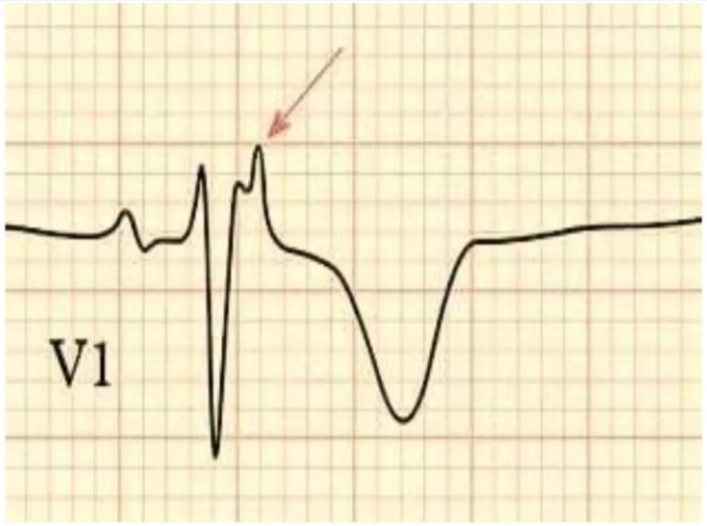

Epsilon wave in V1 due to RV conduction delay

Epsilon Wave

Usually seen in lead V1 and V2

High specificity (but not exclusive):

While highly specific for ARVC, **other conditions** like **cardiac sarcoidosis, Brugada syndrome, or RV infarction can** also present with epsilon waves

Criteria of ARVD

5. **Ventricular ectopy** of **LBBB morphology**, with frequent PVCs >1000 per 24hours

6. **Paroxysmal** episodes of **VT with LBBB morphology** (RVOT tachycardia)

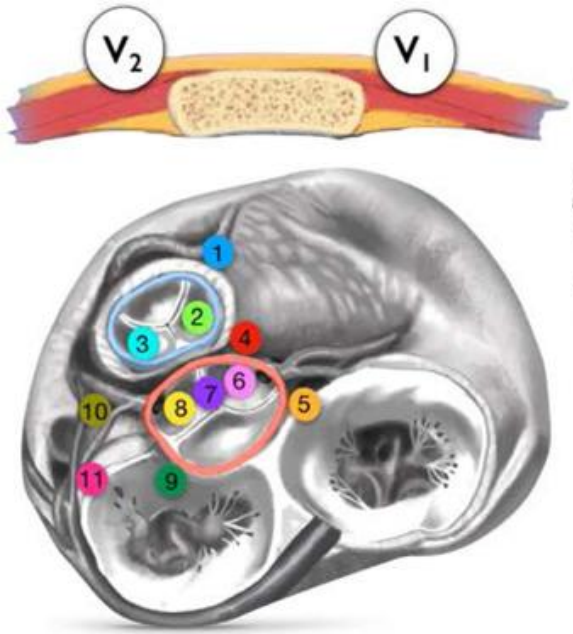

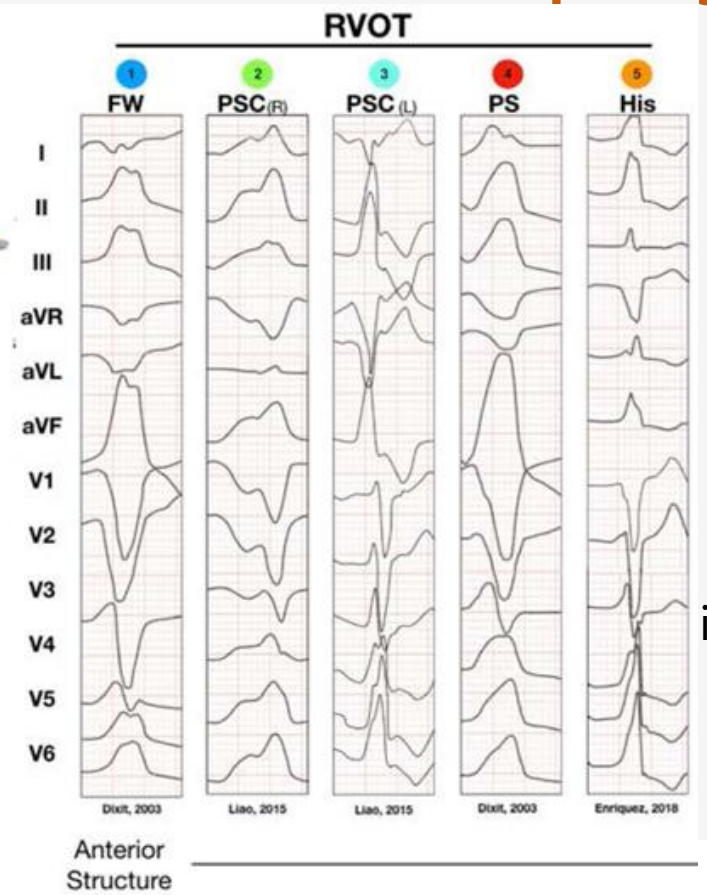

W

illiam

M

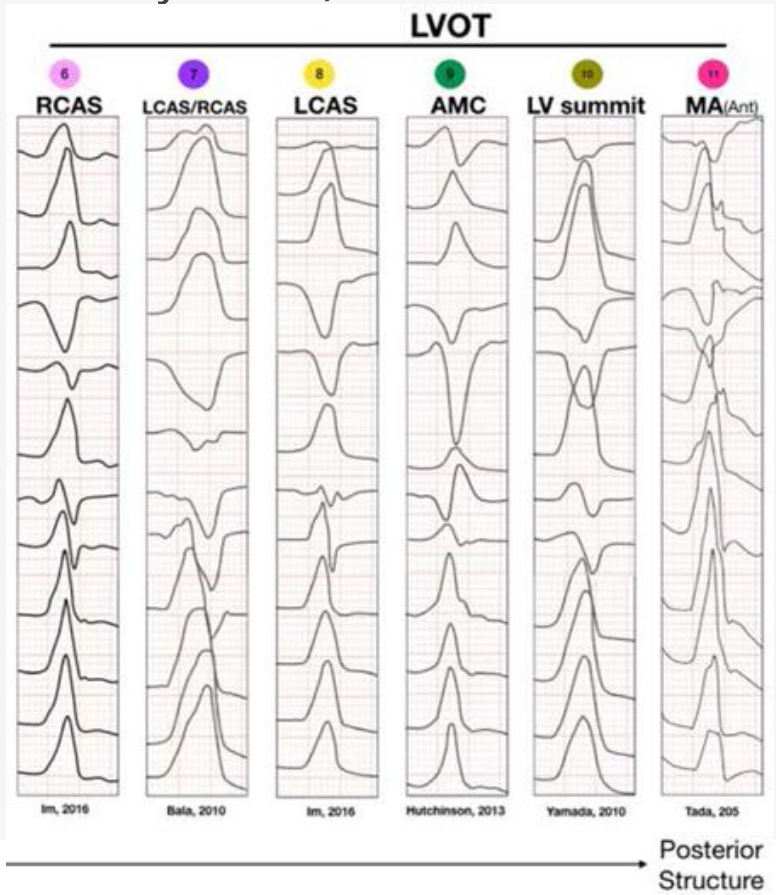

M

arrow

W

Criteria of ARVD - Echocardiogram

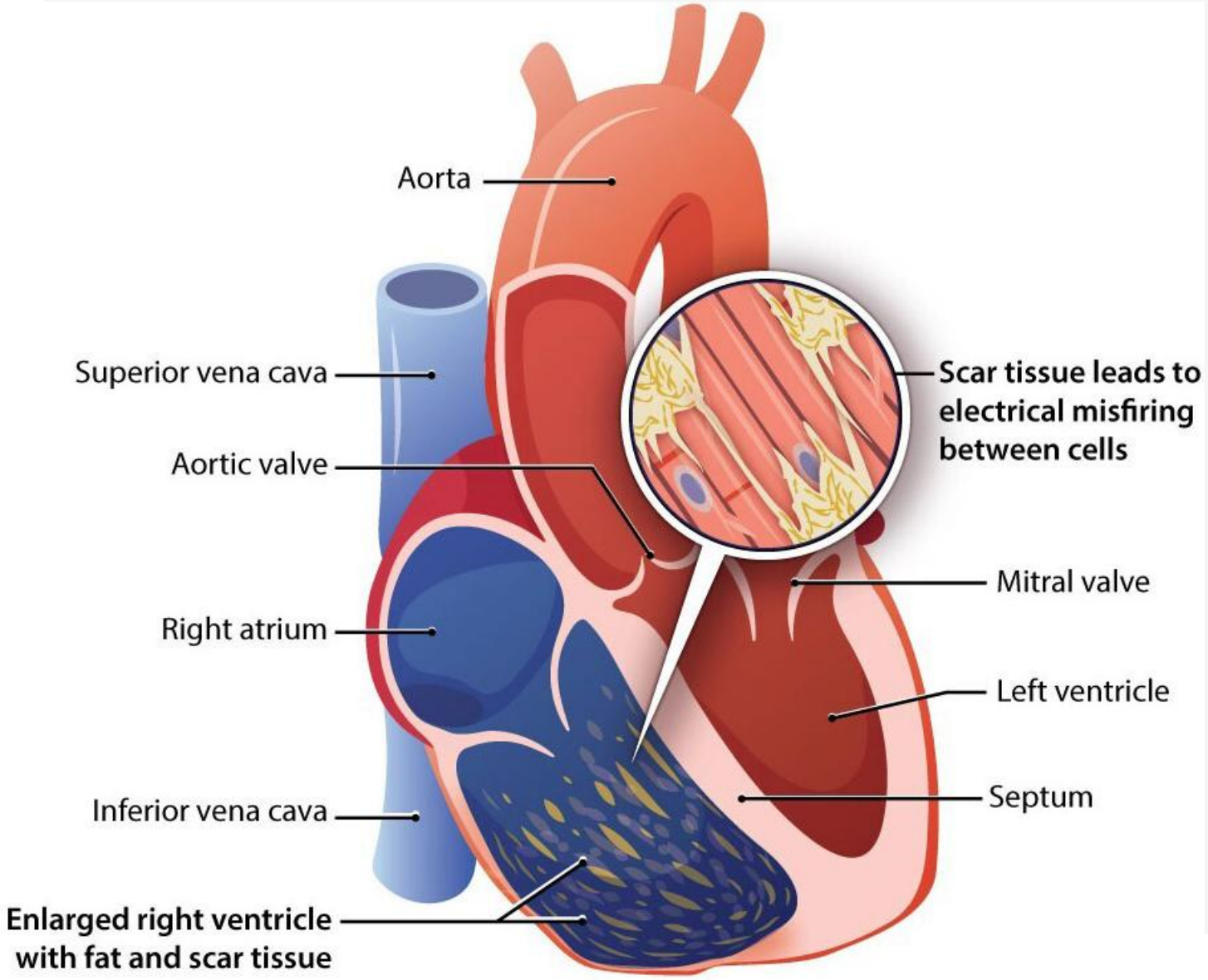

1. RV walls – Dilatation and hypokinesia
2. RV Apex
   - ✓ Prominent Trabeculae
   - ✓ Akinesis – Dyskinesis
3. RV Inferobasal Segment
   - ✓ Akinesis – Dyskinesis
   - ✓ Aneurysm
4. RVOT = Isolated Dilatation
5. RV Moderator band = Increased Reflectivity

Brugada Syndrome

Brugada Syndrome is due to a **mutation** in **Sodium Channel gene**

Channelopathy
♠SCN5A (Loss of Function)
Sodium Voltage-Gated Channel Alpha Subunit 5
Alpha Subunit of Cardiac Sodium Channels

Sodium, Potassium, Calcium Channels

Familial clustering and **autosomal dominant inheritance** has been demonstrated

Alpha Subunit of Cardiac Sodium Channels

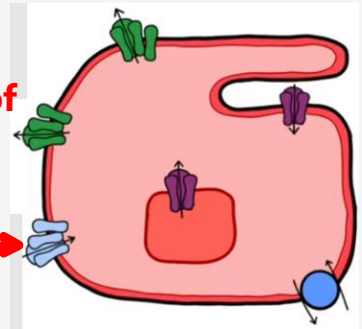

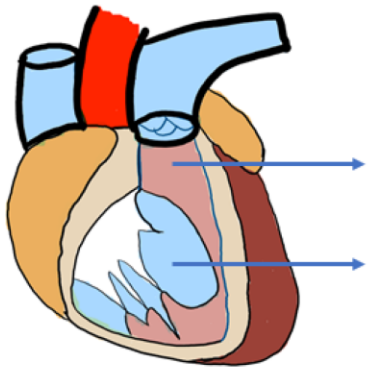

RVOT
Sodium channel
Right ventricle

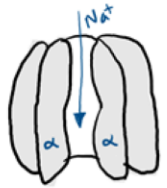

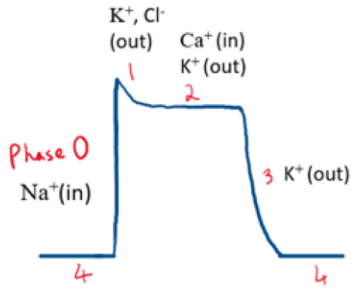

SCN5A gene mutation in the α-subunit of the cardiac Na^+ channel:
reduced expression of Nav 1.5 α-subunit

↓

Loss of functional Na^+ channels

↓

Impaired phase 0 action potential (fast upstroke)

↓

Reduced Na^+ current and/or other channel abnormalities

↓

Depolarization, repolarization abnormalities
Prolonged PR interval, wide QRS
Prolonged T-peak T-end interval
Slowed cardiac conduction
Phase 2 re-entry, late potentials

Elevation/reduction - specific plasma proteins
AT III post-translational modification

Autoantibodies against cardiac α-actin, connexin-43 keratin, skeletal α-actin.

Myocyte inflammation, fibrosis - RVOT, RV

Risk factors
Male gender
Family history of SCD
Spontaneous BrS type 1 ECG
Syncope
SCN5A gene mutation
Inducible VT/VF

Coved type
ST elevation
V1-V2 leads

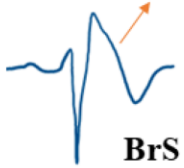

BrS type 1 ECG pattern
VF, sustained VT, aborted SCD
Syncope, ICD appropriate shock
Electrical storm

Sudden cardiac death

Exact Mechanism (Brugada's Syndrome)

Exact Mechanism (Unknown)

1. Depolarisation Theory
2. Repolarizarion Theory
3. Current/ Load mismatch theory

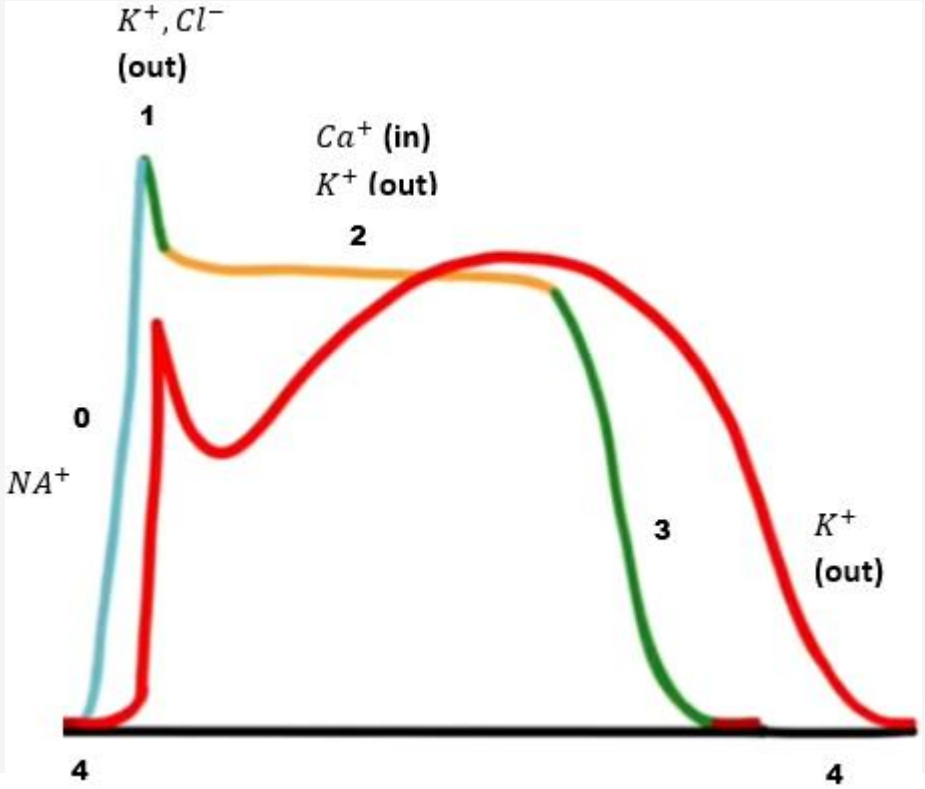

Abnormal Cardiac Action Potential

Predisposes to **VT/ VF**

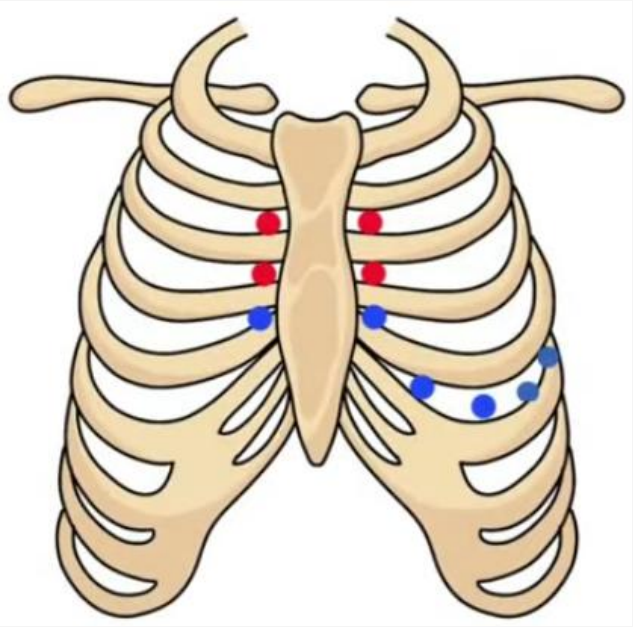

Right precordial leads placed in **2nd or 3rd *IC* spaces**

Brugada Syndrome

Type 1



Type 2



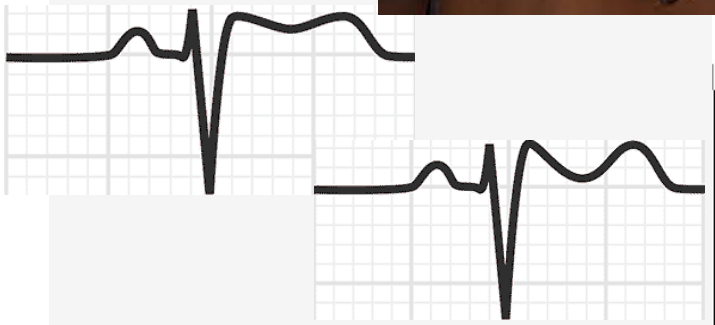

Type 3

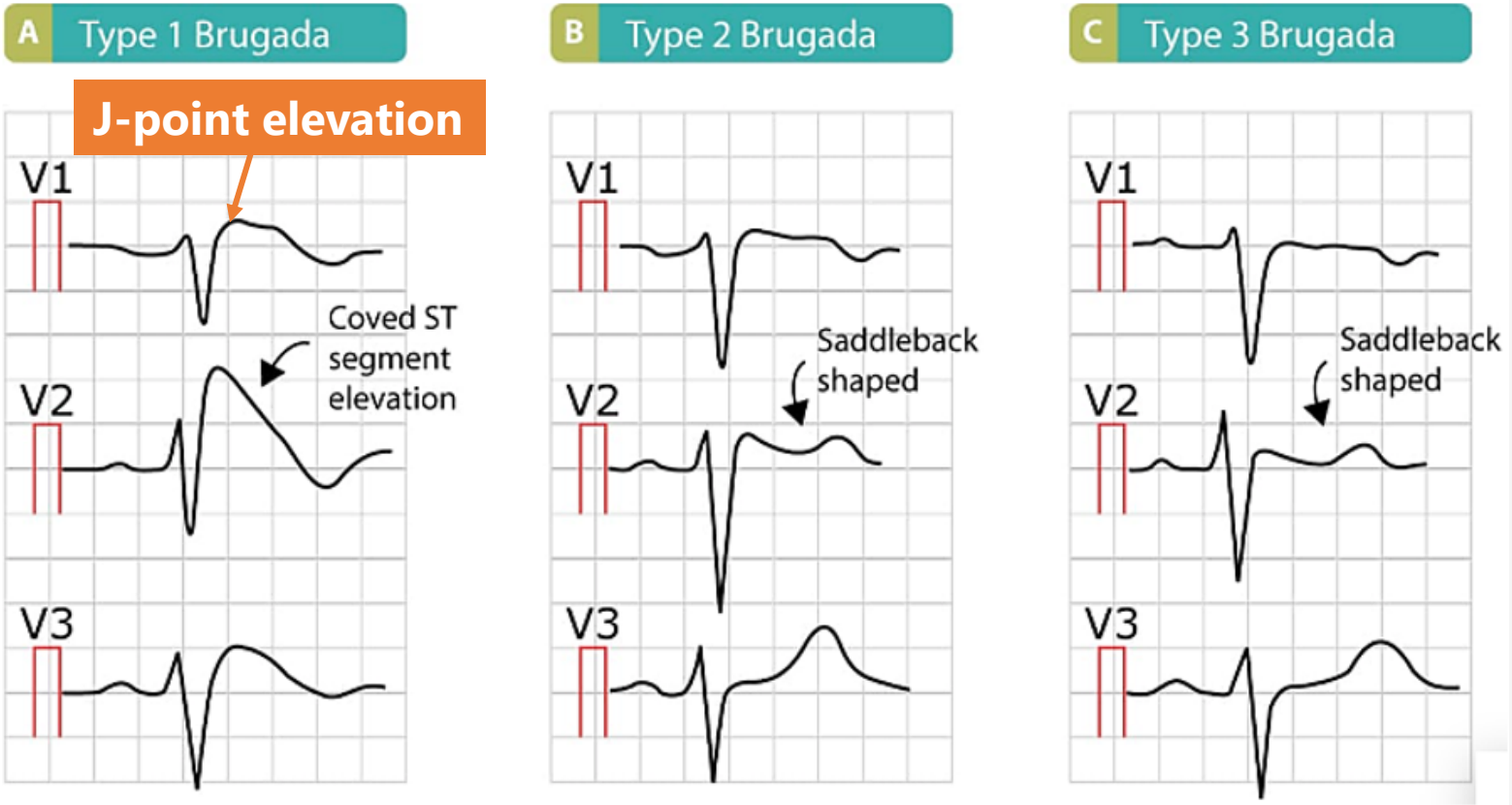

STE pattern	Coved shaped which ends with T-wave inversion	Saddleback-shaped	
J point		Elevated ≥2mm in V1 and/ or V2	Elevated <1mm in V1 and/ or V2
Pattern	Diagnostic	Non-diagnostic	
Response	Present with or without Na+ channel blocker	After Na+ channel blocker, converts to type 1 Flecainide	

Wellens Syndrome

Wellens Syndrome is a clinical syndrome characterized by biphasic or deeply inverted T waves in V2-V3, plus a history of recent chest pain now resolved.

It is highly specific for critical stenosis of the let anterior descending artery (LAD)

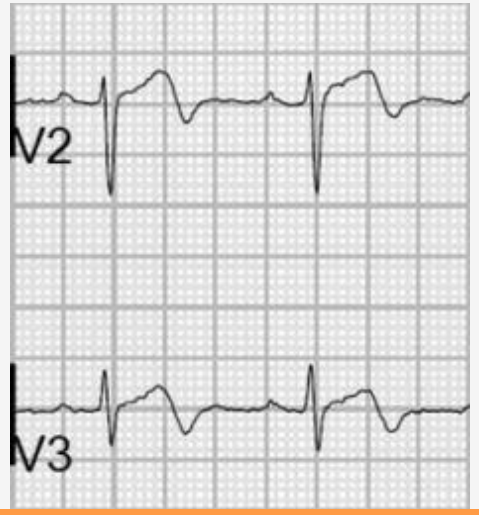



Wellen Pattern A:	Wellen Pattern B:
Biphasic T waves	Deep T waves inversion
Terminal T-wave inversion	Symmetric T-wave inversion

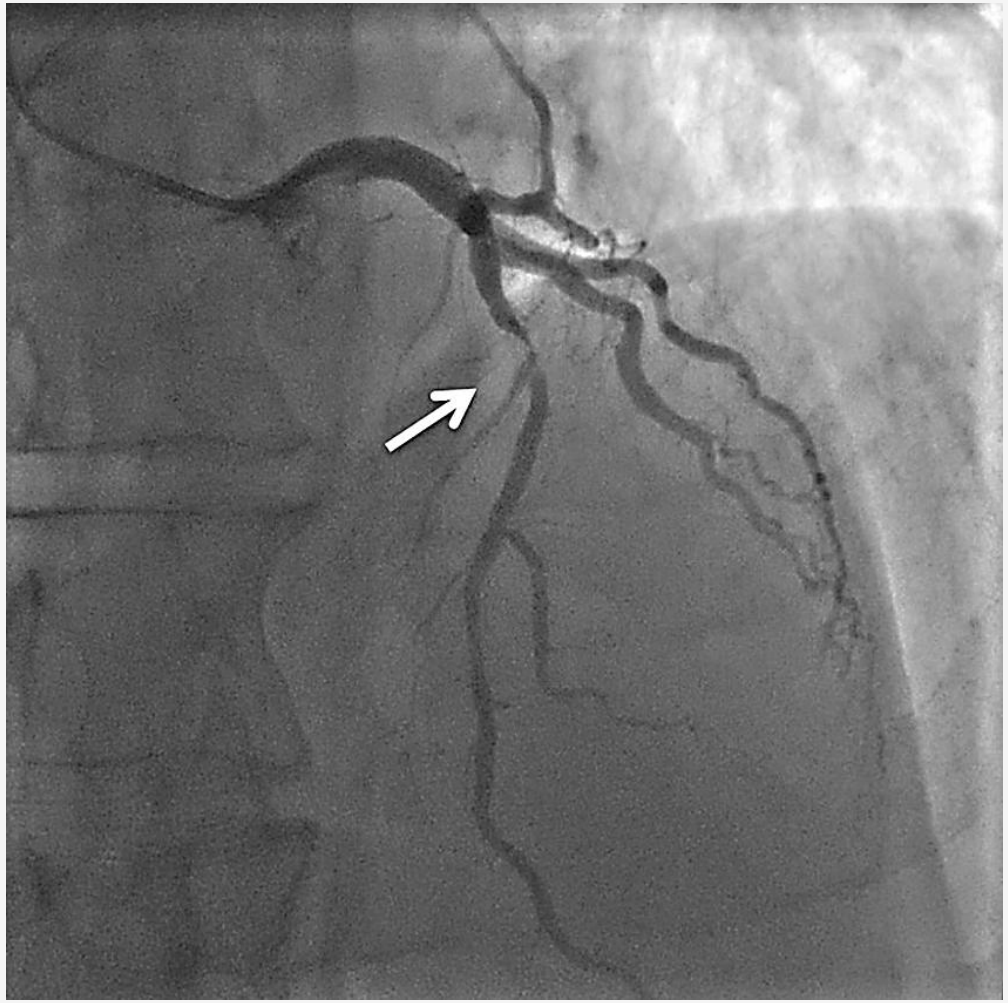

Atrial Septal Defect

1. **Crochetage sign**
   - ♥ A notch near the apex of the R wave notching in inferior leads

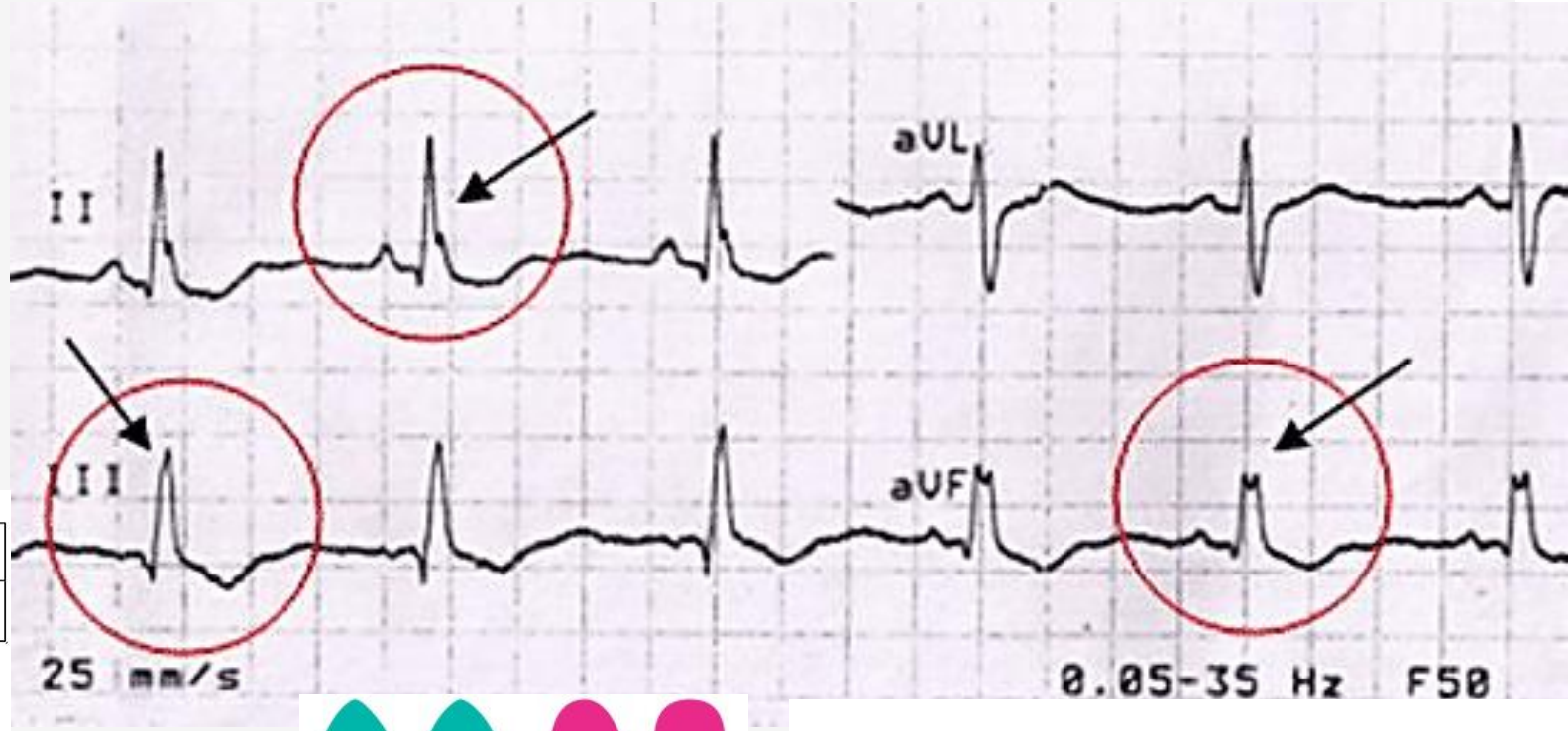

2. **Right Axis Deviation**

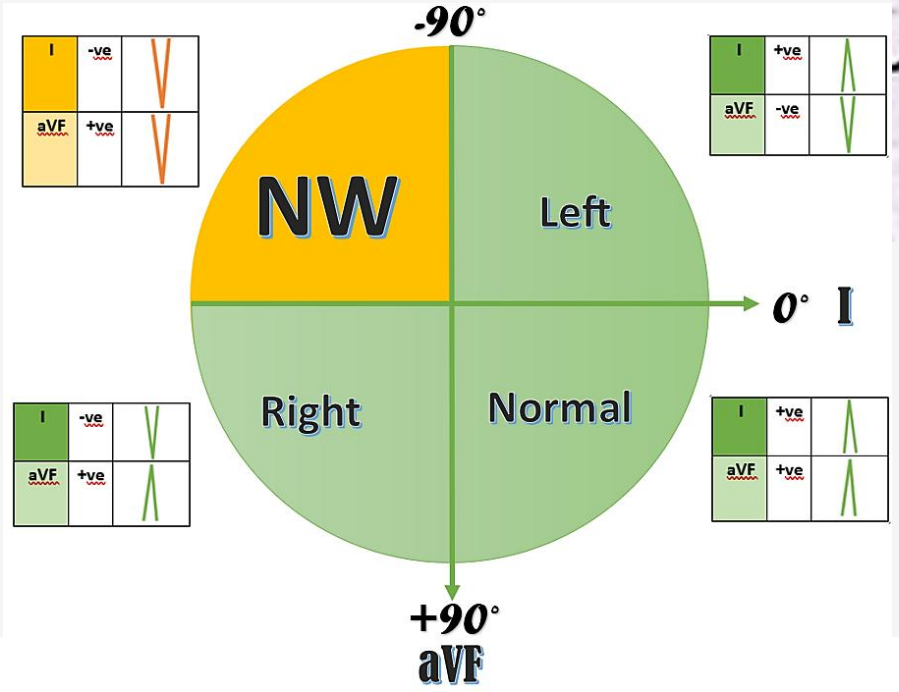

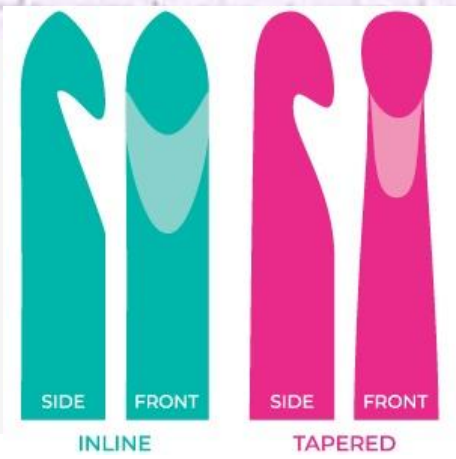



Crochetage Sign – is not only meant for ASD

Inferior leads show notched R waves

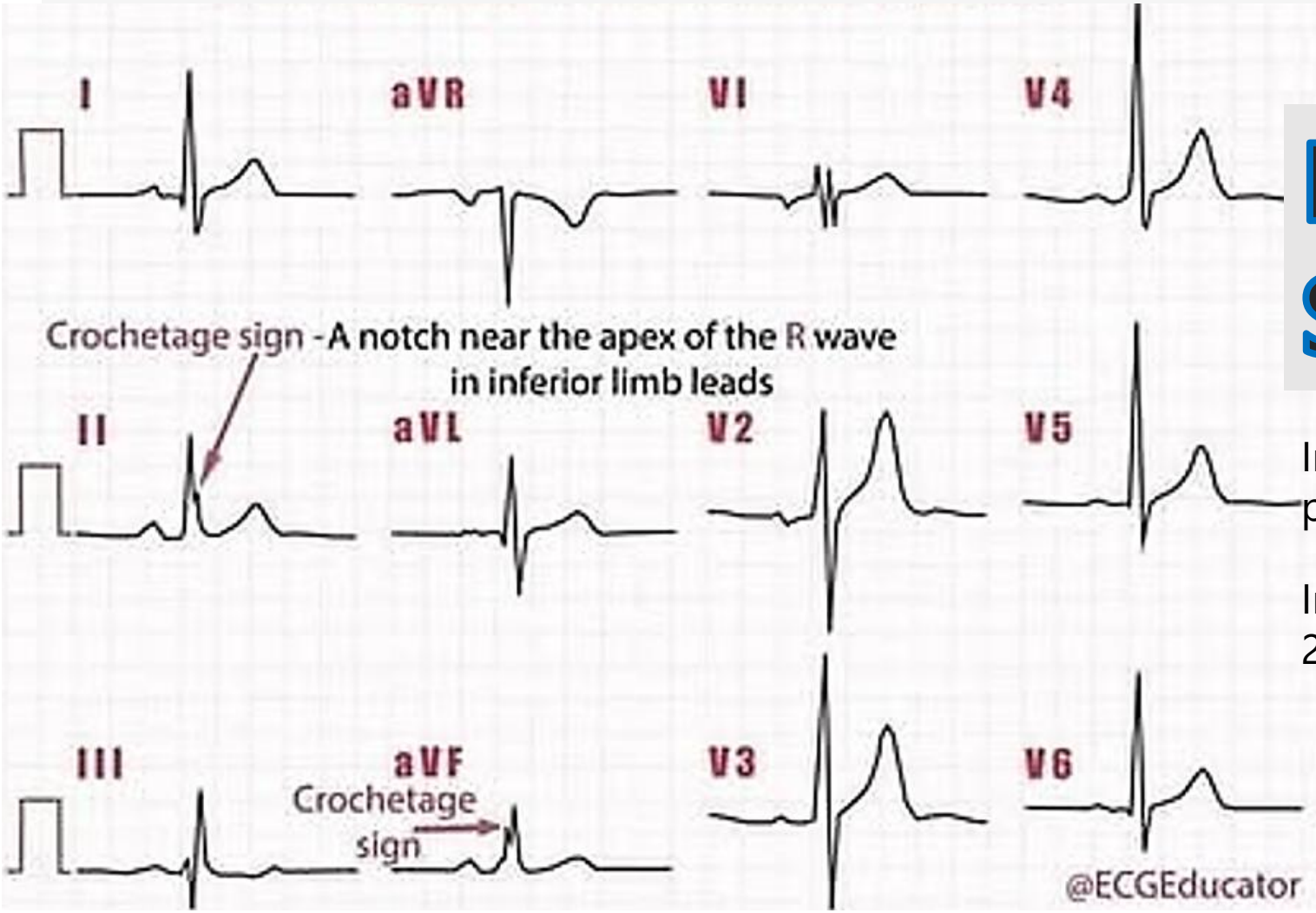



VSD

Pulmonary Stenosis (PS)

ASD patients

Involves all 3 inferior leads in 0.7% of the PS patients

Involves at least 1 inferior limb lead in 73% of the ASD patients

Involves at least one inferior limb leads in 23% of the PS patients

Crochetage Sign

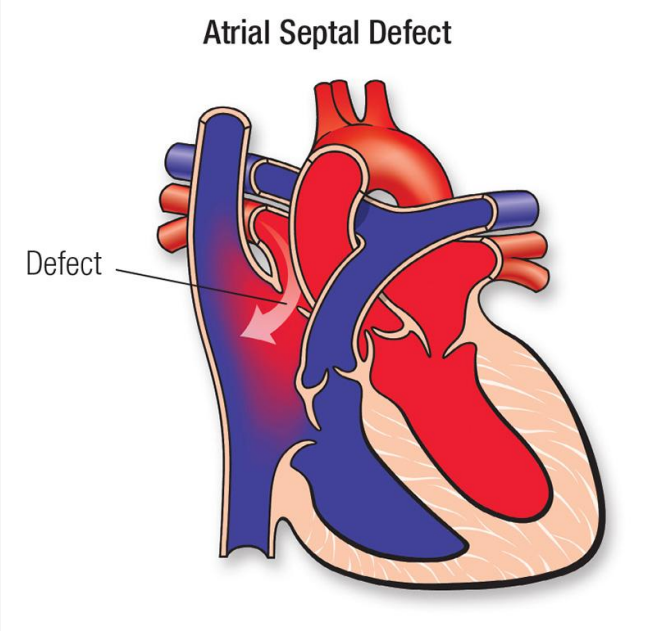

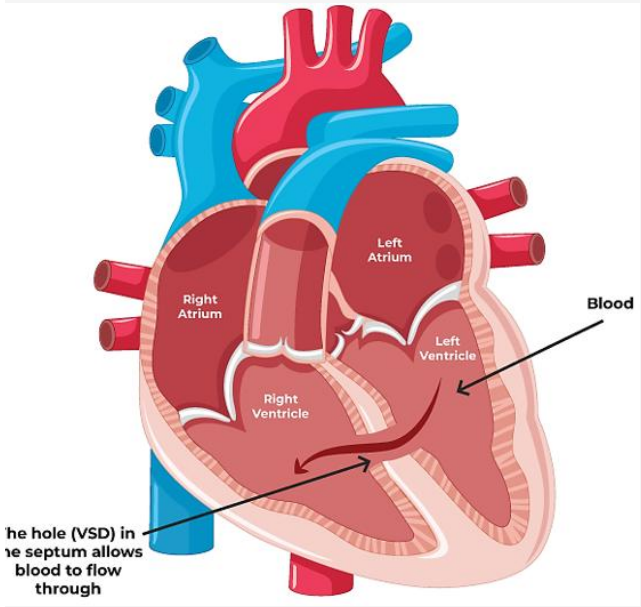

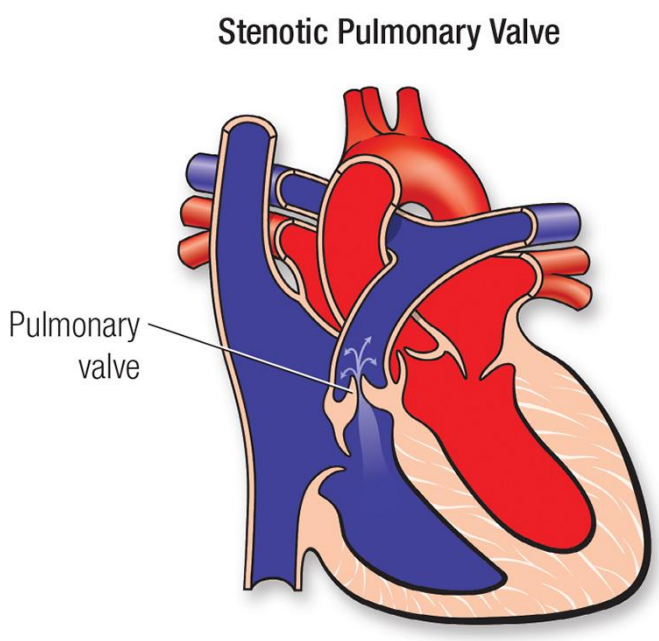

	Atrial Septal Defect	Ventricular Septal Defect	Pulmonary Stenosis
Involves in all 3 inferior leads	27%	2%	0.7%
Involves at least one inferior limb lead	73%	35%	23%
Crochetage sign Disappears	2 weeks after ASD closure (50%)		

Atrial Septal Defect - RVH

QRS duration <120ms (changes not due to RBBB)

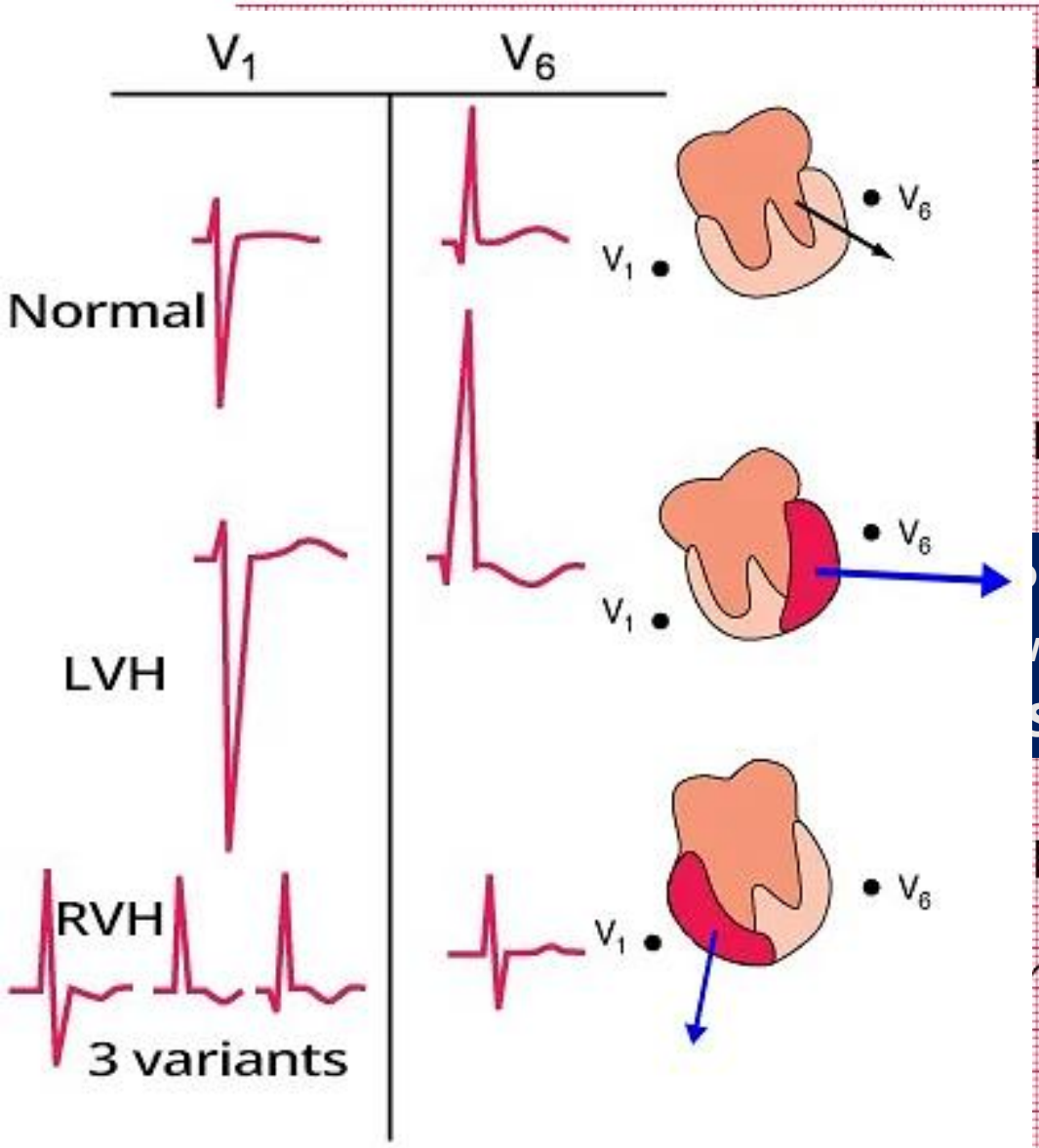

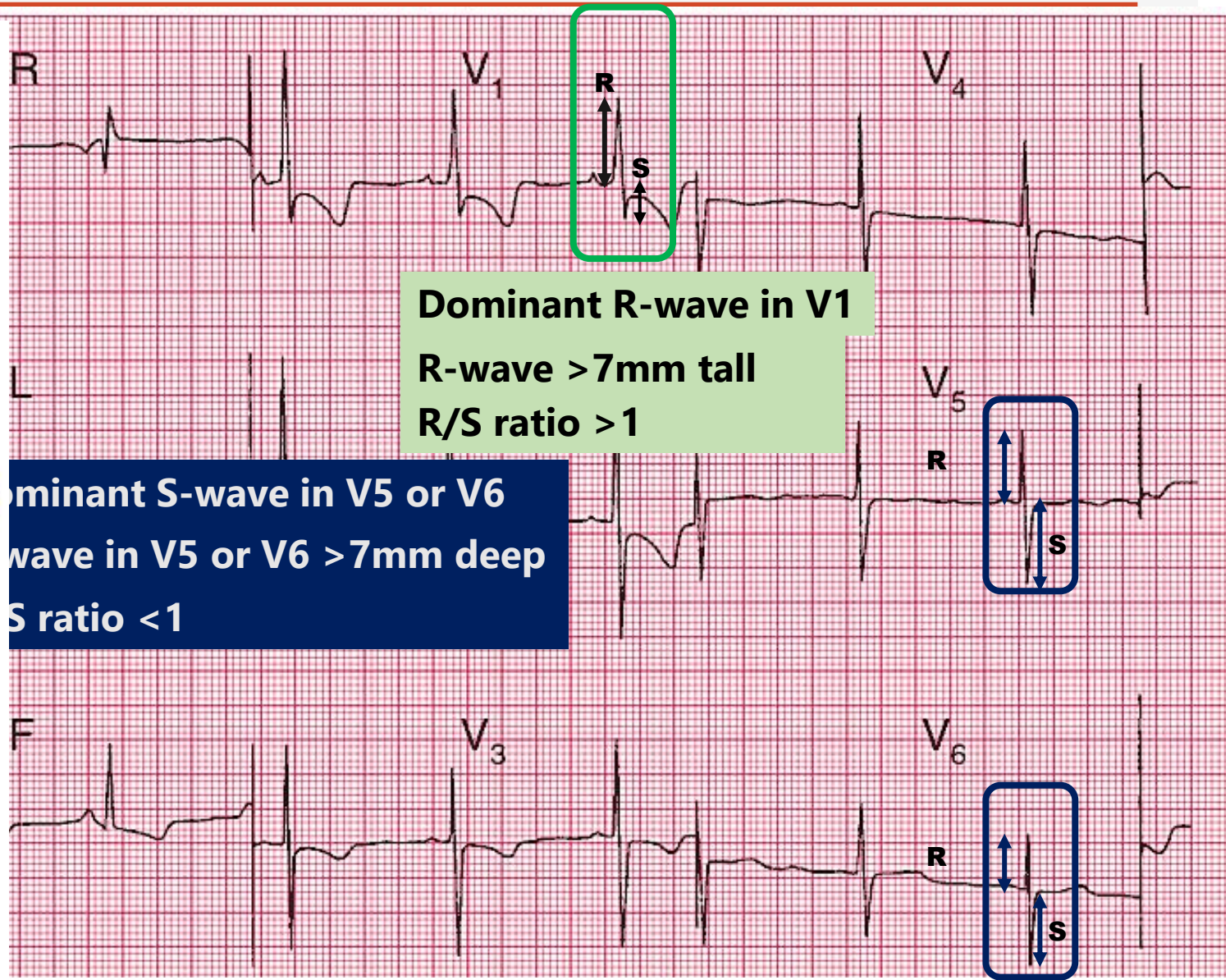

Dominant R-wave in V1

R-wave >7mm tall

R/S ratio >1

minant S-wave in V5 or V6

wave in V5 or V6 >7mm deep

S ratio <1

What else do you see?

RAE

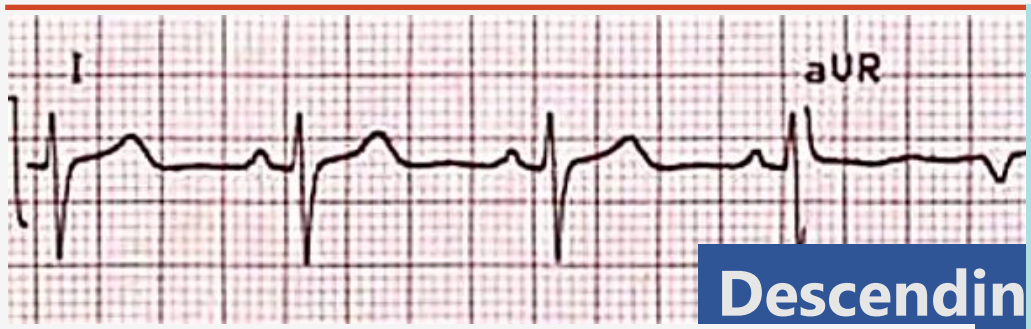

Descendin







ring repolarization



Atrial Septal Defect

5. Right Atrial Enlargement (RAE)
   - ♥ Tall, peaked P-waves (**P Pulmonale**)
   - ♥ >2.5mm in the inferior leads
   - ♥ >1.5mm in V1 and V2

6. First Degree AV Block
   - ♥ PR prolonged

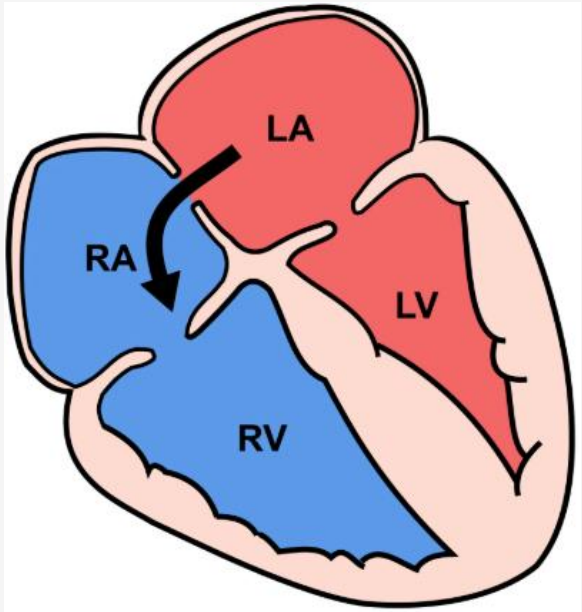

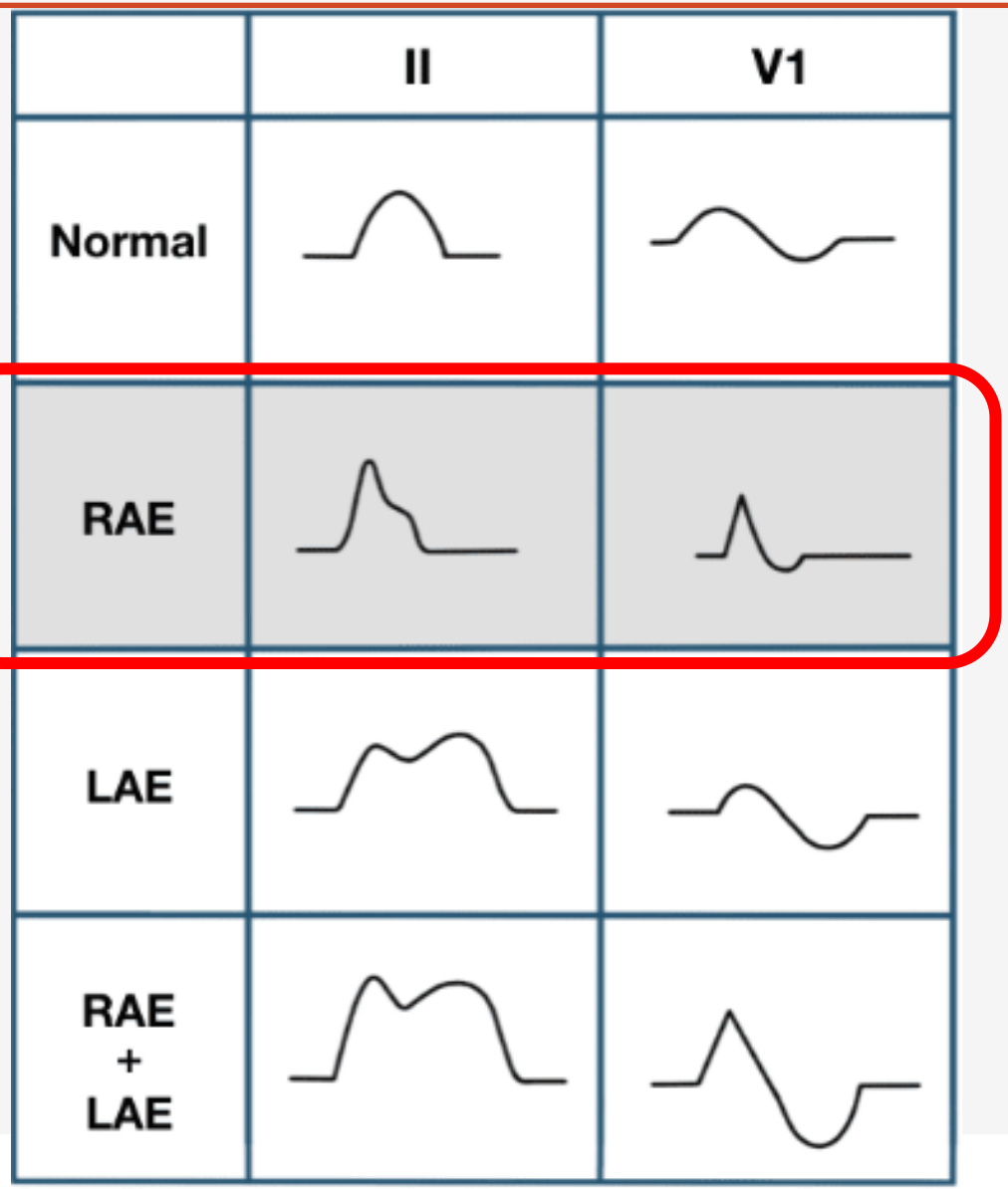

spandan®

Decoding Pericarditis

Symptoms, Causes & Treatment Explained

Symptoms

- Chest Pain
- Fever
- Heart Palpitations
- Shortness of Breath
- Fatigue & Weakness

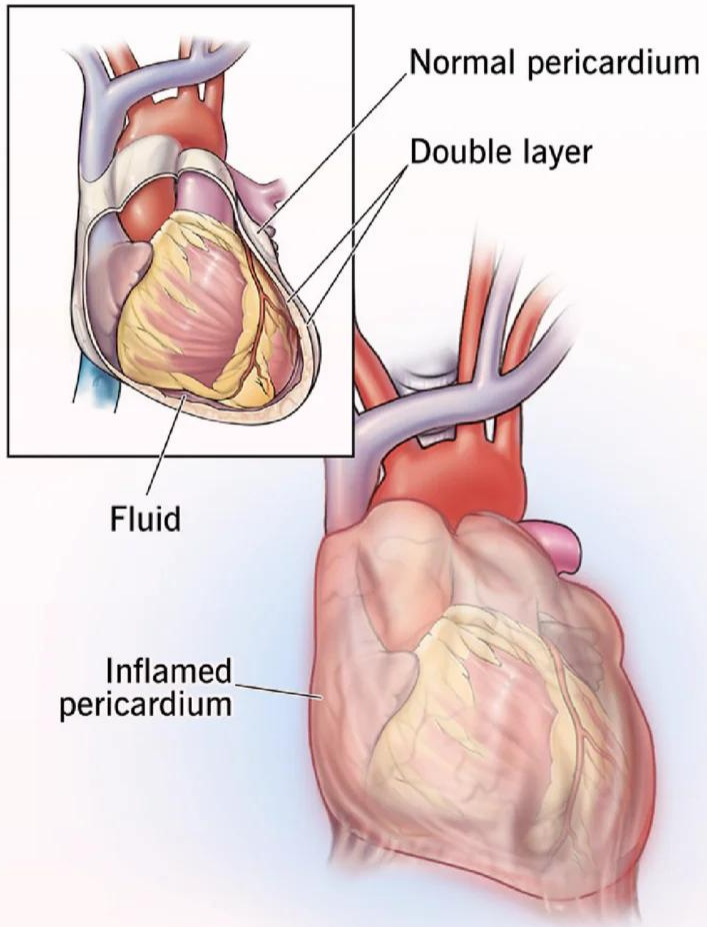

Causes

- Viral & Bacterial Infections
- Autoimmune Disorders
- Fungal & Parasitic Infections
- Trauma & Surgery
- Cancer

Pericarditis

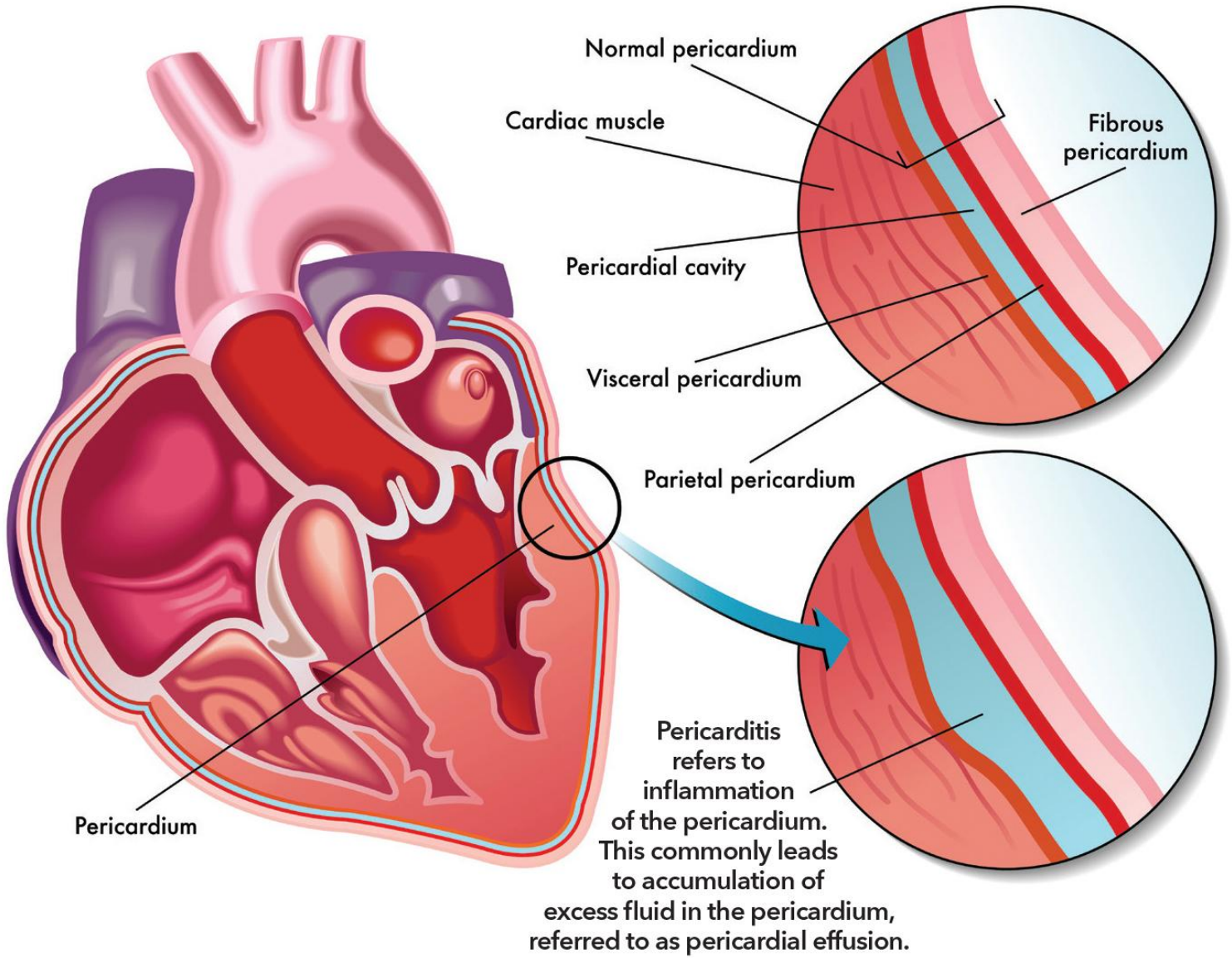

Healthy pericardium

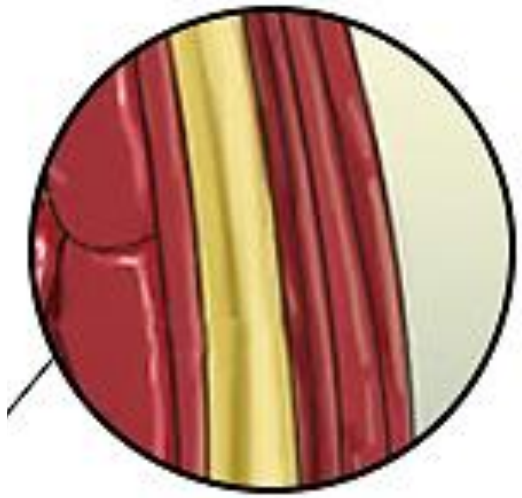

Inflamed pericardium

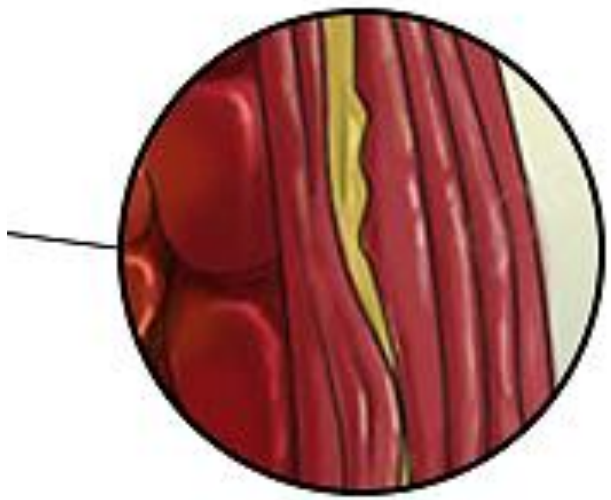

PERICARDITIS

Widespread concave STE and
PR depression throughout most of the limb leads (I, II, III, aVL, aVF) **and precordial leads** (V2-V6)

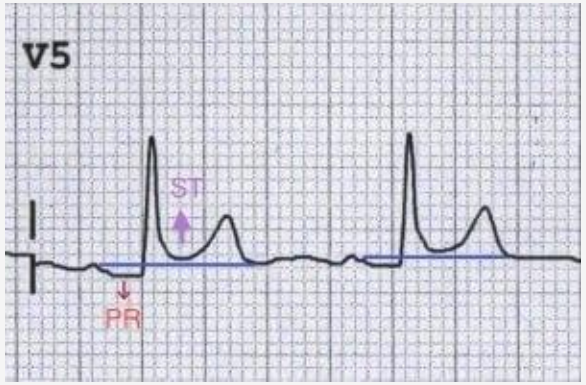

- ♥ PR depression and STE in V5
- ♥ Degree of STE is modest (0.5 – 1.0mm)
- ♥ ST- and PR-segment changes are relative to the baseline formed by TP segment

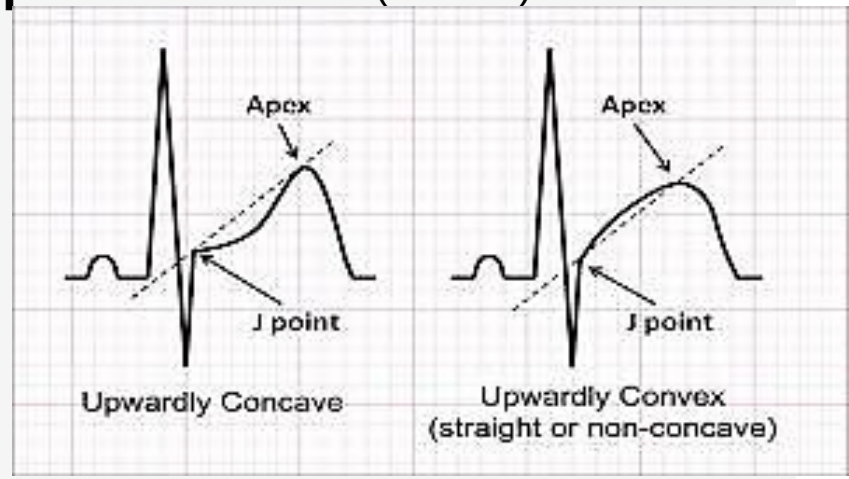

Reciprocal STD and PR elevation in lead aVR ± V1



- ♥ Reciprocal PR elevation and ST depression

STD and PR elevation

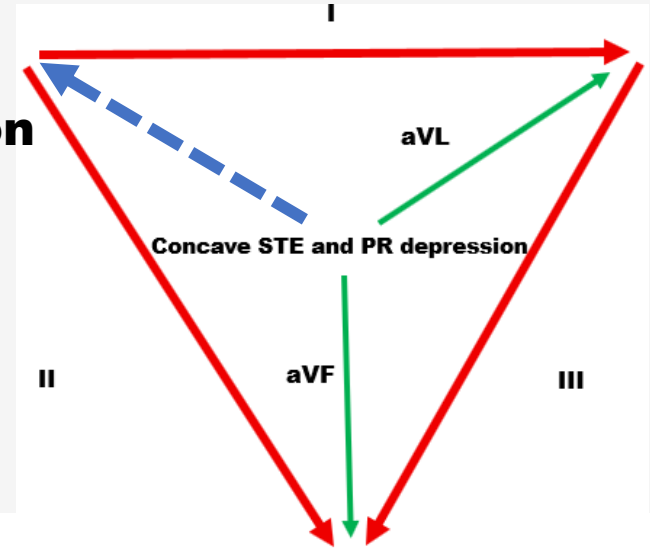

Sinus Tachycardia is also common in acute pericarditis

Spodick sign



Downslopping TP segment seen as an early ECG manifestation in 30% of patients with preicarditis

Best visualized in leads II and the lateral precordial leads

Stages of Pericarditis

1



Widespread STE and PR depression

With reciprocal changes in aVR

(occurs during the 1st two weeks)

2



Normalization of ST changes;

Generalized T-wave flattening
(1 to 3 weeks)

3



Flattened T-waves become inverted
(3 to several weeks)

4



ECG returns to normal
(several weeks onwards)

Four-Stage (“Typical”) Electrocardiographic Evolution of Acute Pericarditis

Four-Stage (“Typical”) Electrocardiographic Evolution of Acute Pericarditis

Stage	Leads of “Epicardial” Derivation			Leads Reflecting “Endocardial” Potential		
	S–T Segment	T Waves	P–R Segment	S–T Segment	T Waves	P–R Segment
1	Elevated	Upright	Depressed or isoelectric	Depressed	Inverted	Elevated or isoelectric
2 Early	Isoelectric	Upright	Isoelectric or depressed	Isoelectric	Inverted	Isoelectric or elevated
Late	Isoelectric	Low to flat to inverted	Isoelectric or depressed	Isoelectric	Shallow to flat to upright	Isoelectric or elevated
3	Isoelectric	Inverted	Isoelectric	Isoelectric	Upright	Isoelectric
4	Isoelectric	Upright	Isoelectric	Isoelectric	Inverted	Isoelectric

PERICARDITIS

Reciprocal STE and PR depression in aVR

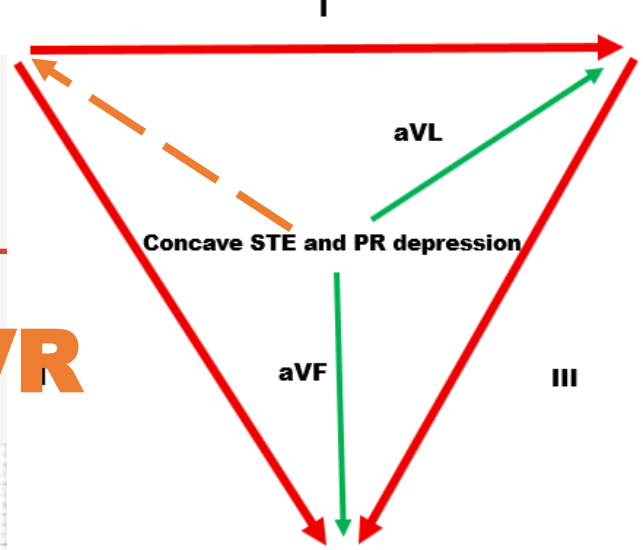

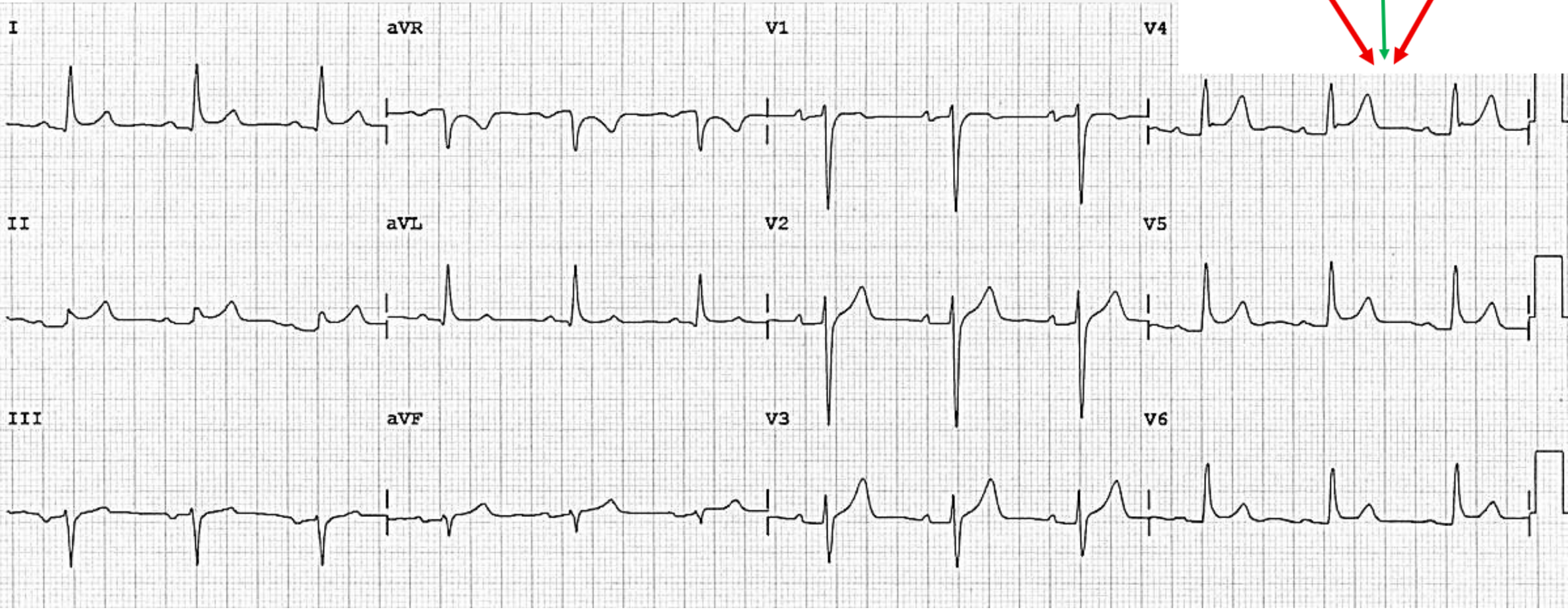

Pericarditis VS Benign Early Repolarization (BER)



ST segment height = 2mm
T-wave height = 4mm
ST/ T wave ratio = 0.5

ST/ T wave ratio > 0.25 is consistent with pericarditis

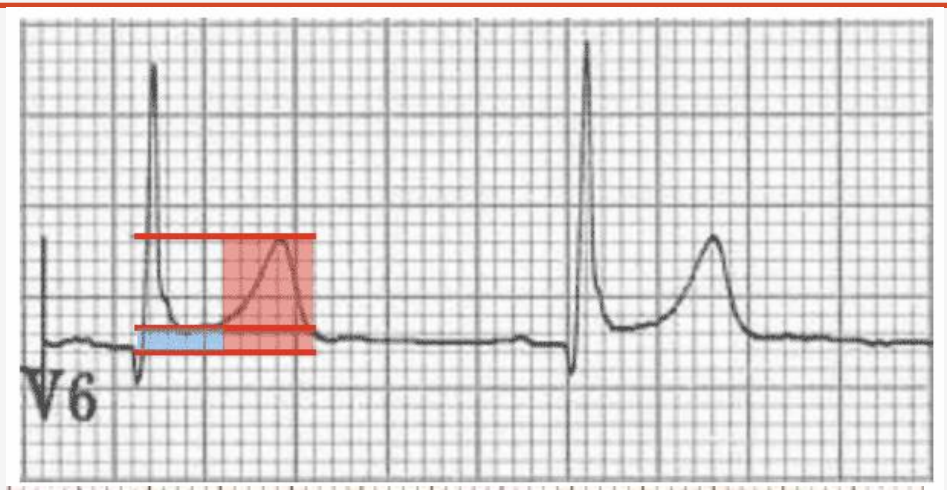

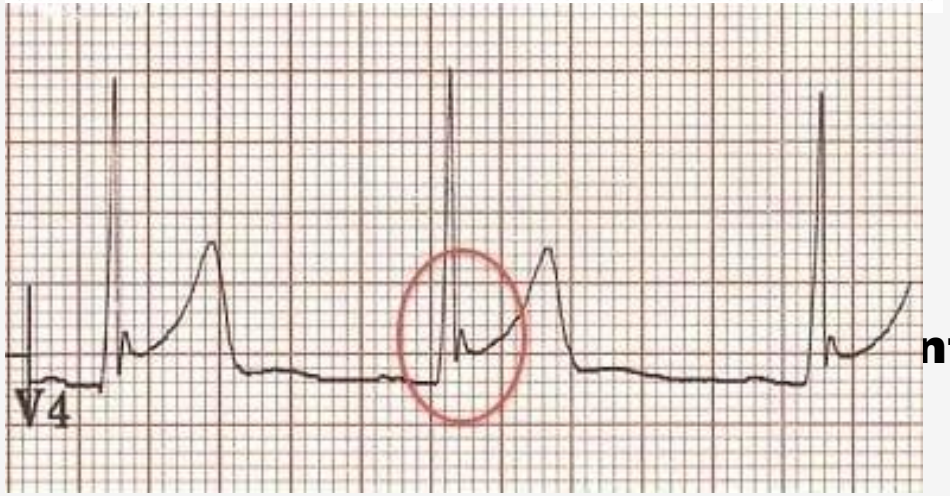

nt

"**Fish hook**" pattern suggestive for BER

Usually benign ECG pattern


thank
you