T wave

By Richard Long, HSIS

Outline



1. Normal T wave
2. Too tall
3. Too small
4. Biphasic
5. Camel hump
6. Inverted

What is the T wave?

T wave is the positive deflection after each QRS complex

It represents ventricular repolarization

Normal T wave

Upright in all leads except in V1 & aVR
Inverted T waves can also be normal in leads III, V2 and even V3
Amplitude <5mm in limb leads and <15mm in precordial leads

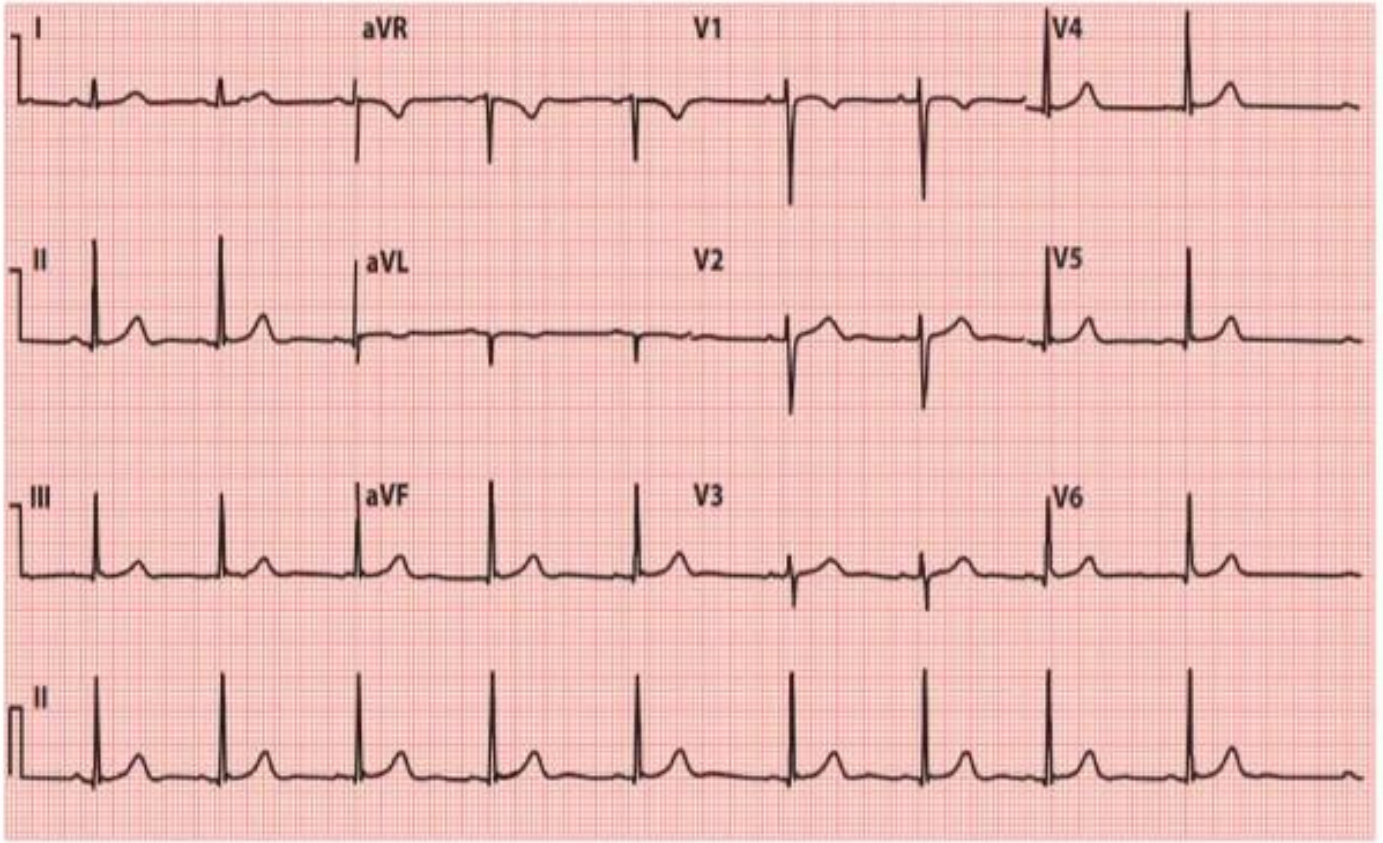

Figure 16.1 Normal 12-lead ECG.

Key point: • The shape and orientation of normal T waves varies from lead to lead.

Tall T waves

Could be due to hyperkalemia or acute coronary syndrome

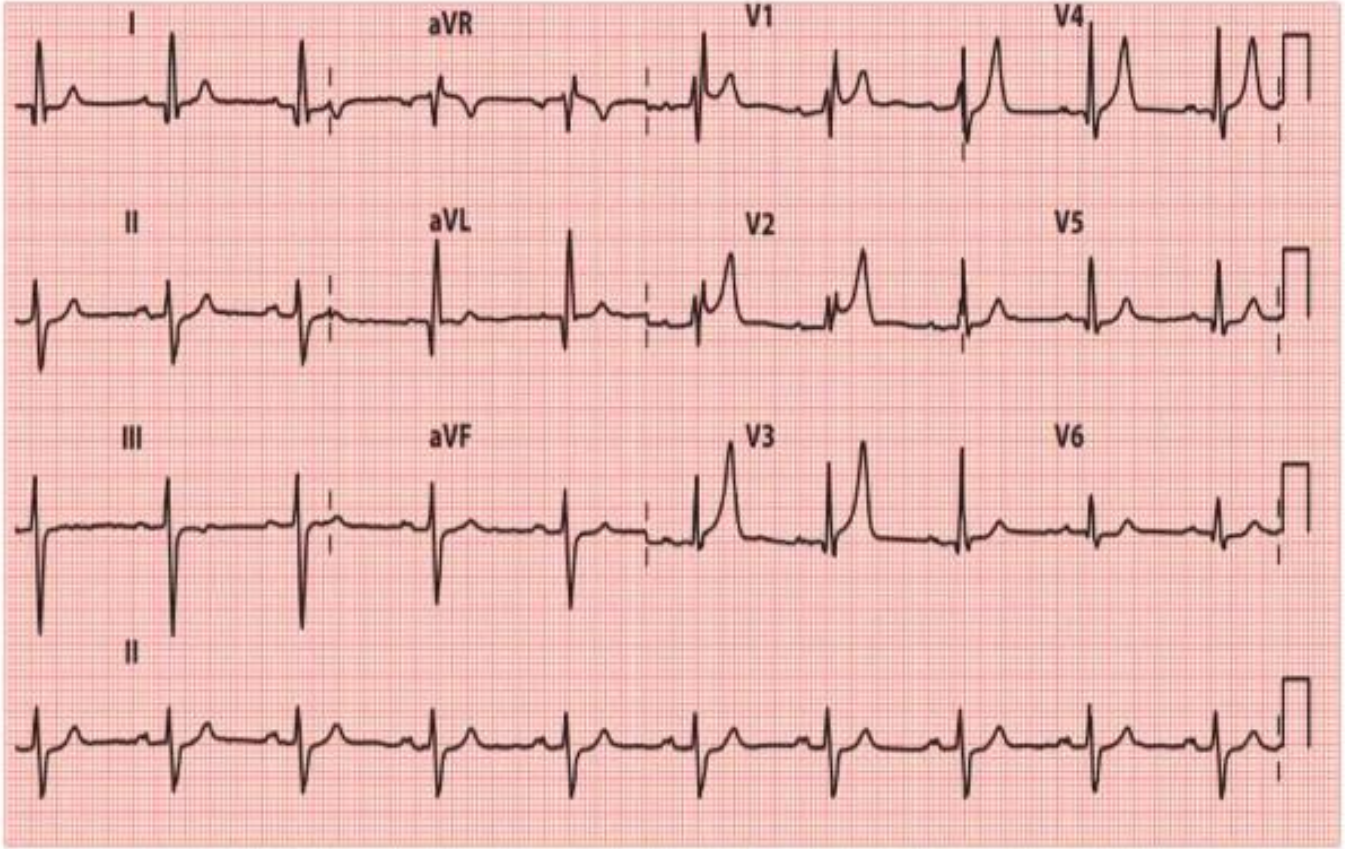

Figure 16.2 Hyperkalaemia.

Key point: • Tall 'tented' T waves are present in the anteroseptal chest leads.

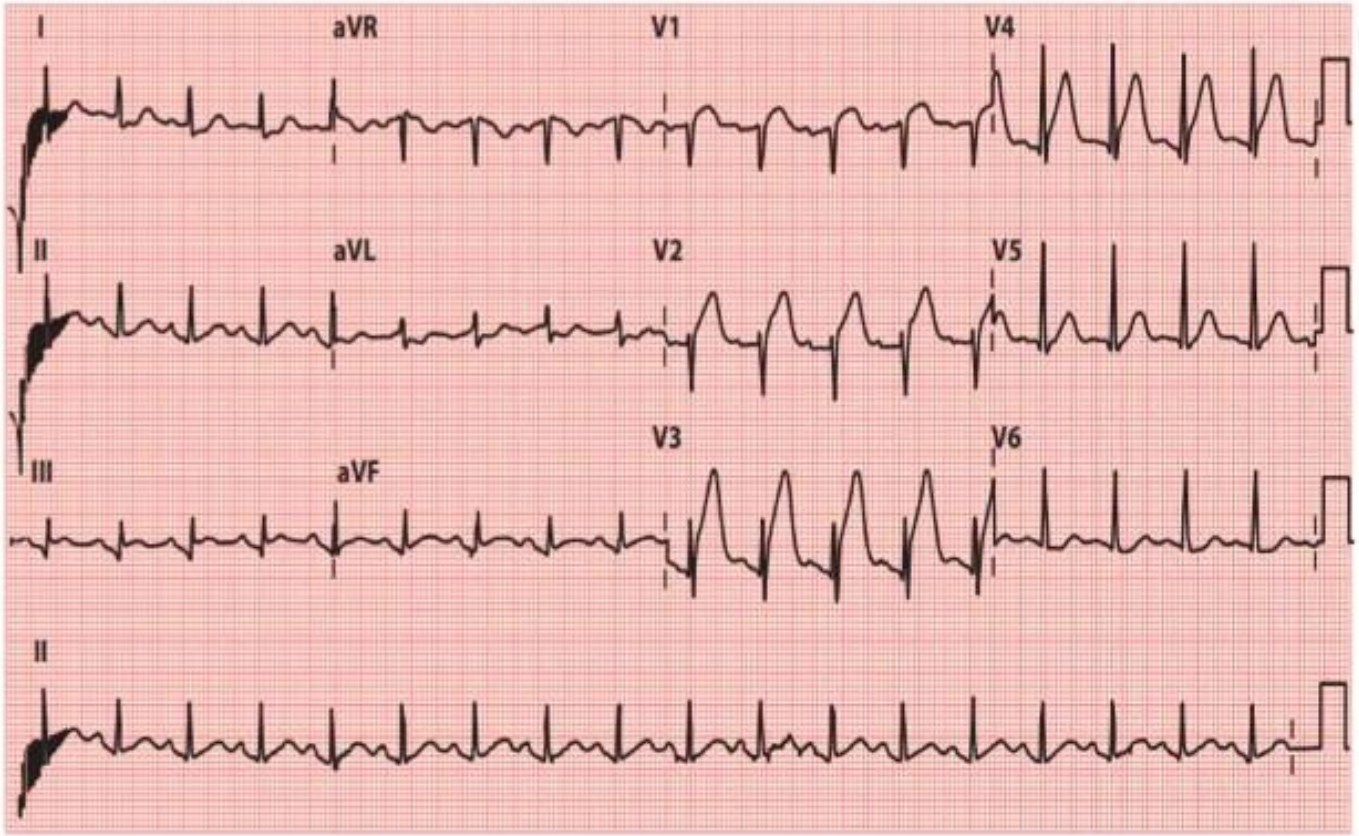

Figure 16.4 Acute anterior myocardial infarction.

Key point: • Tall 'hyperacute' T waves are present in the anteroseptal chest leads.

Inverted T waves

Normal finding in children (V1-V3)
Persistent juvenile T wave pattern (V1-V3, young Afro Carribean women)
Myocardial ischemia and infarction
Bundle branch block
Ventricular hypertrophy (strain pattern)
Pulmonary embolism
Hypertrophic cardiomyopathy
Raised intracranial pressure
Memory T waves



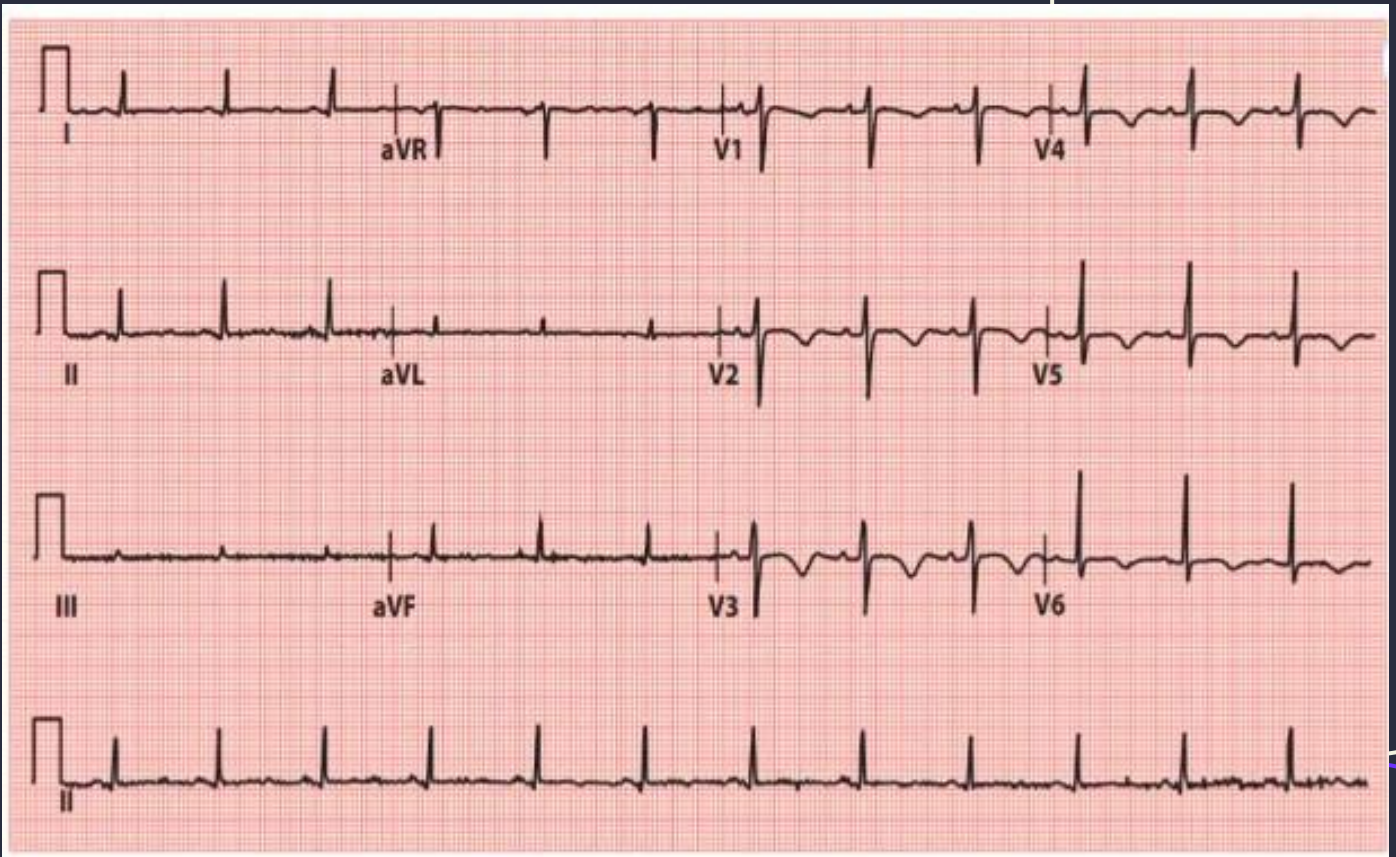

Figure 16.6 Myocardial ischaemia.

Key points:
- Abnormal T wave inversion (leads V_2–V_6) during an episode of myocardial ischaemia.
- There is also, incidentally, prolongation of the QT interval.

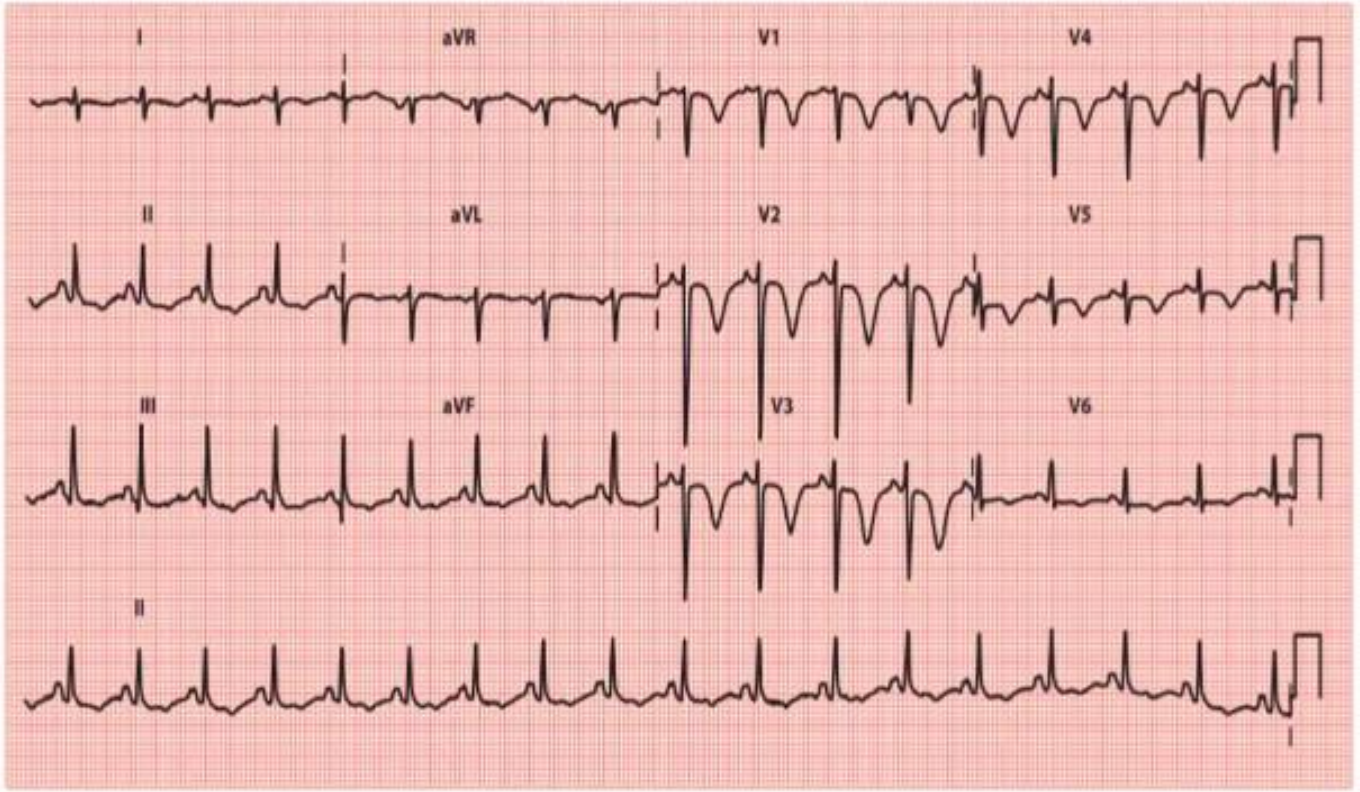

Figure 16.7 Wellens' sign.

Key points:
- Deep T wave inversion in the anterior chest leads in a patient presenting with unstable angina.
- Coronary angiography revealed a critical proximal stenosis in the left anterior descending coronary artery.

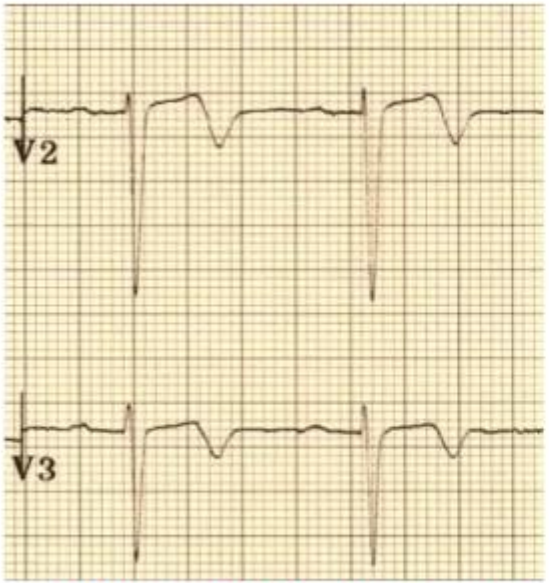

Wellens Pattern A (Type1)

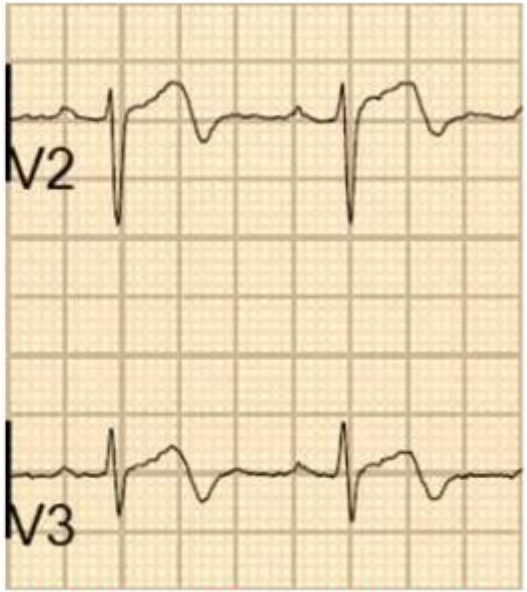

Wellens Pattern A (Type 1)

Wellens Type B TYPE 2

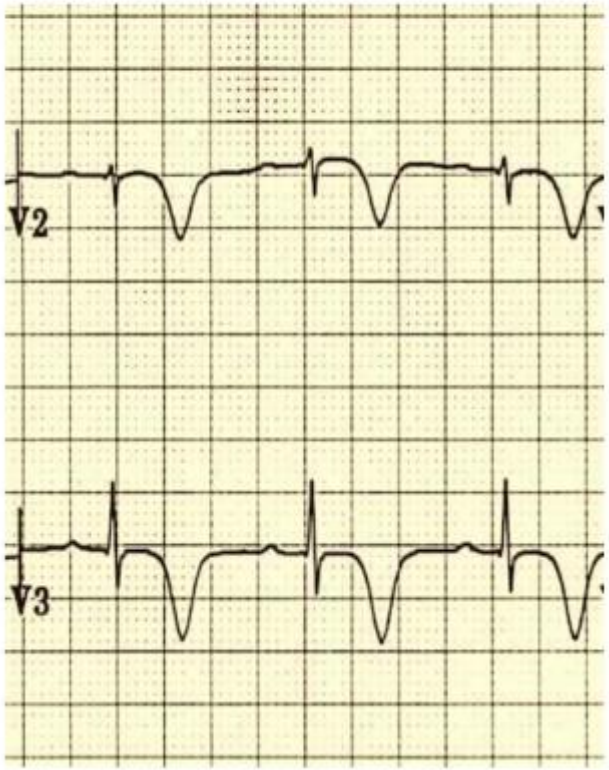



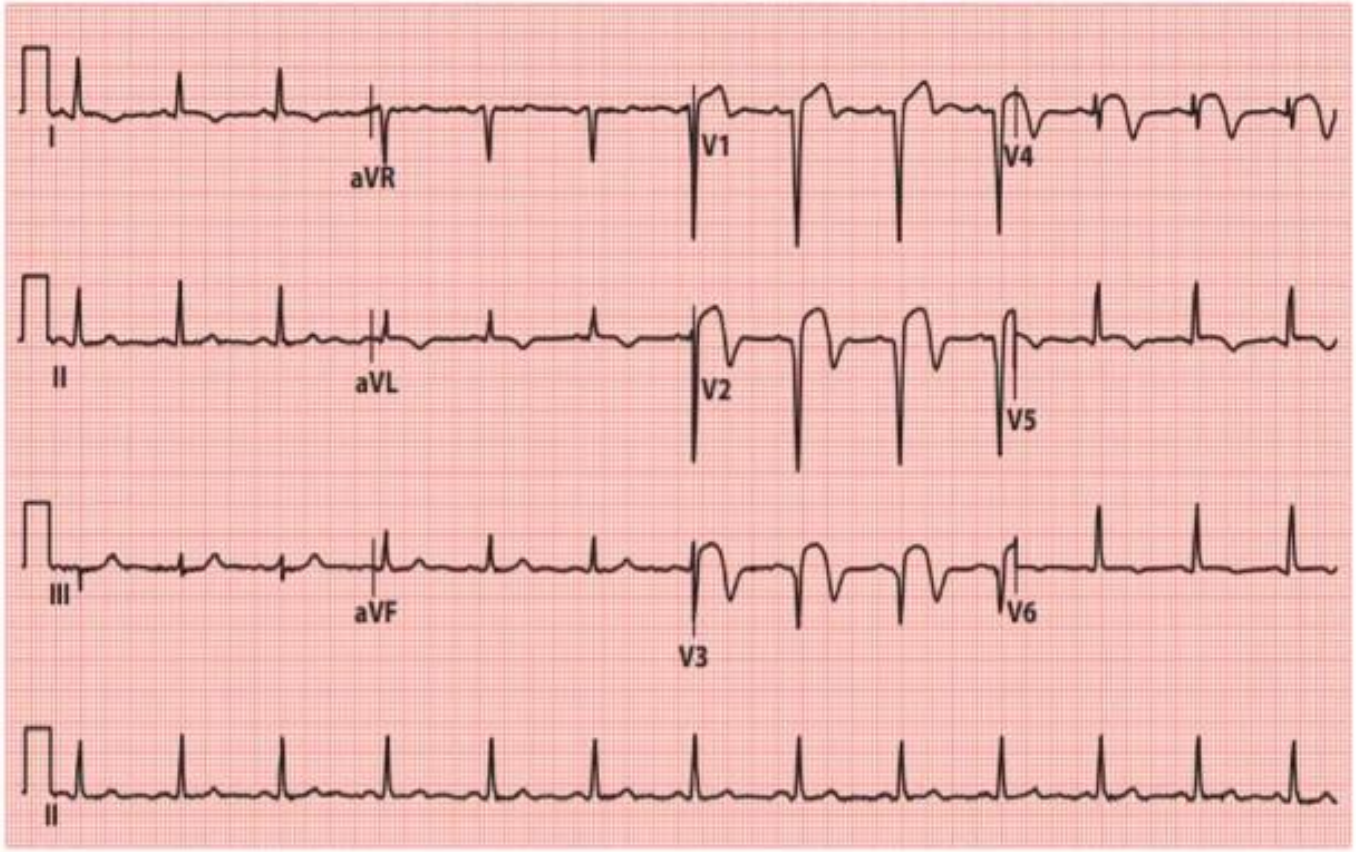

Figure 16.8 Evolving ST segment elevation myocardial infarction.

Key points:
- As the ST segment elevation returns to baseline, T wave inversion develops.
- Note also the development of Q waves in the anterior leads.

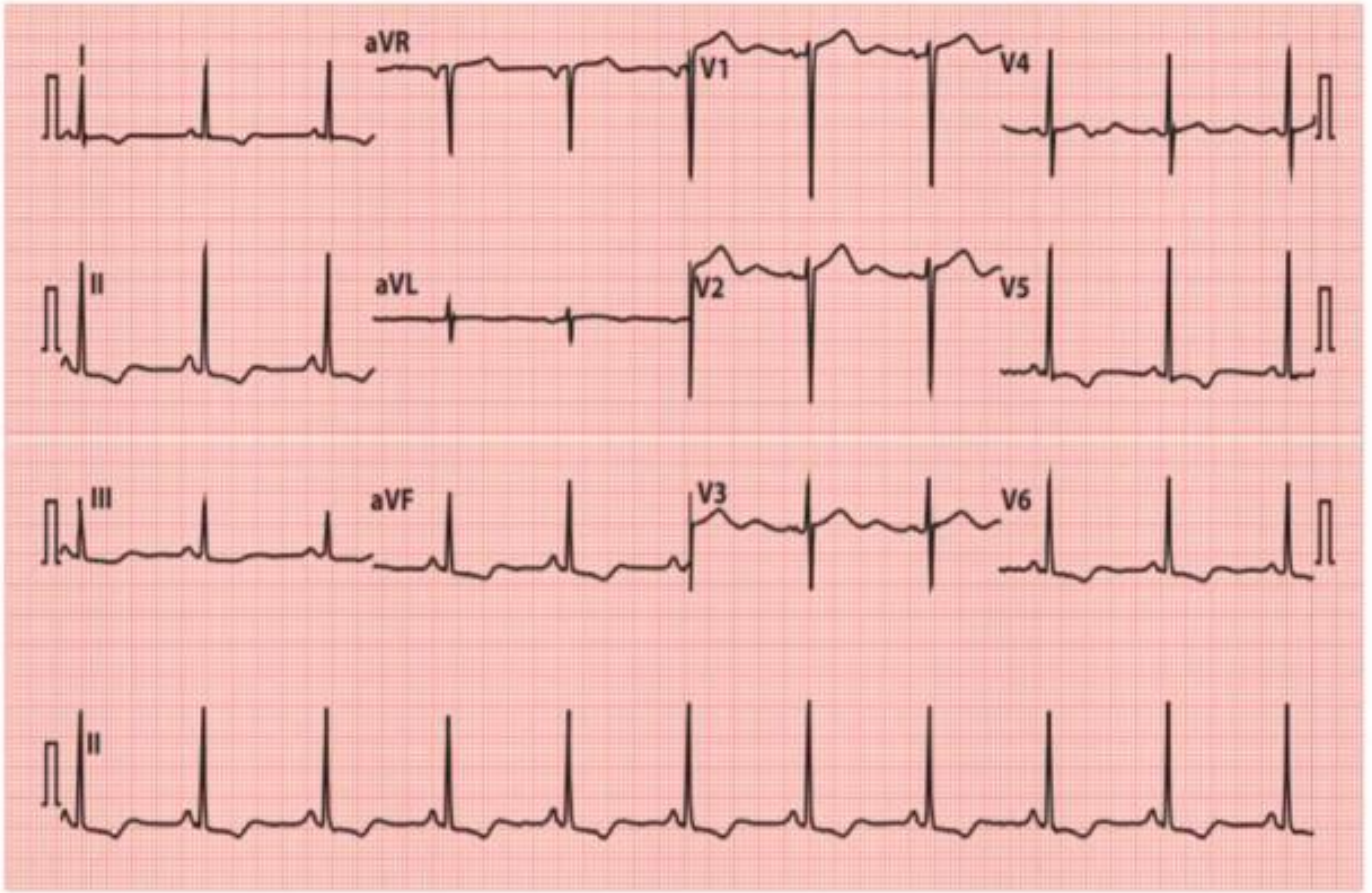

Figure 16.9 Left ventricular hypertrophy with 'strain'.

Key point: • As well as large QRS complexes, T wave inversion is present in the lateral leads.

Right Ventricular Hypertrophy (RVH)

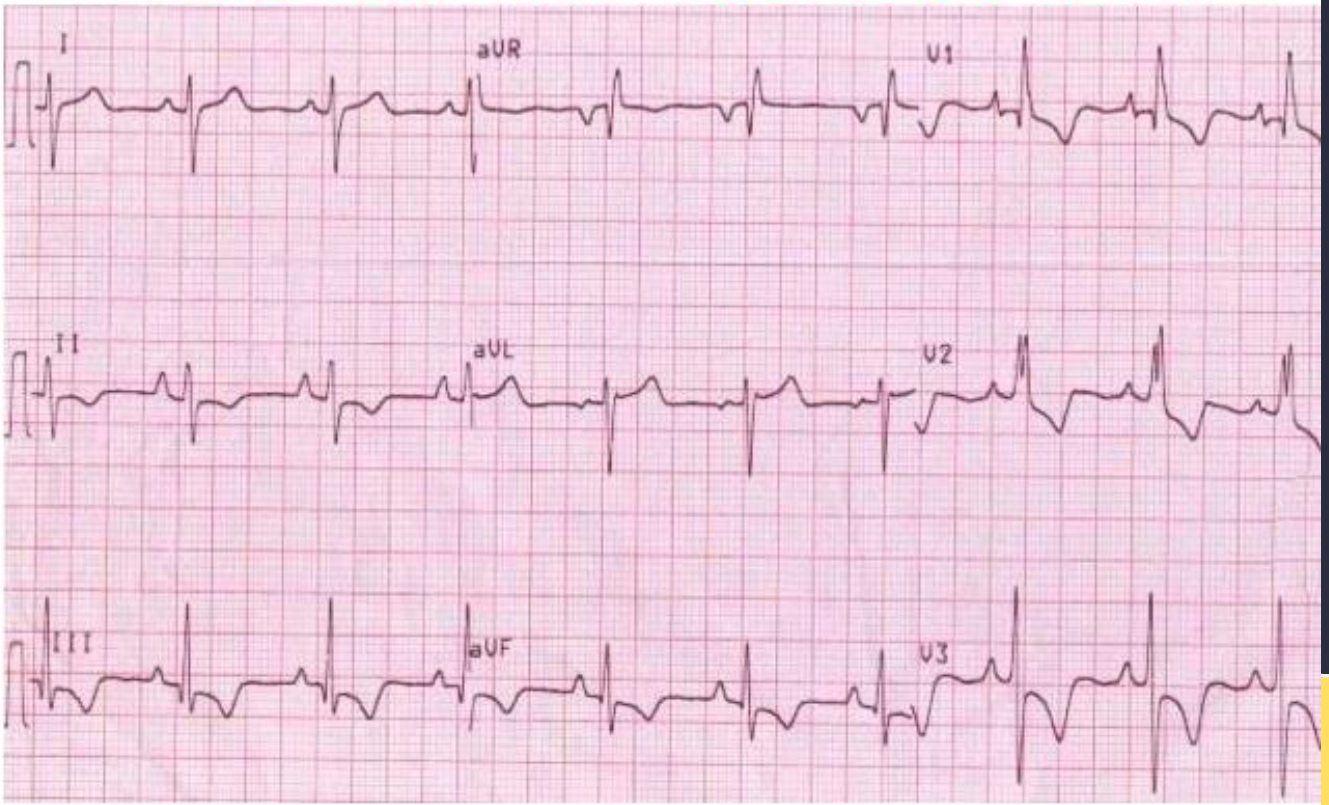

•Right ventricular hypertrophy produces T-wave inversion in the right precordial leads V1-3 (right ventricular 'strain' pattern) and also the inferior leads (II, III, aVF)

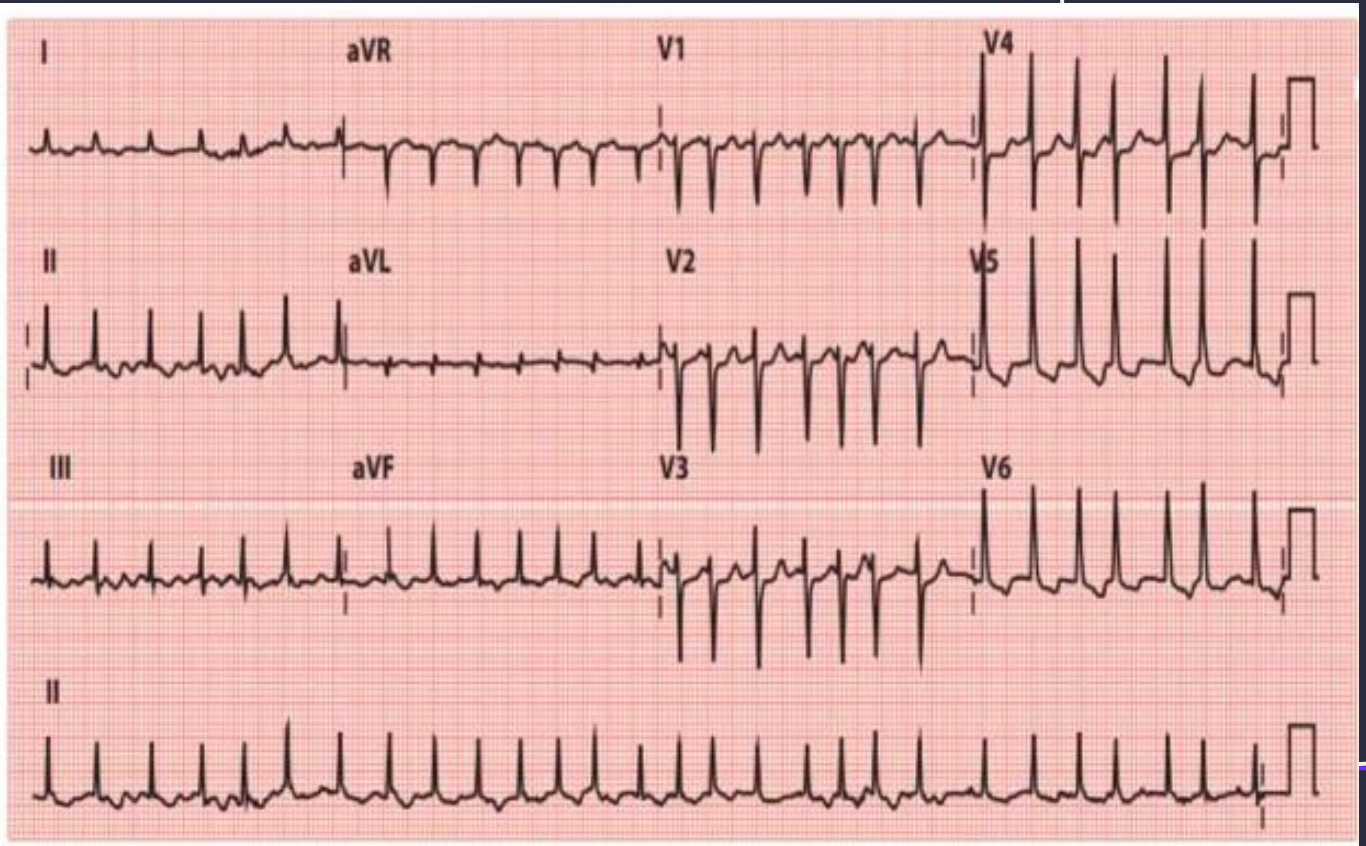

Figure 16.10 Digoxin effect on the ECG.

Key point: • There is reverse tick ST segment depression and T wave inversion in leads V_5–V_6. Patient on digoxin for atrial fibrillation with a very fast ventricular rate (168/min).

T wave inversion in I, aVL, V5-V6

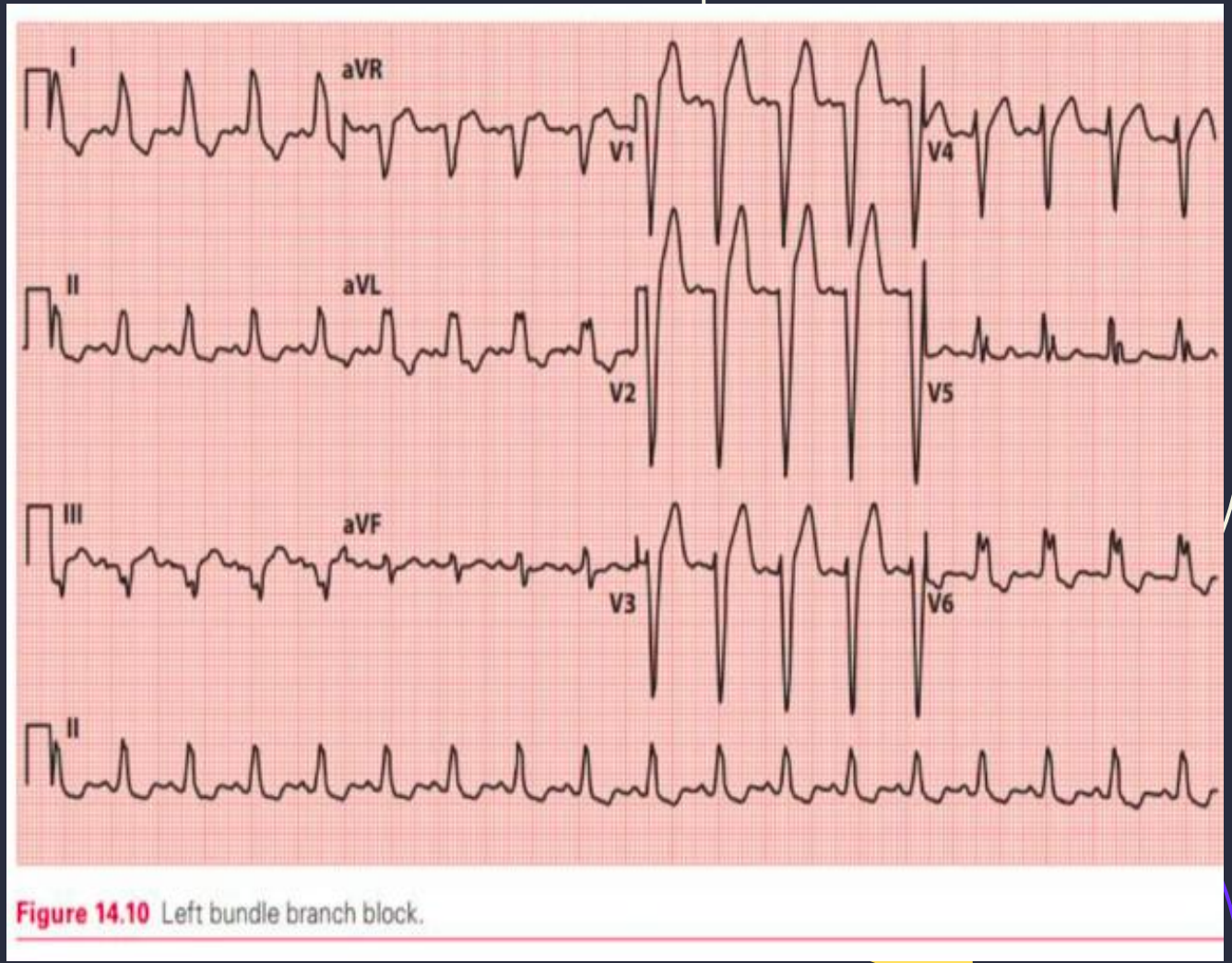

Figure 14.10 Left bundle branch block.

T wave inversion V1-V3

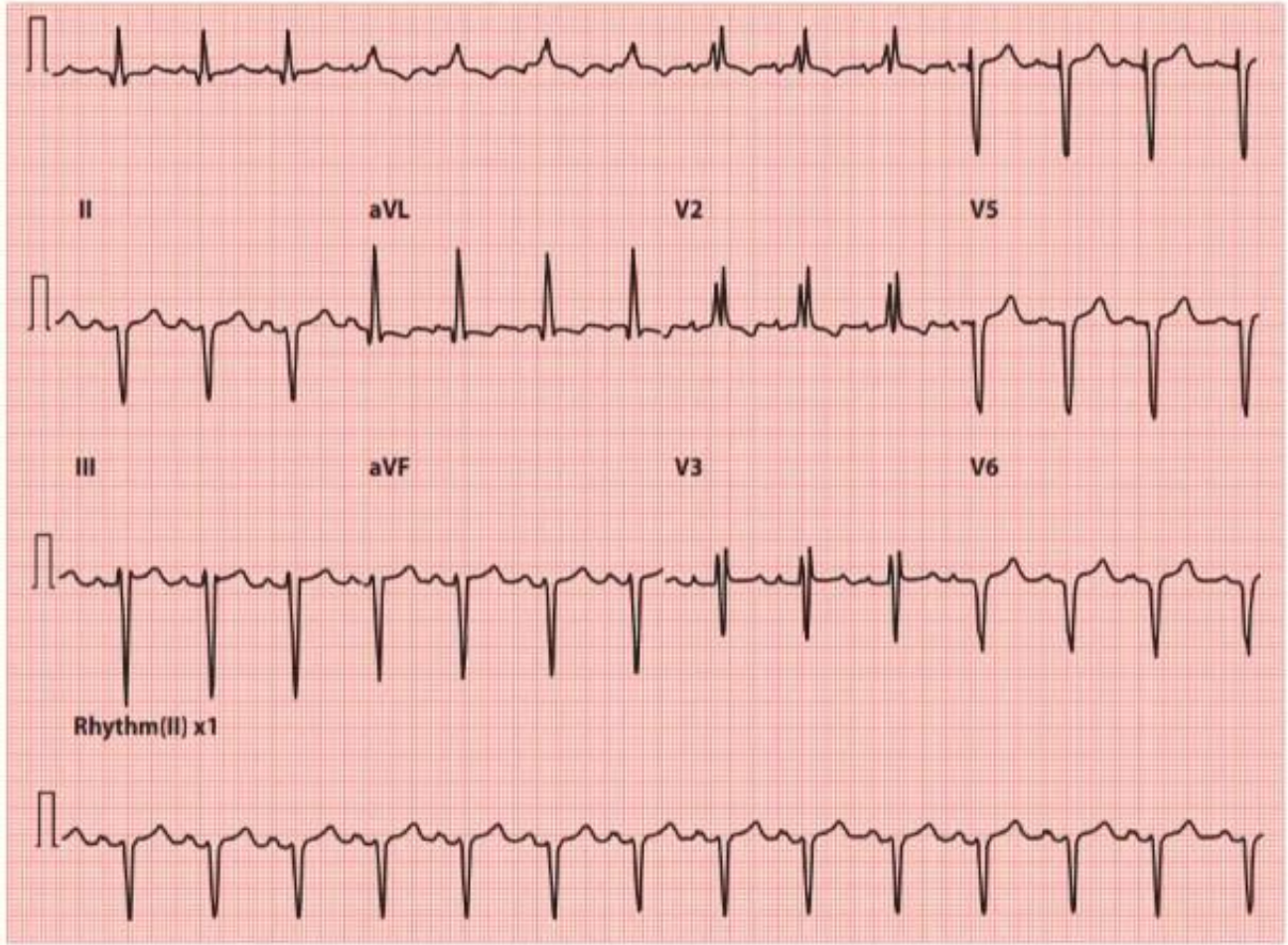

Figure 14.11 Right bundle branch block.

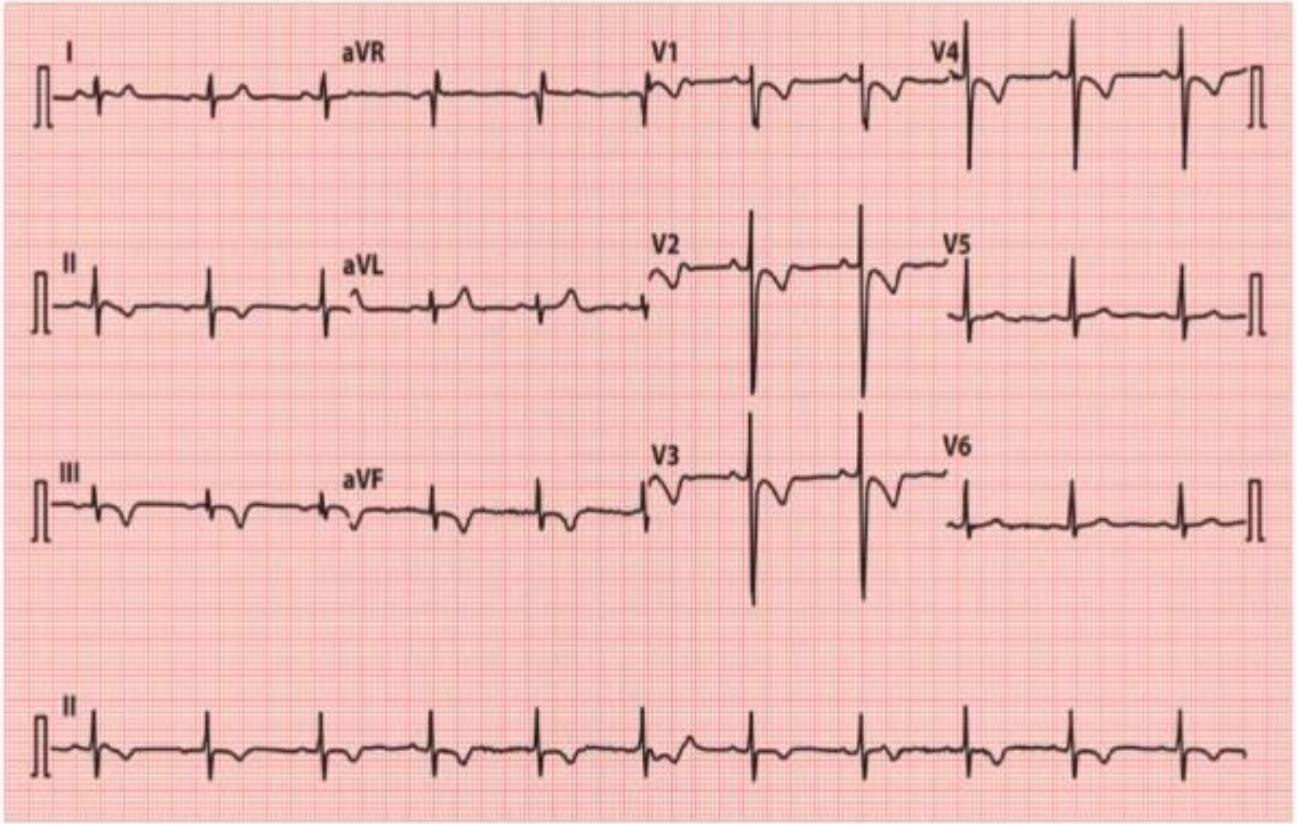

Figure 13.4 Pulmonary embolism.

Key points:
- There is an $S_I Q_{III} T_{III}$ pattern.
- Note also the T wave inversion in leads V_1–V_4.
- The patient was taking beta-blockers, and so the usual sinus tachycardia was absent in this case.

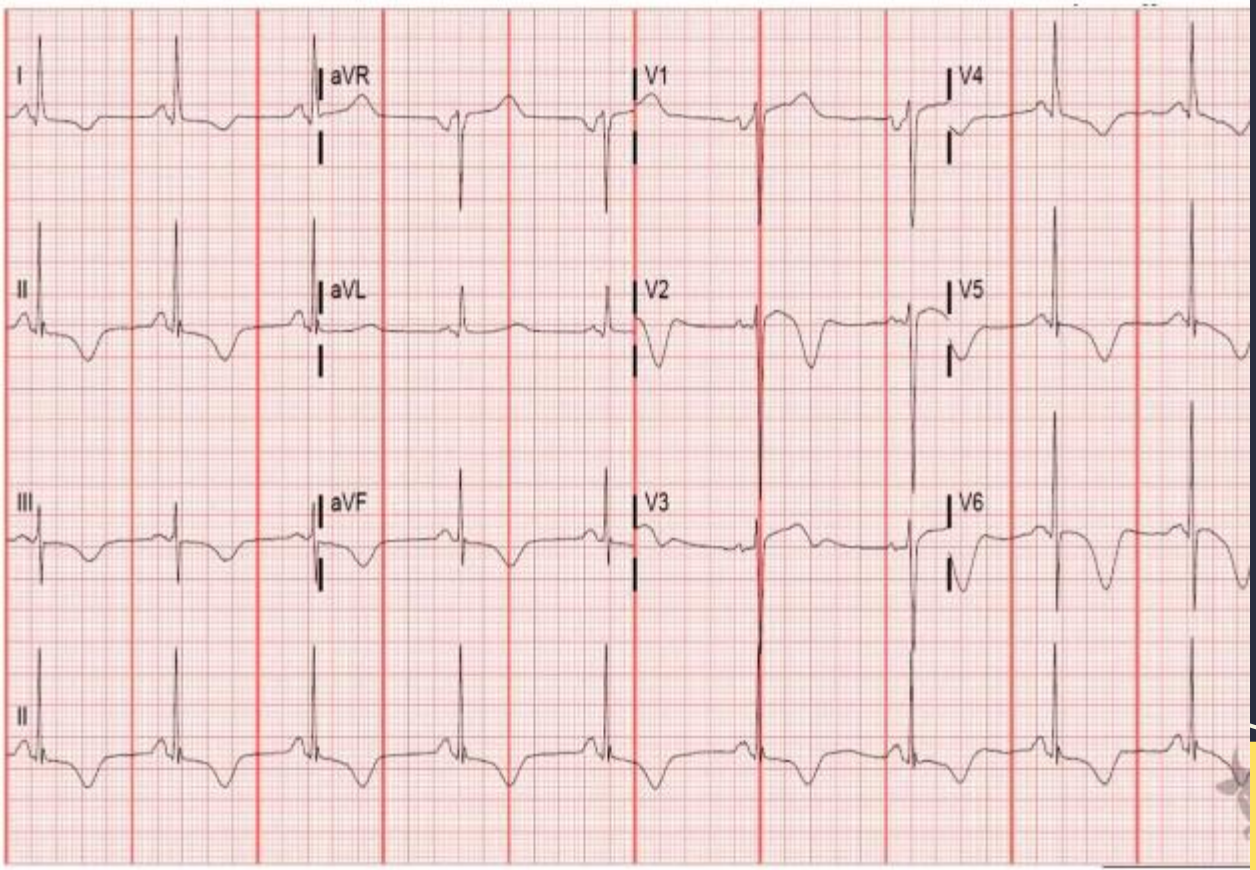

- **Cerebral T waves**
- The diffuse "roller coaster" T wave inversions and prolonged QT inteveral were due to a pontine hemorrhage

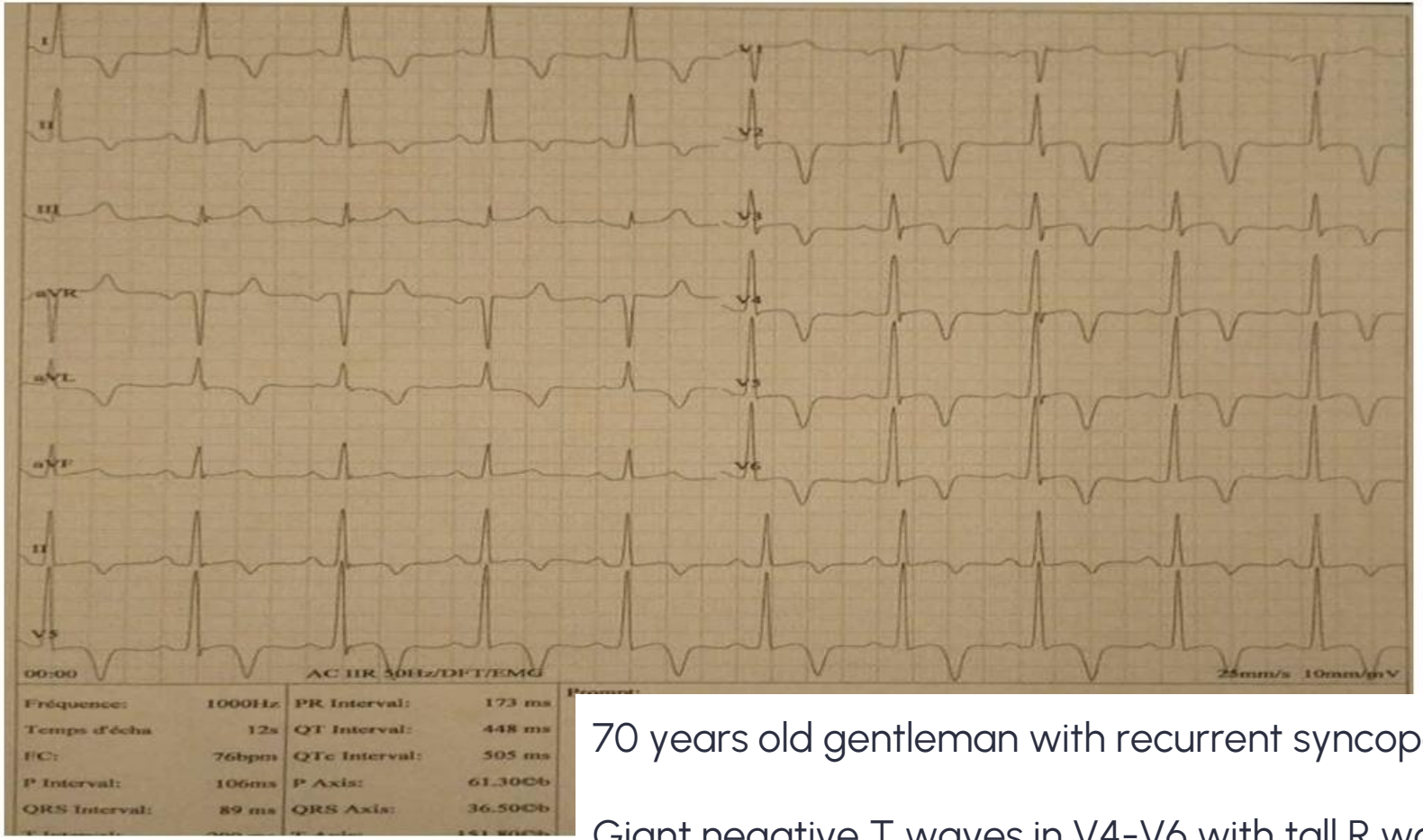

70 years old gentleman with recurrent syncope

Giant negative T waves in V4-V6 with tall R waves are classic for apical hypertrophic cardiomyopathy

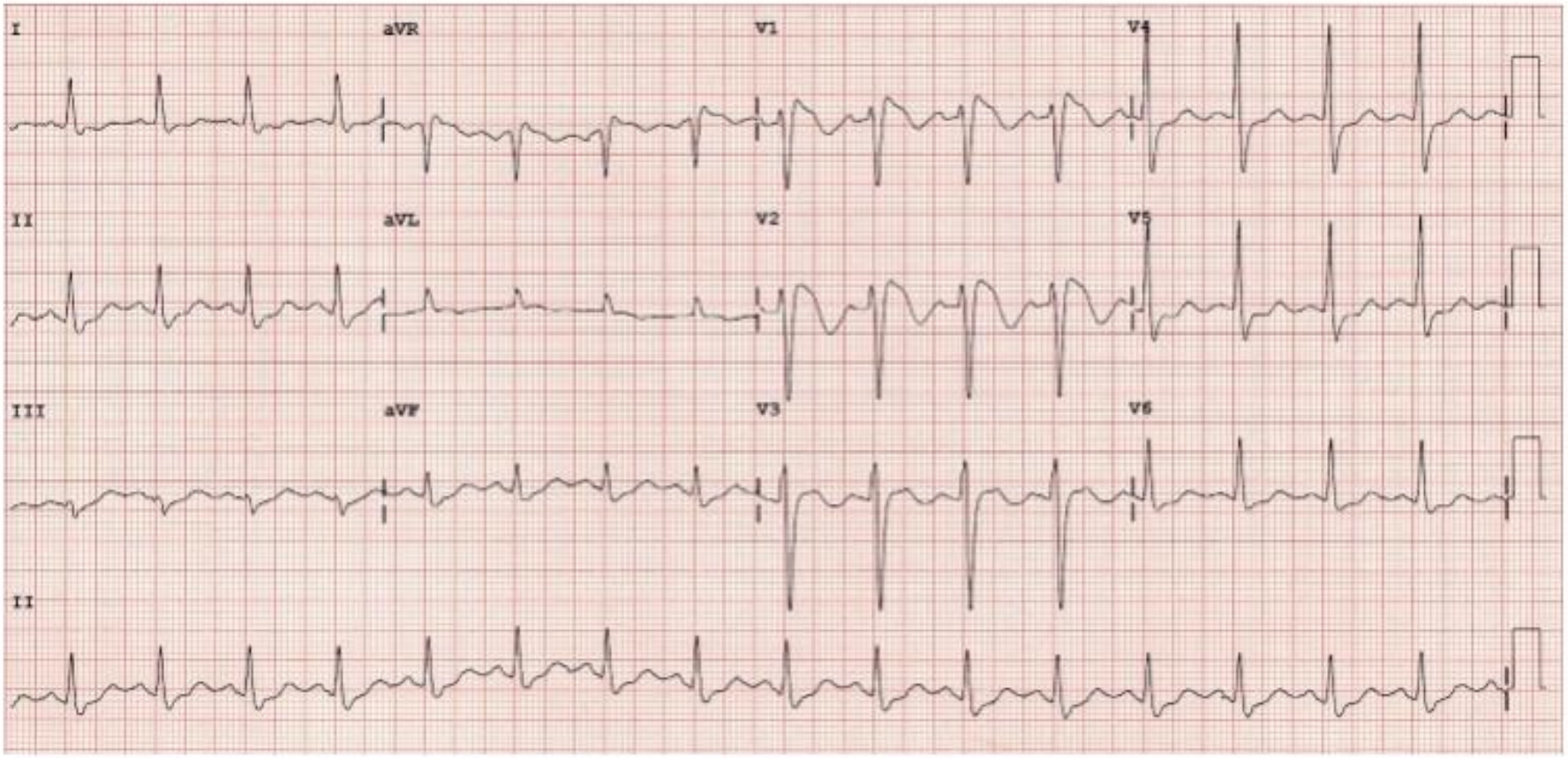
I
aVR
V1
V4
II
aVL
V2
V5
III
aVF
V3
V6
II

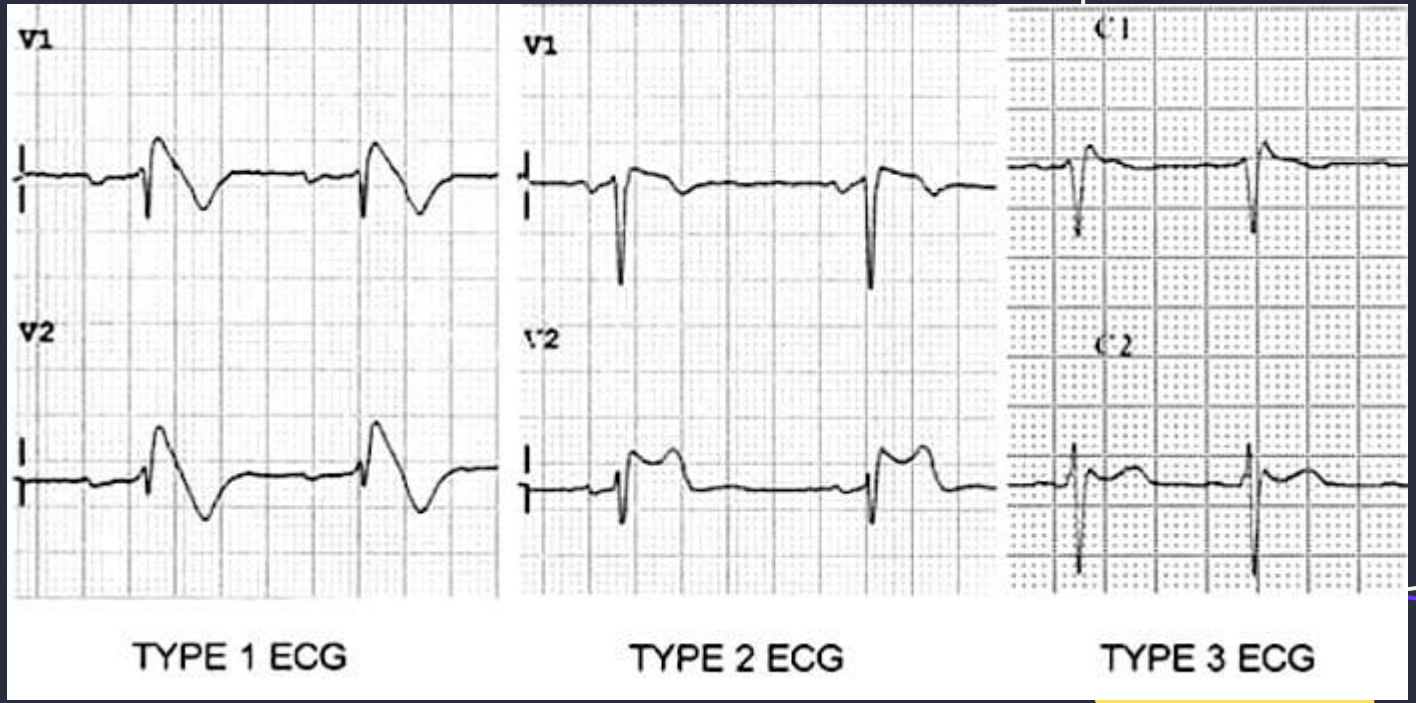
V1
V2
V1
V2
TYPE 1 ECG
TYPE 2 ECG
TYPE 3 ECG

Small T wave

Hypokalemia (1st degree HB; U waves; ST depression)
Pericardial effusion (whole ECG complexes small)
Hypothyroidism (along with sinus bradycardia)

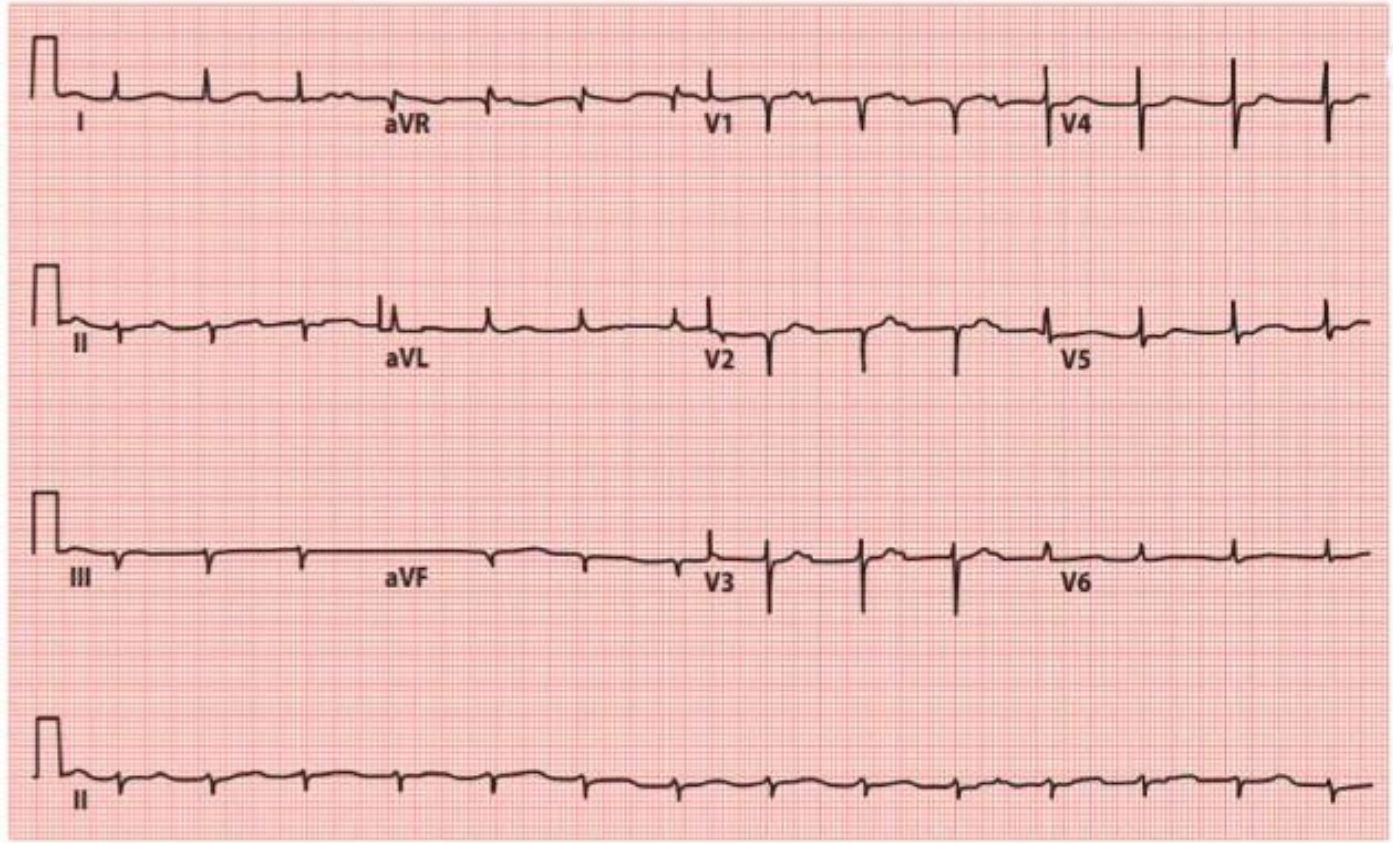

Figure 16.5 Hypokalaemia.

Key point:

- There are small T waves and prominent U waves, plus first degree atrioventricular block and left axis deviation.

Biphasic T wave

Myocardial ischemia
Hypokalemia

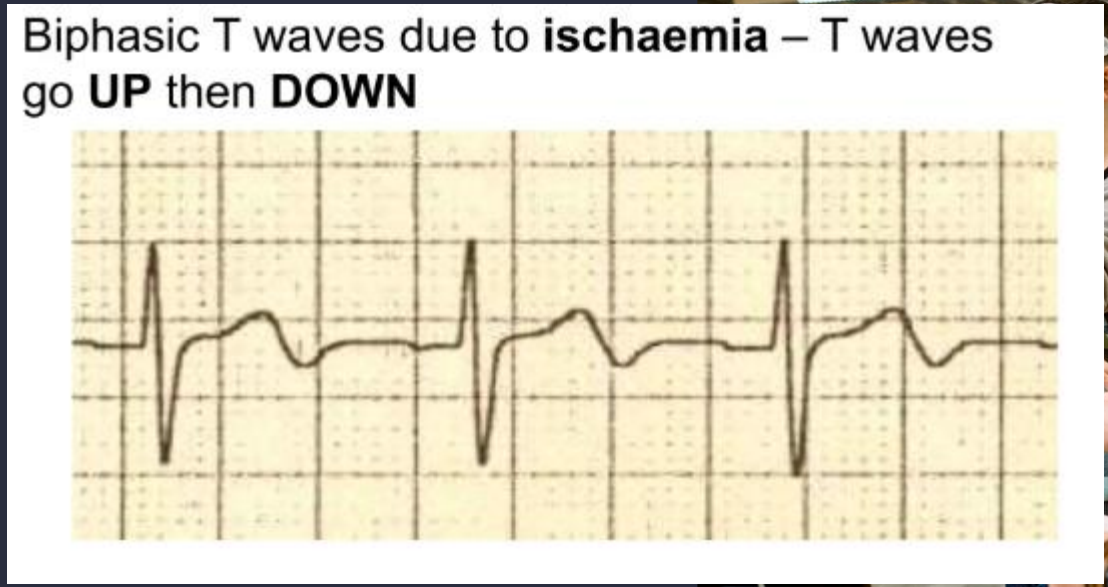

Biphasic T waves due to Hypokalaemia –

T waves go **DOWN** then **UP**



Camel hump T wave

Double peak T wave
Prominent U wave in severe hypokalemia
Hidden P wave as in sinus tachycardia & various types of heart block

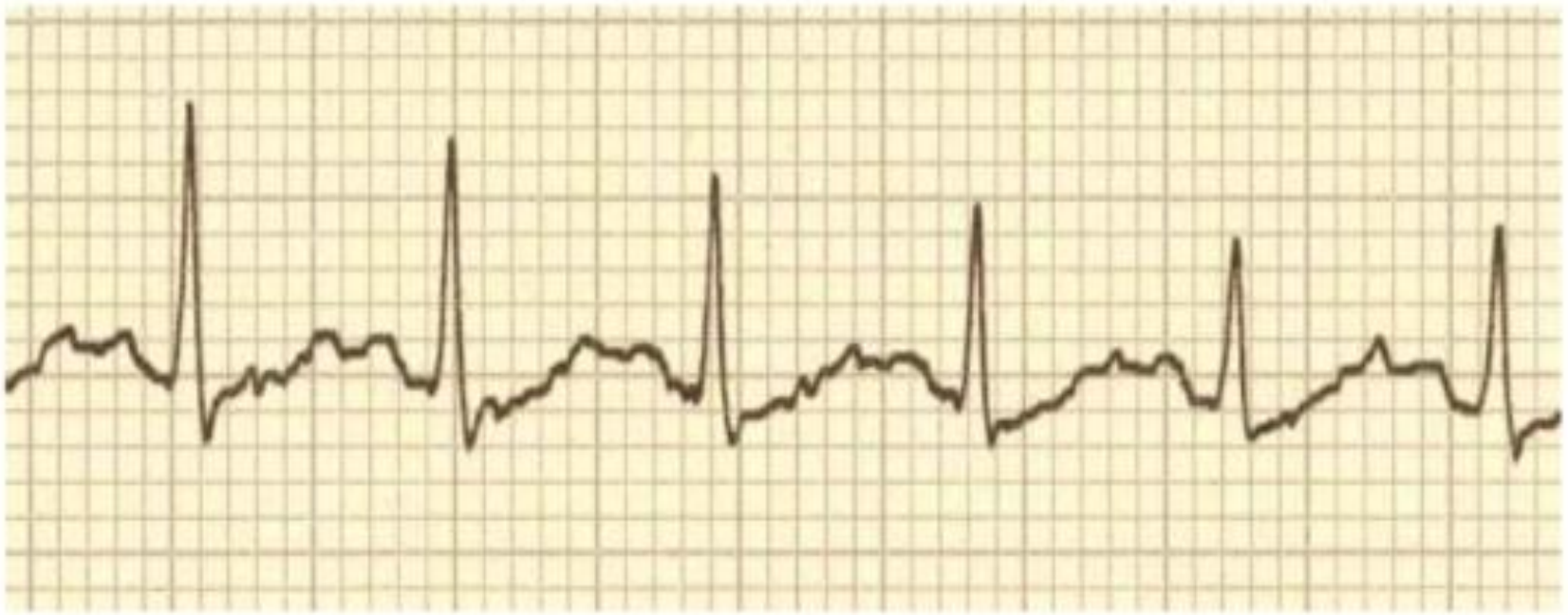

Hidden P waves in sinus tachycardia

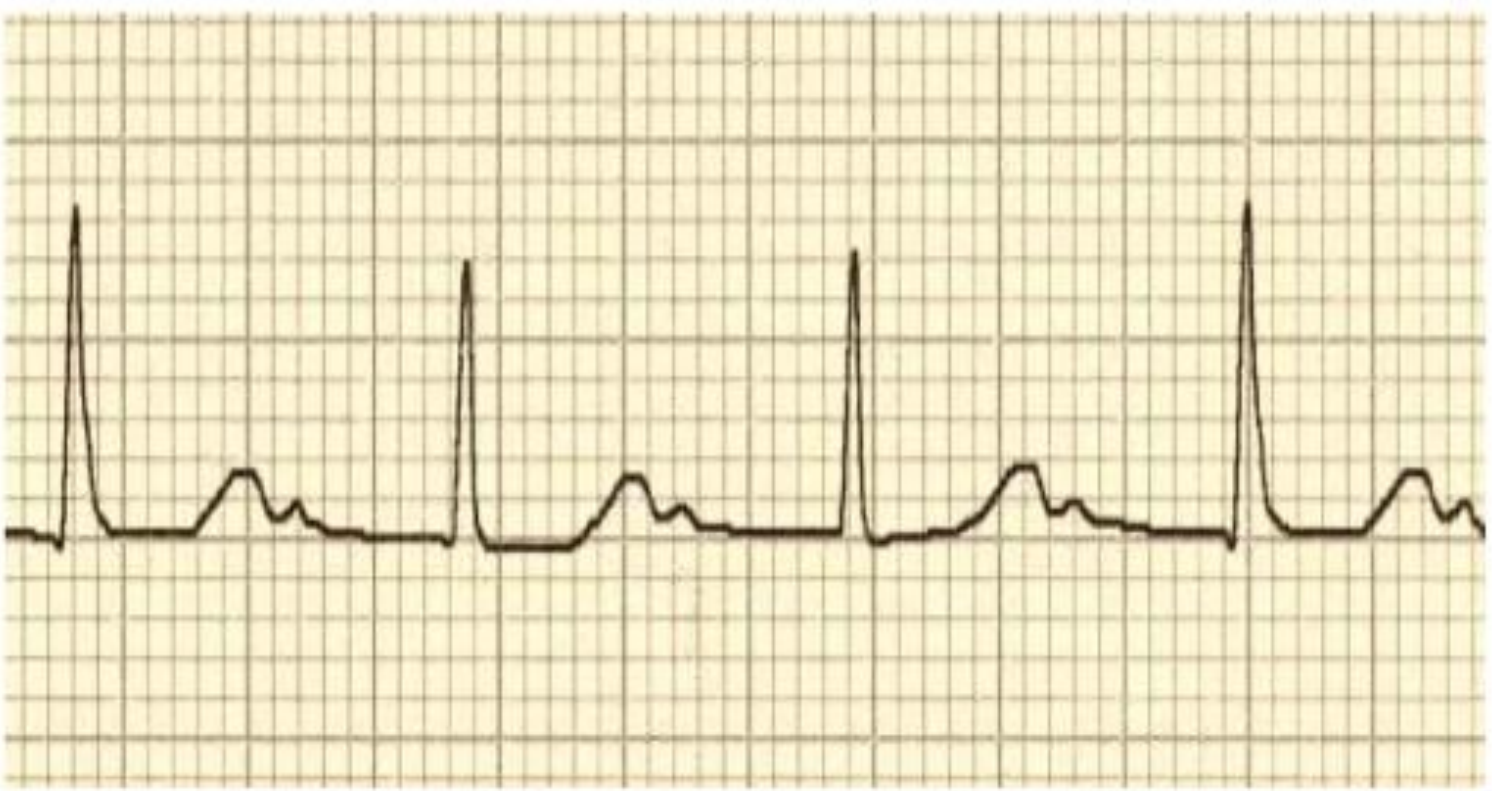

Hidden P waves in marked 1st degree heart block

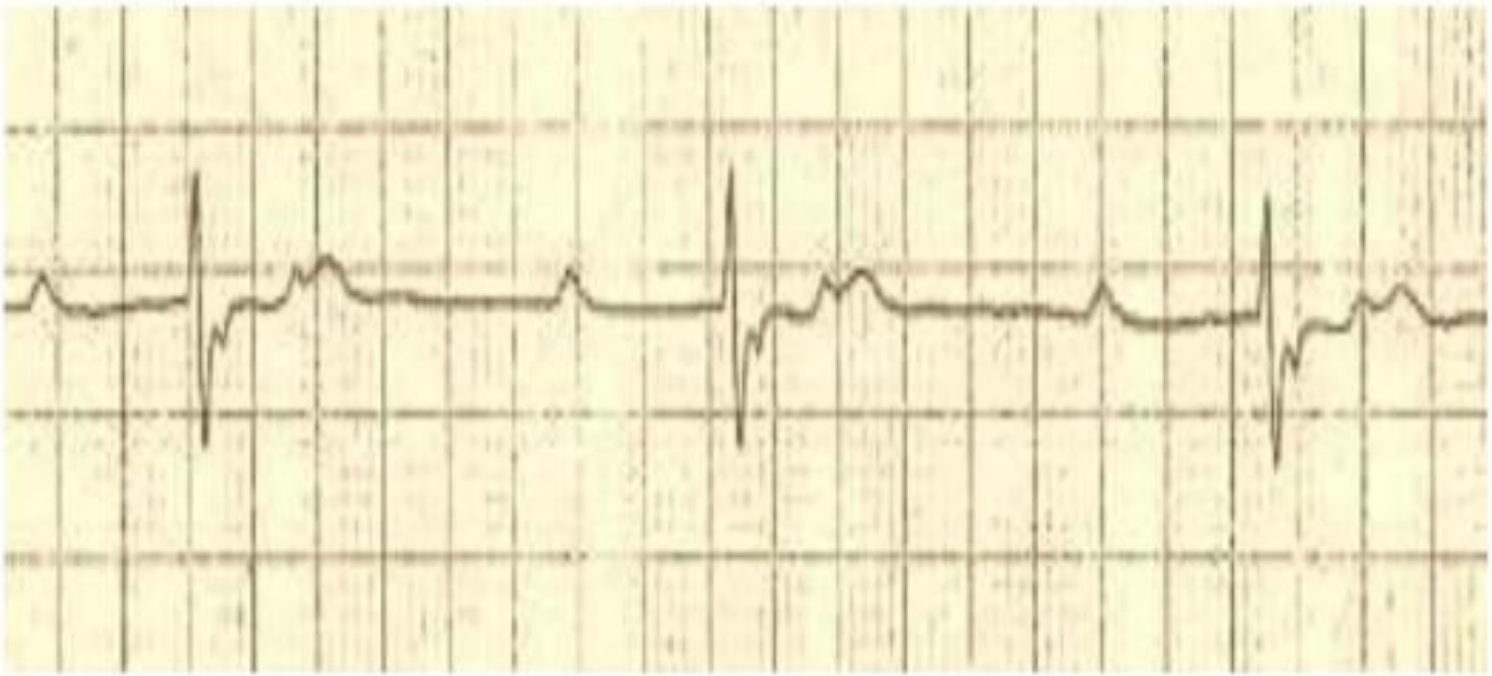

Hidden P waves in 2nd degree heart block with 2:1 conduction

Prolonged QT interval

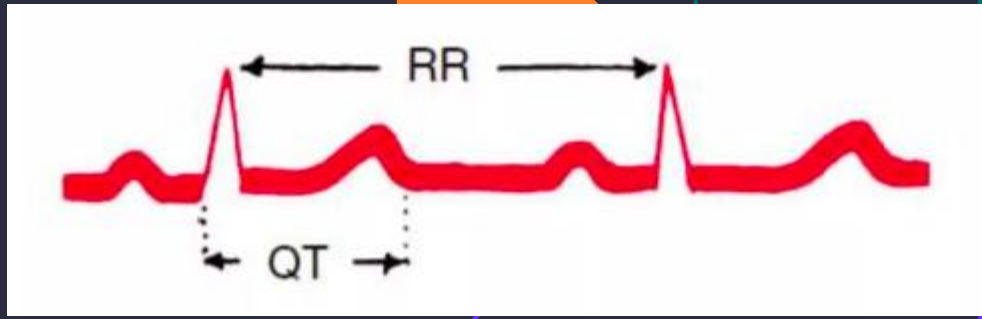

Beginning of QRS to end of T
Represents ventricular repolarization
Normal values of QT depends on heart rate
As the heart rate increases (RR interval shortens), the QT interval shortens
As the heart rate decreases (RR interval lengthens), the QT interval lengthens

Corrected QT

Bazett formula
QTc = QT/ √RR

QTc > 440 ms in males - abnormal
QTc >460 ms in females - abnormal
QTc >500 ms 5X increased risk of events







	LQT1	LQT2	LQT3
ECG Morphology	Broad T waves	Bifid T waves	Late T waves
Trigger	Exertion, fright, swimming	Auditory	Sleep / rest

Any questions? Ask away!



Thank you